

Supplement to

RETINA TODAY

November/December 2010

Jointly sponsored by the Dulaney Foundation and Retina Today.

CME ACTIVITY



Topical Steroids

for Therapeutic Use in
the Posterior Segment

TARGET AUDIENCE

This activity is designed for retina specialists and other ophthalmologists.

LEARNING OBJECTIVES

Upon completion of this activity, you will be able to:

1. Discuss recent data on key posterior segment conditions comparing difluprednate vs other treatment options in terms of dosing and visual and functional outcomes
2. Cite findings from a refractory macular edema study comparing difluprednate vs sub-Tenon triamcinolone
3. Evaluate research describing the dose uniformity among various preparations of steroids
4. Clarify the role of difluprednate for the treatment of uveitis and understand its dosing schedule compared with other treatment options
5. Develop clinical strategies that account for different dosing patterns and delivery methods among the preparations (ie, topicals or injections)

METHOD OF INSTRUCTION

Participants should read the continuing medical education (CME) activity in its entirety. After reviewing the material, please complete the self-assessment test, which consists of a series of multiple-choice questions, and the course evaluation. To answer these questions online and receive real-time results, please visit <http://www.dulaneyfoundation.org> and click "Online Courses." Upon completing the activity and achieving a passing score of over 70% on the self-assessment test, you may print out a CME credit letter awarding 1.0 AMA PRA Category 1 Credits.[™] The estimated time to complete this activity is 1.0 hour.

ACCREDITATION AND DESIGNATION

This activity has been planned and implemented in accordance with the Essential Areas and policies of the Accreditation Council for Continuing Medical Education (ACCME) through the joint sponsorship of the Dulaney Foundation and *Retina Today*. The Dulaney Foundation is accredited by the ACCME to provide continuing education for physicians. The Dulaney Foundation designates this educational activity for a maximum of 1.0 AMA PRA Category 1 Credits.[™] Physicians should only claim credit commensurate with the extent of their participation in the activity.

CONTENT VALIDATION

In compliance with ACCME standards for commercial support and the Dulaney Foundation's policy and procedure for resolving conflicts of interest, this CME activity was peer reviewed for clinical content validity to ensure the activity's materials are fair, balanced, and free of bias; the activity materials represent a standard of practice within the medical profession; and any studies cited in the materials upon which recommendations are based are scientifically objective and conform to research principles generally accepted by the scientific community.

FACULTY CREDENTIALS

Alexander Eaton, MD, is in private practice in Fort Myers, FL, and is a member of the Clinical Faculty at Duke University Medical Center in Durham, NC.

Ron P. Gallemore, MD, PhD, is director of the Retina Macula Institute and Research Center in Los Angeles and Assistant Clinical Professor at the Jules Stein Eye Institute, University of California, Los Angeles.

Seenu M. Hariprasad, MD, is an Associate Professor and the Director of Clinical Research at the University of Chicago Department of Surgery, Section of Ophthalmology and Visual Science. He serves as Chief of the Vitreoretinal Service and is Director of the Surgical Retina Fellowship Program.

Daniel M. Miller, MD, PhD, is with the Cincinnati Eye Institute in Ohio and is a voluntary Assistant Professor in the Department of Ophthalmology at the University of Cincinnati.

Keith A. Warren, MD, is a Professor of Ophthalmology at the University of Kansas and founder of Warren Retina Associates, PA, in Overland Park, KS.

DISCLOSURE

In accordance with the disclosure policies of the Dulaney Foundation and to conform with ACCME and US Food and Drug Administration (FDA) guidelines, anyone in a position to affect the content of a CME activity is required to disclose to the activity participants: (1) the existence of any financial interest or other relationships with the manufacturers of any commercial products/devices, or providers of commercial services; and (2) identification of a commercial product/device that is unlabeled for use or an investigational use of a product/device not yet approved.

Dr. Eaton-Grant/Research Support: Alcon Laboratories, Inc., Regeneron. Consultant: Allergan, Inc.

Dr. Gallemore-Grant/Research Support: Genentech. Consultant: Ista Pharmaceuticals. Speakers List: Alcon Laboratories, Inc., Allergan, Inc., Ista Pharmaceuticals, Inspire, Bausch + Lomb.

Dr. Hariprasad-Consultant: Alcon Laboratories, Inc., ODOS, Genentech, Pfizer, Ocular Therapeutix. Speakers List: Alcon Laboratories, Inc., Allergan, Inc., Genentech.

Dr. Miller-Grant/Research Support: Alcon Laboratories, Inc, Genentech, Regeneron. Consultant: Alcon Laboratories Inc., Revision. Speakers List: Allergan, Inc.

Dr. Warren-Consultant and Speakers List: Alcon Laboratories, Inc., DORC.

All of those involved in the planning, editing, and peer review of this educational activity report no financial relationships.

STATEMENT OF NEED

The challenges faced by vitreoretinal specialists and ophthalmologists managing retinal conditions are increasing due to the impact of the aging population, the epidemic of diabetes, and diabetic retinal disease.¹ As advances in vitreoretinal treatment options and technology have increased the opportunity

for improved patient outcomes, evidence suggests that, like other clinicians, ophthalmologists do not fully use these advances for the benefit of their patients.² The knowledge base with regard to a commonly used class of drugs for the treatment of retinal disease—steroids—is quickly evolving. As the understanding of the pharmacology and pharmacokinetics of these agents becomes further elucidated, surgeons must be made aware of emerging concepts.

Most retina specialists were educated at a time when much less was understood regarding steroids and steroid receptors. The available information of the past was mostly limited to the basic differences in steroid structure and potency. In fact, the original experiments indicating potency measures were performed more than 40 years ago, and steroid receptor morphology and its subsequent influence on steroid activity was largely unknown. Furthermore, the bulk of information about steroids was derived from other specialties, such as asthma and allergy, where steroids were routinely used. Therefore, little comparative data with regard to ocular use was available. Additionally, most of the use of steroids in retinal disease has been driven by “off-the-shelf” use of triamcinolone acetonide at the time of the most earliest experiments.³⁻⁶ Today, the understanding of the role of inflammation in the underlying pathology of retinal disease is being expanded exponentially, thanks largely to the availability of new technologies, as well as applied learning from the fields of oncology and immunology.^{7,8}

Now, new steroids and steroid formulations and delivery systems are being investigated as well as being approved for use in a variety of retinal diseases, yet much of the science behind steroid differentiation has not been adequately discussed or disseminated among retina specialists.⁹⁻¹⁴ Given these circumstances, there is a growing need to expose retina specialists to current and emerging thinking regarding the area of steroids and how they can be differentially used to achieve optimal patient outcomes in retinal diseases.

This is further illustrated by a recent online commentary by Judy E. Kim, MD, retina specialist and Professor at the Medical College of Wisconsin.

“Compared with other routes of delivery, steroid delivered topically for treatment of ocular inflammation has the benefit of having lower or nonexistent risk of endophthalmitis, retinal tears or detachment, subconjunctival hemorrhage, pain, cataract, and ptosis. In addition, it is less likely than intravitreal steroid to cause very high intraocular pressure (IOP). Topical steroids can be used as a method of challenge to see if sub-Tenon or intravitreal steroid injection is likely to cause IOP elevation.

Furthermore, steroid dosing and duration of treatment can be tailored to the severity of inflammation and can be tapered or discontinued as needed. In cases of mild but recurrent inflammation, low-dose or even once a day or less

dosing may be effective in keeping the inflammation from recurring. Finally, studies have shown that topical steroid can be combined with topical nonsteroidal medications to give synergistic effect in treatment of pseudophakic cystoid macular edema.

However, topical steroid may not be as potent as sub-Tenon or intravitreal route of steroid delivery. Therefore, for more severe, chronic or vision-threatening inflammation, I often proceed directly to sub-Tenon or intravitreal steroid injection. Because my patients are often referred to me after failure of trial of topical steroid, I tend to proceed to other routes of steroid delivery sooner. Furthermore, patient compliance with topical steroid cannot be controlled, and poor compliance may reduce the efficacy of the drug.”¹⁵

It is clear that expert opinion and dissemination of knowledge among colleagues can improve this learning gap so that more patients may benefit from treatment advances that have the potential to greatly improve outcomes and therefore quality of life for patients. Heightened expectations from Internet-savvy patients and increasing demand for vitreoretinal care due to population and demographic changes over the coming years adds to the pressure on surgeons to deliver superior clinical outcomes to more patients.^{16,17}

1. Ryskulova A, Turczyn K, Makuc DM, Cotch MF, Klein RJ, Janiszewski R. Self-reported age-related eye diseases and visual impairment in the United States: results of the 2002 national health interview survey. *Am J Public Health*. 2008;98(3):454-461.
2. Drapkin J, Howell S. *Demonstrating and Capturing the Value of Medical Technologies. Value-based Payment for Medical Technologies*. Conference Report. The Health Industry Reform, October 2, 2007, Washington, DC.
3. Lewis-Tuffin LJ, Jewell CM, Bienstock RJ, et al. Human glucocorticoid receptor b binds RU_486 and is transcriptionally active. *Mol Cell Biol*. 2007;27:2266-2282.
4. Smoak K, Cidlowski JA. Glucocorticoids regulate tristetrapolin synthesis and posttranscriptionally regular tumor necrosis factor alpha inflammatory signaling. *Mol Cell Biol*. 2006;26:9126-9135.
5. Ciulla RP, Pratt TA, Anliker PT, et al. Intravitreal triamcinolone acetonide in exudative age-related macular degeneration. *Retina*. 2000;20:244.
6. Karacorlu M, Ozdemir H, Karacorlu S. Intravitreal triamcinolone acetonide for the treatment of central retinal vein occlusion in young patients. *Retina*. 2004;24(2):324-327.
7. Klein BEK, Cushman M, Wong TY. Traditional and novel cardiovascular risk factors for retinal vein occlusion: the multiethnic study of atherosclerosis. *Invest Ophthalmol Vis Sci*. 2008;49(10):4297-4302.
8. Lee HB, Pulido JS, McCannel CA, et al. Role of inflammation in retinal vein occlusion. *H Can J Ophthalmol*. 2007;42(1):131-133.
9. Oakley RH, Sar M, Cidlowski JA. The human glucocorticoid receptor b isoform. *J Biol Chem*. 1996;271:9550-9559.
10. Scoltock AB, Heimlich G, Cidlowski JA. Glucocorticoids inhibit the apoptotic actions of UV-C but not Fas ligand in hepatoma cells: direct evidence for a critical role of Bcl-xl. *Cell Death Diff*. 2007;14:840-850.
11. Lewis-Tuffin LJ, Cidlowski JA. The physiology of human glucocorticoid receptor b (hGRb) and glucocorticoid resistance. *Ann NY Acad Sci*. 2006;1069:1-9.
12. Necela BM, Cidlowski JA. A single amino acid change in the first zinc finger of the DNA binding domain of the glucocorticoid receptor regulates differential promoter selectivity. *J Biol Chem*. 2004;279:39279-39288.
13. Hermoso MA, Cidlowski JA. Putting the breaks on inflammatory responses: the role of glucocorticoids. *Life*. 2003;55:497-504.
14. Necela BM, Cidlowski JA. Development of a flow cytometric assay to study glucocorticoid receptor-mediated gene activation in living cells. *Steroids*. 2003;68:341-350.
15. What are the benefits and liabilities of using topical vs. intravitreal steroids in treating inflammation associated with eye disease? OSN SuperSite. May 10, 2010. Available at: <http://www.osnsupersite.com/view.aspx?rid=63665>. Accessed November 15, 2010.
16. Baby boomers will increase demand for eye care. OSN SuperSite. November 11, 2008. Available at: <http://www.osnsupersite.com/view.aspx?rid=32642>. Accessed January 14, 2009.
17. Institute of Medicine. *Knowing What Works in Health Care: A Roadmap for the Nation*. Washington, DC: The National Academies Press; 2008. Available at: <http://www.iom.edu/Object.File/Master/50/721/Knowing%20What%20Works%20report%20brief%20FINAL%20for%20web.pdf>. Accessed January 14, 2009.

Topical Steroids for Therapeutic Use in the Posterior Segment

Dr. Gallemore: When treating any retinal disease, we strive to provide our patients with the best options that take into account not only visual acuity, but also safety and ease in delivery. As research advances and our understanding of the pathogenesis of retinal disease increases, we are finding different ways to address the multiple factors that are involved. In diabetic macular edema (DME) for example, we know that vascular endothelial growth factors (VEGF) and inflammatory factors are major contributors. Thus, there has been an initiative to investigate the role of anti-VEGF injections and intravitreal steroids, alone and in combination with laser. Sustained delivery of steroids for DME is also a promising treatment and we anticipate US Food and Drug Administration (FDA) approval of the sustained delivery fluocinolone acetonide

insert (Iluvien; Alimera Sciences, Alpharetta, GA) in the near future.

Topical delivery of steroids would be the ideal scenario, as we could obviate the concerns associated with more invasive platforms. However, is there a role for topical steroids in treating retinal disease? Can topical drops penetrate ocular tissue to reach the back of the eye and treat disease such as DME? This is the issue that we will discuss in this supplement to *Retina Today*.

Editor's note: Difluprednate is approved by the US Food and Drug Administration for the treatment of inflammation and pain associated with ocular surgery. The applications discussed herein constitute off-label use.



Ron P. Gallemore, MD, PhD:

I am Founder and Director of the Retina Macular Institute and Research Center in Los Angeles and on the Clinical Faculty at the University of California, Los Angeles. In my private practice, which consists of five office locations and three physicians, we see a variety of retinal disorders including age-related macular degeneration (AMD), diabetic retinopathy (DR), retinal vein occlusions, uveitis, postoperative complications, trauma, and tumors.



Alexander Eaton, MD:

I am part of a two-physician private retinal practice in Southwest Florida, and I am on the Clinical Faculty of the Duke University Medical Center. We have a predominately senior population, and therefore, see a wide spectrum of retinal disorders including AMD, retinal vascular disease, DR, retinal detachments, uveitis, and postoperative complications.



Keith A. Warren, MD:

I am in private practice in Kansas City and am a Clinical Faculty member at the University of Kansas, where I was formerly the Chair of the Ophthalmology Department. Our practice has

two offices and our cases are similar to those that Dr. Gallemore and Dr. Eaton have described—AMD, DR, and postoperative complications. During my residency and fellowship, I had specialty training in uveitis. I see many patients with inflammatory ocular disease and have an interest in cystoid macular edema (CME).



Seenu M. Hariprasad, MD:

I am in practice at the University of Chicago Medical Center and an Associate Professor and the Director of Clinical Research at the University of Chicago Department of Surgery, Section of Ophthalmology and Visual Science. I am currently the Chief of the Vitreoretinal Service and Director of the Surgical Retina Fellowship Program. Like the rest of the panel, I primarily treat AMD, DR, postoperative posterior complications, and uveitis.



Daniel M. Miller, MD, PhD:

I am a member of a large multispecialty hybrid private/university practice group, the Cincinnati Eye Institute, where I train residents and fellows. I am also voluntary Assistant Professor in the Department of Ophthalmology, University of Cincinnati. I treat a similar spectrum of diseases as mentioned previously.

Topical Steroids for Therapeutic Use in the Posterior Segment

RATIONALE FOR STEROIDS IN RETINAL DISEASE

Dr. Gallemore: What data are available to support the use of steroids for retinal disease?

Dr. Eaton: The last time I performed a pubmed search on topical steroids and general eye diseases, I received a list of over 1,000 articles. Clearly, there is a vast amount of research that has been performed over many years.

Dr. Gallemore: Inflammatory cascades and mediators are involved in many eye diseases and so it makes sense, from a scientific standpoint, that steroids would play an important role in management.

Dr. Warren: In looking at how we currently treat retinal disease, it is clear that we have made tremendous advances, particularly in an understanding of the pathophysiology of the disease. There is significant evidence pointing to a role for steroids, particularly for DME. For example, Adamis and Berman¹ published a paper that showed an inflammatory component to diabetic retinopathy (DR) and suggests a multimodal treatment approach with not only steroids, but anti-VEGF and non-steroidal anti-inflammatory drugs (NSAIDs).

At the 2010 American Society of Retinal Specialists (ASRS) meeting, I presented a paper on combination therapy for DME that showed evidence that, when using all three of these medications, we can at least reduce the treatment burden of DME.² We have many years of experience using steroids to treat uveitis, and we now have evidence that steroids can be used successfully for retinal venous occlusive (RVO) disease.^{3,4}

Dr. Gallemore: Dr. Eaton, have you had any experience with RVO and steroid treatment or combination therapy?

Dr. Eaton: I have found that steroids have played a bigger role in my practice over the last few months. My initial therapy for RVOs is generally an anti-VEGF agent.^{5,6}

I am finding, however, that with RVOs, along with DME and AMD, an increasing number of patients who have been on anti-VEGF therapy for extended periods of time are beginning to show resistance. When these patients are given steroids, however, the chronic edema can often be completely eliminated and the effect maintained with continued therapy.

Dr. Gallemore: Combination therapy has proven critical for managing chronic edema associated with DME, RVO, and even wet age-related macular degeneration (AMD). For those patients that have chronic edema after initial anti-VEGF therapy, I have found a combination of

topical steroid, NSAID, and carbonic anhydrase inhibitors (CAI) drops can reduce the chronic edema and improve vision. I also use this combination acutely in some cases. Before initiating treatment with anti-VEGF drugs for RVO, for example, I will pre-treat with topical antibiotics and lid hygiene and schedule the injection for 1 week. I concurrently initiate treatment with topical difluprednate, NSAID, and CAI drops three times daily and often note a significant improvement in edema when the patient returns for the injection. In some cases, we hold the injection if the topical drops alone have produced a dramatic improvement.

Dr. Warren: Most of us have tried intravitreal injections for diffuse DME because we have not seen great results with laser. The results from the Diabetic Retinopathy Clinical Research Network supported laser as the standard of care for DME.⁷ It also showed, however, that steroids are effective in the short term and as such, this has modified how I currently treat my patients. I will treat initially with laser, but I will begin dosing with difluprednate immediately after so that the benefits of laser can be continued with steroid.



Combination therapy has proved critical for managing chronic edema.

- Ron Gallemore, MD, PhD

Dr. Miller: I most commonly use steroids postoperatively. The typical postoperative regimen involves the use of topical steroids, sometimes in conjunction with NSAIDs. I also commonly use intravitreal and periocular steroids to treat diffuse DME and macular edema from RVO.

Dr. Gallemore: Recently, topical difluprednate ophthalmic emulsion 0.05% (Durezol, Alcon Laboratories, Inc.) has become available. Practically speaking, do we need another steroid considering the success that we have had using injections of steroids up to this point? What are the advantages to having a topical formulation and what are the challenges?

Dr. Eaton: Not all patients want to undergo injections with steroids—that is the advantage of topical difluprednate. To my knowledge, this is the first time we

Topical Steroids for Therapeutic Use in the Posterior Segment

have had a steroid drop that has tremendous penetration and the ability to treat cystoid macular edema (CME). Prior to the availability of difluprednate, my approach to CME was to give an initial periocular injection of triamcinolone acetate and possibly two or three subsequent injections. If I saw no response, I would switch to an intravitreal triamcinolone acetate injection. I never took topical steroids seriously, but with difluprednate, I have seen patients who were non-responders to periocular and intravitreal injections respond to topical difluprednate.

Dr. Hariprasad: I agree. In regard to topical steroids, we need a drug with superior dosing uniformity. Does the first drop in the bottle have an equal concentration to the last drop? We also need a steroid with a better side effect profile and increased penetration—it is obviously important that the agent we are using reaches the



Having a topical agent that provides penetration and potency will increase patient compliance.

- Keith Warren, MD

site of action. Finally, we need a steroid with increased anti-inflammatory activity.

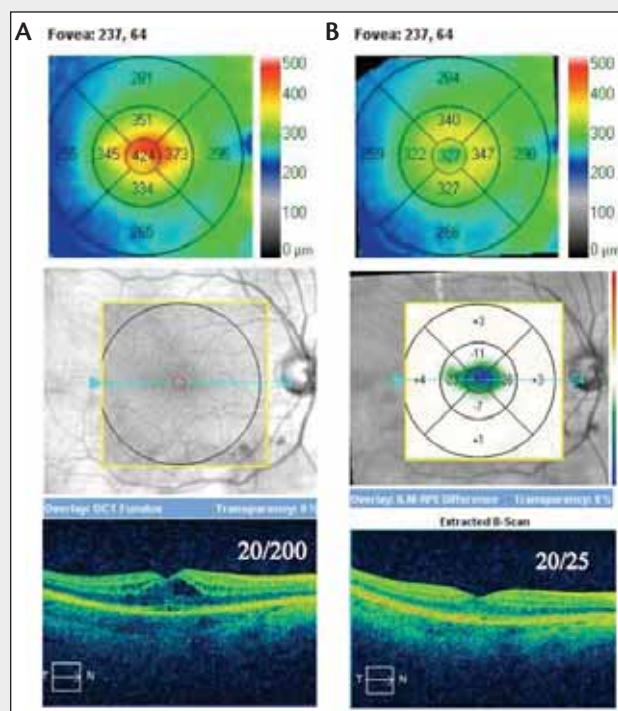
STERIOD UTILITY FOR RETINAL SURGERY

Dr. Gallemore: When I perform a vitrectomy for DME or macular pucker, the optical coherence tomography (OCT) scans show significant preoperative edema. Although the postoperative OCTs indicate that some of

CASE REPORTS

CASE 1: MANAGEMENT OF POSTOPERATIVE CYSTOID MACULAR EDEMA (CME) FOLLOWING CATARACT SURGERY

The patient failed a 6-week course of treatment with prednisolone acetate 1% and ketorolac 0.4% four times daily. After



treatment for 2 weeks with a combination of topical difluprednate, nepafenac, and brinzolamide (Azopt, Alcon Laboratories, Inc.) the patient improved to 20/25 (Figure 1).

CASE 2: MANAGEMENT OF MACULAR EDEMA ASSOCIATED WITH CENTRAL RETINAL VEIN OCCLUSION

The patient elected treatment with topical difluprednate combination therapy instead of an intravitreal injection of steroids or anti-VEGF therapy. The patient demonstrated a marked improvement in vision from 20/200 to 20/30 and

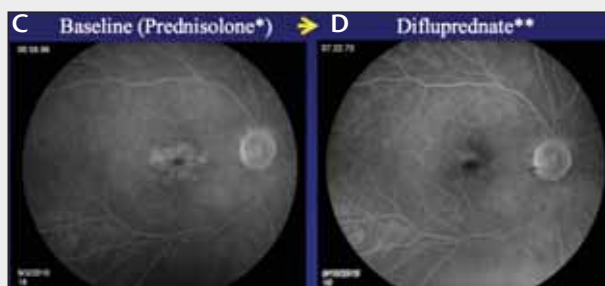


Figure 1. Panels show high resolution Cirrus OCT (Carl Zeiss Meditec, Dublin, CA) images before (A) and after (B) treatment with contour maps (top), difference maps (middle), and horizontal cross sections (below). Reduction in macular leakage demonstrated on fluorescein angiography before (C) and 2 weeks after treatment with the difluprednate combination therapy (D).

Topical Steroids for Therapeutic Use in the Posterior Segment

the edema has been eliminated, a fair amount often persists. When fluorescein angiography shows persistent leakage, I use topical difluprednate for a short phase to treat the postoperative inflammation and then for a longer phase to treat the residual chronic edema.

In your own experience, have you found therapeutic indications for steroids after retinal surgery?

Dr. Eaton: Simple cases, like nonclearing vitreous hemorrhages, macular puckers, or macular holes in which there is no significant postoperative inflammation, may not require much in the way of postoperative steroids barring residual CME. For more protracted and difficult situations, such as proliferative vitreoretinopathy (PVR) or proliferative diabetic retinopathy (PDR), during which extensive laser has been applied or where there are residual lens fragments, and underlying inflammation exists, I find that the use of topical difluprednate is significantly

more effective than the use of topical prednisolone acetate. Difluprednate is also useful to control inflammation following an injection of intravitreal antibiotics in the treatment of infectious endophthalmitis. I have also found that for chronic postoperative CME or DME, I can achieve excellent results with difluprednate, which I had not seen before with other topical steroid formulations.

Dr. Warren: I agree. I believe that we must stratify our cases; for example, a diabetic nonclearing vitreous hemorrhage does not require aggressive steroid treatment. For these cases, we can apply a routine regimen of four-times-daily moderately potent (prednisolone acetate) steroids. There are certain cases, however, that warrant more aggressive steroid therapy, and having a topical agent that provides penetration and potency will 1) increase patient compliance, and 2) increase the amount of potent drug that is delivered to the target tissue. In the past, I pre-

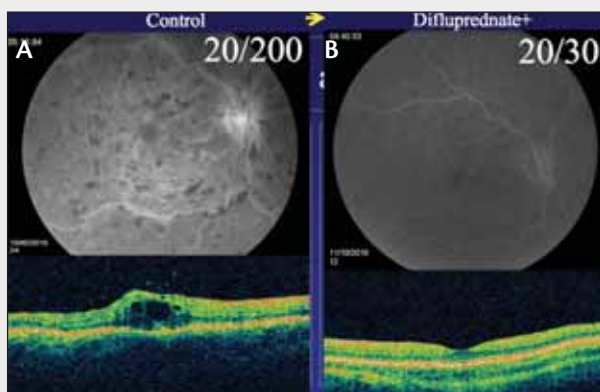


Figure 2. Panels show fluorescein angiography and high resolution Cirrus OCT images before (A) and after treatment with difluprednate combination therapy. There is marked reduction in macular leakage demonstrated on fluorescein angiography (B, top) and retinal thickness on OCT (B, bottom).

reduction in macular edema with decreasing retinal edema on combination therapy of difluprednate three times daily, bromfenac (Xibrom, Ista) once daily and dorzolamide (Trusopt, Alcon Laboratories, Inc.) three times daily after approximately 5 weeks of treatment (Figure 2).

Cases 1 and 2 submitted by Ron P. Gallemore, MD, PhD

CASE 3: CHRONIC CME

A 71-year-old woman presented with chronic cystoid macular edema (CME) and a history of a macular pucker in her right eye, for which she had undergone pars plana vitrectomy with removal of the macular pucker 9 years ago. The patient had been treated step-wise for CME with topical prednisolone acetate 1%, posterior sub-Tenon triamcinolone acetonide, intravitreal triamcinolone acetonide, along with acetazolamide,

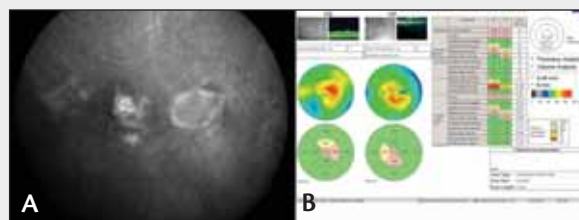


Figure 3. Fluorescein angiography at presentation (A). OCT and retinal thickness maps (B).

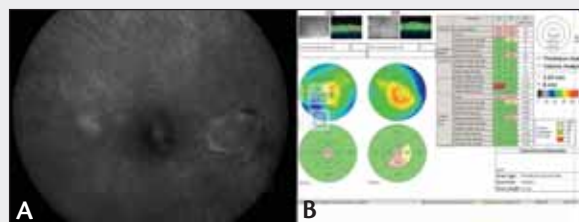


Figure 4. Fluorescein angiography after treatment (A). OCT and retinal thickness maps (B).

and ketorolac (Acular, Allergan, Inc.).

On presentation, the patient's vision was 20/60 in the right eye and the central macular thickness (CMT) measured 312 μm on optical coherence tomography (OCT). Figure 3A shows the patient's fluorescein angiography at presentation. Figure 3B shows the patient's OCT and retinal thickness maps.

We initiated therapy with difluprednate and nepafenac three times daily. At follow-up, less than 3 months later, the patient's vision had improved to 20/50 with a pinhole visual acuity of 20/30 in the right eye and the CMT had improved to 281 μm on OCT. Figure 4A shows the patient's fluorescein angiography after treatment. Figure 4B shows the patient's OCT and retinal thickness maps.

Case 3 submitted by Alexander Eaton, MD

Topical Steroids for Therapeutic Use in the Posterior Segment

ferred steroid ointments because they stay on the surface of the eye, but patients tend to not be compliant with ointments and so the benefits were minimized.

Dr. Gallemore: Compliance can be an issue when treating any retinal disorder. Even in the case of simple postoperative inflammation after vitrectomy or scleral buckle surgery, non-compliance can increase the risk of complications such as CME. For those who already have macular edema or uveitis and require long term management, compliance is even more critical. We now have a strong steroid that can be used once or twice a day to effectively manage ocular inflammation in the short and long term. The efficacy of this steroid is without question—a recent study by Nakano et al⁸ showed that topical difluprednate is comparable to sub-Tenon steroids in the setting of post-vitrectomy for DME. Indeed, we now have a strong topical steroid that can be comparable to an injection with the benefits of non-invasive treatment and an adjustable dose schedule.

Dr. Hariprasad: I use steroids in all my patients post-operatively. In the past, I would dose a topical steroid four times a day after surgery, but with difluprednate in conjunction with nepafenac (Nevanac, Alcon Laboratories, Inc.), I am able to reduce the dosing schedule and achieve the same control of postoperative inflammation.

The Nakano study provides evidence that there may be some utility for steroids in the back of the eye. This was a nonrandomized case control study, and patients enrolled all had persistent refractory DME despite pars plana vitrectomy and were not treated for 3 months prior to enrollment. Patients were randomized to two groups. In the first group, 11 eyes in seven subjects were given difluprednate four times a day for 1 month and then twice a day for 2 months. The second group consisted of 11 eyes in 10 patients who were given a sub-Tenon injection of triamcinolone acetonide. The main efficacy measures were best corrected visual acuity (BCVA) and macular edema on OCT.

At 3 months, visual acuity and retinal thickness was equivalent between difluprednate and sub-Tenon injection of triamcinolone acetonide, and the authors concluded that difluprednate can be safely and effectively used for the treatment of refractory DME.⁸

There are numerous advantages to using postoperative topical steroids after surgery instead of sub-Tenon injections. First, the drop can be administered immediately after surgery. Second, the dosing regimen provides a constant supply of steroid to the eye vs sub-Tenon triamcinolone acetonide, which will wear off

over a certain amount of time. Third, a topical drop eliminates any concerns of infection associated with invasive injections. It is important to keep in mind that this was a small study that had numerous shortcomings, but these data suggest that additional, larger studies should explore difluprednate as monotherapy or in conjunction with other medications for posterior segment indications.



The advantage of a topical drop is that if an IOP rise does occur, the frequency can be reduced.

- Alexander Eaton, MD

Dr. Gallemore: After standard vitrectomy, how long will you use a traditional steroid, such as prednisolone acetate (Pred Forte, Allergan, Inc.), for nonclearing vitreous hemorrhage?

Dr. Warren: I frequently dose a steroid like prednisolone at a similar frequency to the topical antibiotic—three times a day—because it is easier for the patient. I taper after 1 week. I discontinue the antibiotic after the first week and then have the patient use one drop per day of prednisolone for approximately 3 to 4 weeks.

Dr. Eaton: I apply a similar regimen by dosing the prednisolone with the same frequency as the antibiotic. I begin the first week with three-times-a-day dosing if the antibiotic is moxifloxacin (Vigamox, Alcon Laboratories, Inc.) or four times a day if it is gatifloxacin (Zymar, Allergan, Inc.). I taper the prednisolone over the same time period as Dr. Warren, but instead of stopping the antibiotic after 1 week, I have the patient continue it until it runs out.

Dr. Gallemore: What is your dosing regimen with difluprednate?

Dr. Hariprasad: My postoperative regimen includes moxifloxacin (Vigamox, Alcon Laboratories, Inc.) four times a day for 1 week, isoptohyosine twice a day for 1 week, nepafenac three times a day until the bottle runs out, and difluprednate three times a day for the first week, and then twice a day until the bottle runs out.

Dr. Miller: My regimen changes depending on the type

Topical Steroids for Therapeutic Use in the Posterior Segment

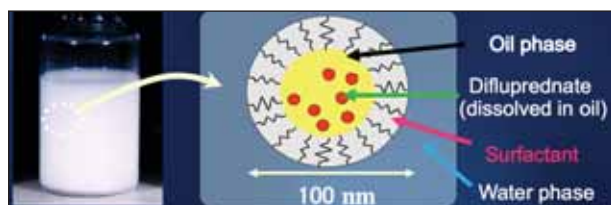


Figure 1. In the manufacturing process, castor oil is used to stabilize the difluprednate in water and a surfactant is used to surround the molecule, allowing it to dissolve.

of surgery and the general pathology, so I tailor my regimen to each specific patient. For less complex surgeries, such as epiretinal membrane and macular hole, I typically use a topical antibiotic for 1 week and topical prednisolone 1% four times a day for 1 week. The antibiotic is discontinued at the end of the first week, and the topical prednisolone is slowly tapered over a period of 4 weeks. For eyes with more inflammation, whether from inflammatory eye disease or inflammation-producing procedures like scleral buckle or combined scleral buckle and vitrectomy, I am more aggressive with topical steroids. In the past, I would use topical prednisolone acetate every 2 hours during the first postoperative week. However, I have had good results with topical difluprednate in these patients. I use difluprednate four to six times per day in the first week followed by a tapering dose over the ensuing 4 weeks.

Dr. Gallemore: What are some of the advantages and disadvantages of the various methods of steroid delivery postoperatively?

Dr. Warren: The advantages of using intravitreal steroids include the fast action and direct delivery of drug. The disadvantages, of course, are a higher incidence of increased intraocular pressure (IOP) and the formation and progression of cataracts.

The advantages of topical application include that the patient has ownership and is involved in his or her own care and if the steroid is potent, the drug can be administered with efficacy. Topical steroids can also lead to increased IOP, but my clinical experience has been that this occurs most commonly after a longer duration—approximately 4 to 6 weeks. None of my patients who had increased IOPs with topical steroids have required surgery, but if you are applying a more potent steroid like difluprednate, IOP rise should be considered.

Dr. Eaton: The advantage of a topical drop is that if an IOP rise does occur, the frequency can be reduced—the medication is not “locked” in or around the eye as with intravitreal or periocular steroids, and it can be

modulated. We should keep in mind, however, as Dr. Warren noted, that if we are dosing a stronger steroid like difluprednate, it can lead to higher IOP rises. Use of topical steroids also avoids complications such as sterile endophthalmitis or the snow-globe effect, both which can occur following intravitreal steroid injections,⁹ along with the associated visual acuity drops that can be stressful for both patients and physicians.

Dr. Miller: The advantage of topical delivery is that you can titrate the amount of steroid that you are giving to the patient by adjusting the frequency of dosing. With periocular or intravitreal steroids the dose may be larger than what is really needed postoperatively for most surgical procedures. Topical delivery, however, allows the surgeon to tailor therapy based on the eye's response. Topical prednisolone, both the generic and branded formulations, have been our mainstay for some time, and they are highly effective with side effect profiles that are similar to most other steroids. Difluprednate, which is more potent and which we have used since its recent availability, is particularly helpful in cases with inflammation because you can dose it less frequently than prednisolone acetate.

I have not seen any differences in the side effect profile of difluprednate vs prednisolone acetate. I have not had much of an issue with IOP rises, but like the rest of the panel, I do not use it for more than 4 to 6 weeks. If I see IOP increase, it tends to be during the tapering phase and is not usually much of an issue. IOP increase is more likely to present an issue when patients are being treated for chronic inflammatory disease or another chronic disease and patients are exposed to the steroid for a long period of time with repeated dosing.

Most cases of IOP increases can be managed by adding a topical glaucoma medication—most patients respond readily to this approach. Occasionally, patients with either underlying glaucoma or a profound increased IOP that is not responding to topical drops will require filtering surgery.

Dr. Gallemore: I agree that topical steroids offer greater flexibility in dosing. In my practice, I have combined difluprednate with a CAI because topical CAIs have been shown in a few small studies to help treat macular edema with varying etiologies.¹⁰⁻¹²

I have found that there is a learning curve associated with understanding how difluprednate affects IOP. Retina specialists tend to use drugs on more of a chronic basis than our anterior segment colleagues and so we are more likely to see IOP spikes. To minimize surprise IOP spikes, I hit the inflammation hard with steroid early on and then

Topical Steroids for Therapeutic Use in the Posterior Segment

Reprinted with permission from Stringer W, Bryant R. Dose uniformity of topical corticosteroid preparations: difluprednate ophthalmic emulsion 0.05% versus branded and generic prednisolone acetate ophthalmic suspension 1%. *Clin Ophthalmol*. 2010;4:1119-1124. Copyright Dove Press.

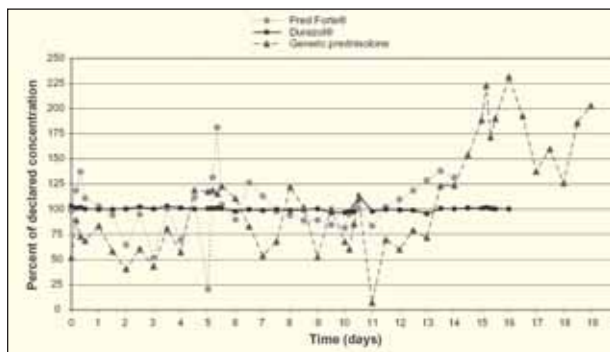


Figure 2. Difluprednate showed an even percentage of concentration from day 0 to day 15 when the bottles were inverted and not shaken.

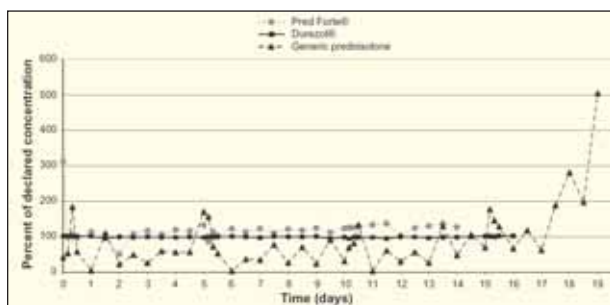


Figure 3. When the bottles were stored upright and not shaken, difluprednate had a uniform dose concentration. Both concentrations of the generic prednisolone acetate and Pred Forte vary widely.

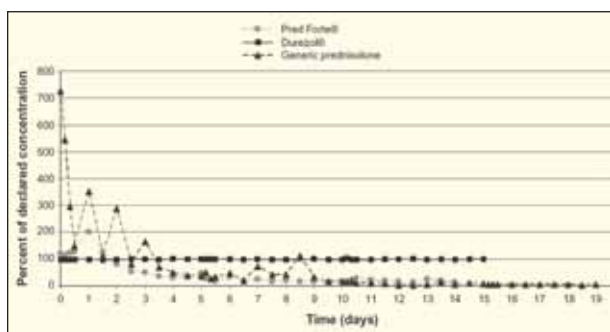


Figure 4. Even when upright and shaken, Pred Forte is over 300% of the label claim early on and by the end of the study, slightly over 100%.

quickly taper with a lower dose for chronic use.

I have protocols in which I use difluprednate four times daily for 1 day, three times daily for the next day, twice daily for the third day, and then once daily for 2 weeks or so until the edema is under control, and finally every other day. This demonstrates the flexibility and potency with this stronger steroid.

Do you recommend prophylactic steroids to address potential posterior segment complications related to

anterior segment surgery or do you use them yourself in cases that are referred to you?

Dr. Eaton: For many years, I have recommended prophylactic periocular 40 mg triamcinolone acetonide injections for patients with diabetes and background diabetic retinopathy prior to anterior segment surgery. Unfortunately, these injections can cause a rise in blood glucose levels, which I warn patients about. Now that topical difluprednate is available, I think it is a good alternative for our anterior segment colleagues. Ideally, difluprednate should be dosed preoperatively, and its use should be continued postoperatively to reduce the development of DME and CME.¹³

Dr. Warren: In my opinion, two types of patients can benefit from aggressive preoperative steroid therapy: those with a history of uveitis and those who have a retained or dislocated lens fragments. In patients with a history of uveitis, it is important to quiet the eye as much as possible prior to surgery. For a retained or dislocated lens, patients present with inflamed eyes, and the preoperative period offers an excellent opportunity to use a potent steroid without having to introduce a periocular injection.

Dr. Gallemore: When I have a patient who I consider high risk, such as a patient with diabetes or uveitis, I check the OCTs and the fluorescein angiograms and am often surprised to see that many of these patients have some edema and/or leakage. So, this is a good opportunity to not only treat the active disease, but to also minimize the potential complications of surgery. I like to use a topical, strong steroid preoperatively and then, in some cases, in a sustained manner postoperatively for high-risk patients.

TOPICAL STEROID FORMULATION AND DOSE UNIFORMITY

Dr. Gallemore: In regard to a topical steroid's efficacy in the eye, what is the difference between suspension vs emulsion drops?

Dr. Warren: Many of the drops that are currently being used in the eye, particularly corticosteroids, are suspensions—there is a viscous phase that is separate from the more lipid phase. Suspensions must be shaken to become miscible, up to 30 times, and because many patients do not fully comply with this requirement, uniform delivery of such a substance is a problem. In contrast, an emulsion is a heterogeneous mixture of fluids in a lipid phase, which results in better uniformity in delivery of molecules.

Topical Steroids for Therapeutic Use in the Posterior Segment

Dr. Hariprasad: Difluprednate is a unique emulsion. An emulsion is a mixture of two immiscible liquids, such as oil and water, and the difluprednate drug substances are dissolved in the oil phase of the emulsion. In the manufacturing process, castor oil is used to stabilize the difluprednate in water and a surfactant is used to surround the molecule, allowing it to dissolve (Figure 1). At the end of this process, the difluprednate emulsion is stable, and the oil droplets will not separate. The process is very complex and is not something that is encountered with generic emulsion formulations.

Dr. Gallemore: From a patient perspective, the requirement of shaking a bottle 20 to 30 times is impractical. There are studies that demonstrate a two- to fivefold greater penetration with emulsions.^{14,15}

Dr. Eaton: Elderly patients, in particular, have difficulty with the “shaking” instructions. For this population, an emulsion would be extremely advantageous.

Additionally, we usually want to treat our patients with the strongest treatment early on, and if the drops are not being shaken to the necessary level, the result will be sub-optimal concentrations.

Dr. Gallemore: What is the importance of dose uniformity and how do you think the different steroid preparations affect dose uniformity?

Dr. Warren: An interesting example of dose uniformity comes from our treatment of AMD with intravitreal ranibizumab (Lucentis, Genentech). As long as we give the injections on the FDA-approved dosing schedule of once a month, we generally find that patients do well. Once we allow the drug levels in the eye to decline, however, by treating on an as needed or another reduced dosing schedule, we tend to see recurrence of disease. The same rule appears to apply to uveitis, for example, with regard to steroid dosing. As long as there is a uniform level of drug available in the eye, the inflammatory response is adequately suppressed. Once that level starts to drop off, however, we begin to see a recurrence of the inflammation.

These examples make the importance of uniform drug delivery to the target tissue clear. Having the knowledge that the appropriate level of drug is being delivered is critical.

Dr. Hariprasad: Stringer et al conducted a study to test the dose uniformity of branded (Pred Forte 1%) and generic prednisolone acetate (1%) suspensions vs

difluprednate emulsion. The study was designed to determine if the position and shaking of the bottle affects the amount of ingredients in the drops compared with the concentration claim on the labels.

All products were stored under identical conditions. The bottles were stored for 12 hours in a designated position—either inverted or upright—and after 12 hours were either not shaken or mechanically shaken for 5 seconds. Two drops were dispensed from each bottle four times a day until no more drops were left in the bottles. The drops were then analyzed for drug content and compared to the concentration stated on the labels.



Compliance is always an issue with any of the therapies that we recommend to our patients.

- Dan M. Miller, MD, PhD

Figure 2 shows the drops from the bottles that were inverted and not shaken. Across the board, difluprednate showed an even percentage of concentration from day 0 to day 15. The generic prednisolone acetate, however, registered as more than 700% on day 0 of the label concentration and varied widely throughout the time period—at day 14, the concentration was 0% of label concentration. The percentages with Pred Forte were less dramatic, but at day 0, the concentration was 200% of the label claim and by day 3 it was under 50% of the label claim.

Figure 3 shows the percentages of label concentration between the three steroids when stored upright and not shaken. Again, difluprednate had a uniform dose concentration across the board. Both concentrations of the generic prednisolone acetate and Pred Forte, however, again vary widely. Even when upright and shaken (Figure 4), Pred Forte is over 300% of the label claim early on and by the end of the study, slightly over 100%. The dose uniformity of the generic prednisolone acetate is extremely poor in this scenario. Difluprednate continued to remain steady at 100% of the label concentration.

All of us have had the patient who we treat with topical steroids and for whom the four times a day regimen goes well for a few days. When we try to taper, however, the patient presents at follow-up with angry rebound inflammation. Our first response is to blame the patient for noncompliance. These data from Stringer et al, however, show that it is not necessarily a compliance issue, but a dose uniformity issue.

Topical Steroids for Therapeutic Use in the Posterior Segment

Dr. Miller: In my experience, compliance is always an issue with any of the therapies that we recommend to our patients. If a patient has chronic uveitis for example, a drug that is potent enough to be given less frequently will help improve patient compliance. Studies have shown at least a twofold increase in potency of difluprednate compared with prednisolone acetate in patients with anterior uveitis.¹⁶ This enhanced potency may allow half the number of drops per day compared with prednisolone, while achieving similar or better control of inflammation.

In regard to dose uniformity, we are careful to instruct patients that they need to shake the prednisolone acetate bottles, but I am certain that only a small fraction of patients actually follow these instructions. With difluprednate, I know that the amount of steroid that is being delivered is the intended dose.

STERIODS FOR POSTERIOR UVEITIS

Dr. Gallemore: How do you treat posterior uveitis in your own practice?

Dr. Warren: It is important to perform an appropriate work-up and evaluation for patients with posterior uveitis so that a full understanding of the disease process is possible so we can tailor the treatment. Steroids remain the mainstay of therapy in posterior uveitis and the current standard of care is intravitreal injections of steroids and/or vitrectomy.

Dr. Hariprasad: Uveitis is an interesting and variable disease. It is important to determine the cause, grade the severity as mild, moderate, or severe, and identify the location—anterior, intermediate, or posterior.

For more mild cases that are noninfectious, I will likely begin treatment with a topical steroid and if I see an inadequate response, I will escalate treatment to a sub-Tenon or intravitreal injection of triamcinolone acetonide. Given the recent FDA approval of sustained delivery dexamethasone (Ozurdex; Allergan, Irvine, CA) for posterior uveitis, I will try dexamethasone in some patients failing topical therapy or those needing frequent periocular or intravitreal steroid. For more severe cases, I may dose systemic steroids or possibly systemic cyclosporine, although I like to exhaust all ocular local therapies before trying systemic immunosuppressants. Many retina specialists feel uncomfortable managing uveitis because it often requires a systemic workup, systemic treatment, and laboratory monitoring.

Dr. Miller: It is hard to generalize treatment regimens for posterior uveitis because there are many underlying

presentations and comorbidities. Most patients who I see in my practice for posterior uveitis have been referred because they have already failed topical steroid therapy, so I tend to use periocular or intravitreal steroids combined with systemic immunosuppressant agents. However, I have found a significant role for topical steroids in many patients. Topical steroids may be utilized to prolong the time between more invasive treatments such as intravitreal and periocular injections. The increased potency of difluprednate is extremely valuable in uveitis patients.



Dose uniformity along with the potency, penetration, and flexibility of a topical steroid is critical to its utility for retinal disease.

- Seenu Hariprasad, MD

Although there are no data on topical steroids for posterior uveitis, there is one study in which 55 of the 136 enrolled patients had panuveitis and were treated with either difluprednate or betamethasone, in which superiority in both more rapid effects and potency against inflammation was shown for difluprednate. These data suggest a positive effect of difluprednate on posterior segment inflammatory disease.¹⁷

Dr. Eaton: I do not see many patients with posterior uveitis; more commonly patients present with intermediate uveitis or pars planitis. I have treated patients primarily with periocular steroids and intravitreal steroids as needed. The reason I did not use topical steroids often was due to lack of patient compliance. As we discussed, patient compliance and dose uniformity with topical difluprednate is vastly improved over other topical preparations, and I have had excellent results with this drug. I start with frequent dosing to bring the inflammation down and then reduce the dosing schedule to once a day to maintain the effect.

For the few cases of posterior uveitis that I do see, my current regimen involves topical difluprednate, periocular steroids, or intravitreal steroids. If the posterior uveitis persists or is particularly severe, I refer the patient for systemic therapy.

Dr. Gallemore: Once you have ruled out an infectious etiology for posterior uveitis, treatment with diflupred-

Topical Steroids for Therapeutic Use in the Posterior Segment

nate may be a good option. The Foster et al¹⁶ data that Dr. Miller referenced earlier that showed a twofold increase in potency of difluprednate when compared to branded prednisolone acetate are encouraging. Although these data are specific to anterior uveitis, they clearly show that difluprednate is a more potent topical steroid.

What challenges do you find in deciding whether to implant the fluocinolone acetonide device (Retisert, Bausch + Lomb), the dexamethasone device?

Dr. Warren: I have a particular interest in being able to provide my patients with posterior uveitis with appropriate anti-inflammatory effects using a topical medication because many of these patients require chronic, aggressive therapy. There is a rebound effect in between injections, even in those for whom we inject intravitreally. Although the implants provide a sustained effect, there is a much higher rate of cataract formation and steroid-induced glaucoma, particularly with the fluocinolone acetonide implant. The challenge is to have a therapy that is strong and durable, sustainable in terms of delivery, and that has a more tolerable side effect profile. I am hopeful that topical difluprednate represents the alternative.

Dr. Eaton: In my past experience, treating patients with prednisolone eight times a day was not a sustainable solution, but if we can cut that dosing schedule in half with a more potent topical steroid, patients will be more likely to comply and we can achieve better results.

Dr. Gallemore: Some patients with uveitis have associated hypotony, which is one instance where we welcome an IOP spike. I have used the fluocinolone acetonide implant for these patients with success, but now I have supplanted my use of the implant with topical difluprednate, which helps control chronic hypotony and does not require a surgical procedure.

Dr. Warren: I have had a few patients with severe nodular scleritis for whom I have used difluprednate and an NSAID, and the inflammation responded rapidly to this treatment. In cases of uveitis-related hypotony, as Dr. Gallemore described, it is critical to get as much drug to the sclerotic body as possible, which topical difluprednate achieves. Again, the dose uniformity provides an advantage and an alternative to injections.

TAKE-HOME MESSAGES

Dr. Gallemore: In your opinion, what is the most



I believe that we will see a rise in the number of applications for the topical delivery of steroids.

- Ron Gallemore, MD, PhD

important point that readers should take away from this roundtable discussion?

Dr. Warren: Patients with DME and PVR or with dislocated lenses and significant anterior and posterior segment inflammation may benefit from a potent topical steroid. Data are in development showing the efficacy of topical difluprednate for treating DME as opposed to periocular or intravitreal injections. Because this drug is an emulsion and a potent steroid, the distribution is more uniform, and the levels of drug that reaches the target tissues are higher. Additionally, these characteristics translate to more durable anti-inflammatory effects and enhanced patient compliance with fewer daily doses.

For less complicated cases of uveitis, topical difluprednate provides an alternative to injections or implants with a better side effect profile that translates to lower rate of morbidities resulting from treatment.

Dr. Eaton: Topical difluprednate has the potential to represent a paradigm shift for the treatment of intraocular inflammation, particularly when it is complicated by vitreous and macular involvement. I have used prednisolone acetate and NSAIDs to treat posterior segment inflammation and cystoid macular edema in the past, but their efficacy is such that most patients will go on to require periocular or intravitreal steroids in order to clear the inflammation and the edema. However, with difluprednate that is frequently not the case; after 2 to 4 weeks of therapy, the inflammation and CME are often completely resolved leaving little doubt as to its efficacy.

Dr. Hariprasad: Dose uniformity along with the potency, penetration, and flexibility of a topical steroid is critical to its utility for retinal disease. Further studies on the efficacy of topical steroids in the back of the eye are required, but the data we have thus far look promising. Our goal is to decrease the treatment burden while achieving good results for our patients, and if we can find a way to deliver effective drugs topically and reduce the

Topical Steroids for Therapeutic Use in the Posterior Segment

need for sub-Tenon or intravitreal steroids, this will be a big advantage.

Dr. Miller: All therapies that we consider should be individualized to fit the patient in front of us. No two patients are the same and the more options that we have available, the better. Previously, we had only one widely used option in prednisolone acetate; we now have a more potent steroid to add to our armamentarium.

Dr. Gallemore: In difluprednate, we now have one of the most potent topical steroids for uniform delivery as an emulsion. It allows for an adjustable dose in contrast to injections and implants along with better potency, reduced dosing frequency, and better compliance. We are beginning to see positive outcomes in the treatment of posterior uveitis and for complicated cases like uveitis-related hypotony and retinal vascular disorders, both as a primary and adjunctive therapy.

As the role of steroids for retinal disease increases, I believe that we will also see a rise in the number of applications for the topical delivery of steroids. ■

1. Adamis AP, Berman AJ. Immunological mechanisms in the pathogenesis of diabetic retinopathy. *Semin Immunopathol.* 2008;30(2):65-84.
2. Warren KA. Combination therapy for diffuse DME. Paper presented at: the American Society of Retina Specialists 28th Annual Meeting; August 28-September 1, 2010; Vancouver, BC.
3. Haller JA, Bandello F, Belfort R Jr, et al; OZURDEX GENEVA Study Group. Randomized, sham-controlled trial of dexamethasone intravitreal implant in patients with macular edema

- due to retinal vein occlusion. *Ophthalmology.* 2010;117(6):1134-1146.
4. The SCORE Study Research Group. SCORE Study Report 5. A randomized trial comparing the efficacy and safety of intravitreal triamcinolone with observation to treat vision loss associated with macular edema secondary to central retinal vein occlusion. *Arch Ophthalmol.* 2009;127:1101-1114.
5. Campochiaro PA, Heier JS, Feiner L, et al; BRAVO Investigators. Ranibizumab for macular edema following branch retinal vein occlusion: six-month primary end point results of a phase III study. *Ophthalmology.* 2010;117(6):1102-1112.
6. Brown DM, Campochiaro PA, Singh RP, et al; CRUISE Investigators. Ranibizumab for macular edema following central retinal vein occlusion: six-month primary end point results of a phase III study. *Ophthalmology.* 2010;117(6):1124-1133.
7. Diabetic Retinopathy Clinical Research Network. Three-year follow up of a randomized trial comparing focal/grid photocoagulation and intravitreal triamcinolone for diabetic macular edema. *Arch Ophthalmol.* 2009;127(3):245-251.
8. Nakano S, Yamamoto T, Kirii E, et al. Steroid eye drop treatment (difluprednate ophthalmic emulsion) is effective in reducing refractory diabetic macular edema. *Graefes Arch Clin Exp Ophthalmol.* 2010;248(6):805-810.
9. Stepien KE, Eaton AM, Jaffe GJ, Davis JL, Raja J, Feuer W. Increased incidence of sterile endophthalmitis after intravitreal triamcinolone acetate in spring 2006. *Retina.* 2009;29(2):207-213.
10. Genead MA, Fishman GA. Efficacy of sustained topical dorzolamide therapy for cystic macular lesions in patients with retinitis pigmentosa and usher syndrome. *Arch Ophthalmol.* 2010;128(9):1146-1150.
11. Genead MA, Fishman GA, Walla S. Efficacy of sustained topical dorzolamide therapy for cystic macular lesions in patients with X-linked retinoschisis. 2010;128(2):190-197.
12. Giusti C, Forte R, Vingolo EM, et al. Is acetazolamide effective in the treatment of diabetic macular edema? A pilot study. *Int Ophthalmol.* 2001;24(2):79-88.
13. Smith S, Lorenz D, Peace J, McLeod K, Crockett R, Vogel R. Difluprednate ophthalmic emulsion 0.05% (Durezol) administered two times daily for managing ocular inflammation and pain following cataract surgery. *Clin Ophthalmol.* 2010;4:983-991.
14. Stringer W, Bryant R. Dose uniformity of topical corticosteroid preparations: difluprednate ophthalmic emulsion 0.05% versus branded and generic prednisolone acetate ophthalmic suspension 1%. *Clin Ophthalmol.* 2010;4:1119-1124.
15. Yamaguchi M, Yasueda S, Isowaki A, et al. Formulation of an ophthalmic lipid emulsion containing an anti-inflammatory steroidal drug, difluprednate. *Int J Pharm.* 2005;301(1-2):121-128.
16. Foster CS, Davanzo R, Flynn TE, McLeod K, Vogel R, Crockett RS. Durezol (Difluprednate Ophthalmic Emulsion 0.05%) compared with Pred Forte 1% ophthalmic suspension in the treatment of endogenous anterior uveitis. *J Ocul Pharmacol Ther.* 2010;26(5):475-483.
17. Ohno S, Mochizuki M, Usui M, et al. A phase III, non-inferiority study of difluprednate ophthalmic emulsion (DFBA), 0.05% in the treatment of anterior uveitis [abstract]. *Invest Ophthalmol Vis Sci.* 2007;48:abstract 3904-B808.

Topical Steroids for Therapeutic Use in the Posterior Segment

1.0 AMA PRA Category 1 Credit™

Expires December 2011

CME credit is available electronically via www.dulaneyfoundation.org.

To answer these questions online and receive real-time results, please visit www.dulaneyfoundation.org and click "Online Courses." If you are experiencing problems with the online test, please e-mail us at support@dulaneyfoundation.org and explain the details of any problems you encounter with the Web site. Alternatively, you can fax your exam to us at +1-610-771-4443. Indicate how you would like to receive your certificate below. Please type or print clearly or we will be unable to issue your certificate.

Name _____ MD participant non-MD participant

Phone (required) _____ e-mail (required) _____

City _____ State _____

CME QUESTIONS

1. Adamis et al published data that showed an inflammatory component to diabetic retinopathy, suggesting treatment with _____?

- a. steroids
- b. anti-VEGF
- c. a combined approach with anti-VEGF, steroids, and laser
- d. none of the above

2. In Nakano et al, visual acuity and retinal thickness between eyes with refractory diabetic macular edema that received either topical difluprednate or sub-Tenon triamcinolone acetonide was:

- a. significantly better in the difluprednate eyes
- b. significantly better in the triamcinolone acetonide eyes
- c. equivalent
- d. none of the above

3. For some topical eye drop suspensions to achieve miscibility, the user must shake the bottle up to:

- a. 40 times
- b. 30 times
- c. 60 times
- d. no more than 10 times
- e. none of the above

4. The following statement is true regarding difluprednate emulsion:

- a. it is a mixture of two immiscible liquids
- b. in manufacturing, castor oil is used to stabilize the difluprednate in water and a surfactant is used to surround the molecule, allowing it to dissolve

- c. after the manufacturing process, the oil and water does not separate
- d. B and C

5. In the dose uniformity study by Stringer et al, the bottles of generic prednisolone that were inverted and not shaken emitted concentrations of drug that were ____ % of the label concentration.

- a. 50
- b. 200
- c. 700
- d. 100

6. Dose uniformity in suspensions rely directly on patient handling.

- a. true
- b. false

7. Which of the following statements is true:

- a. there are data from large randomized clinical trials showing the efficacy of topical steroid preparations for use in retinal disease
- b. there are no published data on the use of topical steroids for use in retinal disease
- c. there are data to suggest that topical steroids may have a role in retinal disease, but more data are required
- d. none of the above

Topical Steroids for Therapeutic Use in the Posterior Segment

Your responses to the questions below will help us evaluate this CME activity. This will provide us with evidence that improvements were made in patient care as a result of this activity as required by the Accreditation Council for Continuing Medical Education (ACCME). Please complete the following course evaluation and send it back to the Dulaney Foundation via fax at +1 610-771-4443.

Name _____

Do you feel the program was educationally sound and commercially balanced? Yes No

Comments regarding commercial bias:

Rate your knowledge/skill level prior to participating in this course: 5 = High, 1 = Low _____

Rate your knowledge/skill level after participating in this course: 5 = High, 1 = Low _____

Would you recommend this program to a colleague? Yes No

Do you feel the information presented will change your patient care? Yes No

If yes, please specify. We may contact you by e-mail in 1 to 2 months to see if you have made this change.

If no, please identify barriers to change.

List any additional topics you would like to see offered at future Dulaney Foundation programs or other suggestions or comments.
