

# Valved Cannulas: A Game Changer (With Caution)

Experience at the Duke Eye Center has shown valved cannulas to make surgery smoother and easier in comparison with nonvalved cannulas as long as certain precautions are taken.

BY PATRICK OELLERS, MD; AND PAUL HAHN, MD, PhD

Advances in cannula design may easily be overlooked in the midst of sexy new technologies such as faster and smaller-gauge vitrectomy machines, optical coherence tomography-enabled microscopes, and wider wide-angle viewing systems. The simple addition of silicone leaflets to the external opening of a cannula creates a valve that has become a game changer for vitreoretinal surgery (Figure 1; Video: [eyetube.net/?v=idepi](http://eyetube.net/?v=idepi)). Surgeons at Duke Eye Center began using valved cannulas in 2012. After a short transition phase in which both valved and nonvalved cannulas were used, these surgeons now exclusively use valved cannulas. The improved fluidics of valved cannulas impressed the surgeons, who also identified potential drawbacks during their early transition experience.

## CLOSED SYSTEM FLUIDICS

Valved cannulas, which allow closed system fluidics by minimizing egress of fluid through the cannulas,

### At a Glance

- The biggest advantage of valved cannulas is precise IOP control that can be maintained during surgery.
- Valved cannulas enable surgical maneuvers under silicone oil or PFO that were previously challenging.
- When using valved cannulas, it is advisable to place all three cannulas before inserting the infusion line.
- Caution is advised against PFO overfill to prevent postoperative retained PFO.

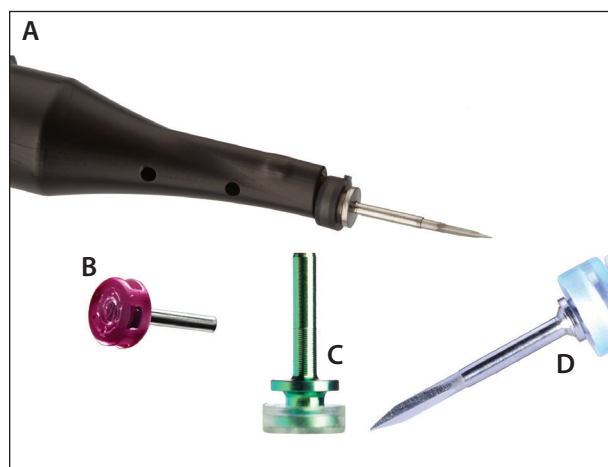


Figure 1. Valved cannulas: Low friction silicone leaflets placed at the outer opening of the cannula function as a valve, preventing egress of intraocular fluid.

bring numerous advantages to vitrectomy surgery. Perhaps the most important advantage is the precise intraocular pressure (IOP) control that can be maintained at all times during surgery, especially when combined with the modern IOP compensation capabilities of current vitrectomy machines.

Valved cannulas reduce episodes of transient hypotony that may be observed when nonvalved cannulas are left unplugged. They enable precise dynamic IOP modulation during surgery, which is particularly important when, for example, maintaining hemostasis during inadvertent intraocular bleeding. By reducing intravitreal fluid flow and turbulence, valved cannulas enable surgeons to apply chromovitrectomy agents to the surface of the retina in a controlled manner. Compared with dispersing such agents throughout

the eye, as in the high-flow circumstances involved with nonvalved cannulas, this is a significant advantage.

Reduced vitreous fluidic turbulence also minimizes formation of perfluoro-n-octane (PFO) bubbles, which frequently form in large numbers during the increased flow associated with instrument exchange in an open system with nonvalved cannulas.

Additionally, valved cannulas facilitate surgical maneuvers under silicone oil or PFO that were previously challenging due to ongoing fluid leakage through nonvalved cannulas. With this reduced flow, valved cannulas afford a potential for decreased vitreous incarceration and fewer associated intraoperative iatrogenic retinal tears, as has been shown in postmortem rabbit eyes.<sup>1</sup>

### POTENTIAL DRAWBACKS AND PEARLS FOR VALVED CANNULA USE

Valved cannulas may not be completely without drawbacks. An obvious challenge is the more difficult insertion of soft-tip instruments. A perfectly coaxial insertion approach, augmented with visualization under a microscope, is typically sufficient and is the favored primary approach at Duke Eye Center. Alternatively, displacement of one of the silicone leaflets with a second instrument, such as fine-tipped forceps, can be performed. Instruments with shorter, and therefore more rigid, soft-tip extensions and retractable soft tips are also helpful for insertion. Some manufacturers have designed their valves on a removable cap that enables easy transitioning between a valved and traditional nonvalved cannula setup.

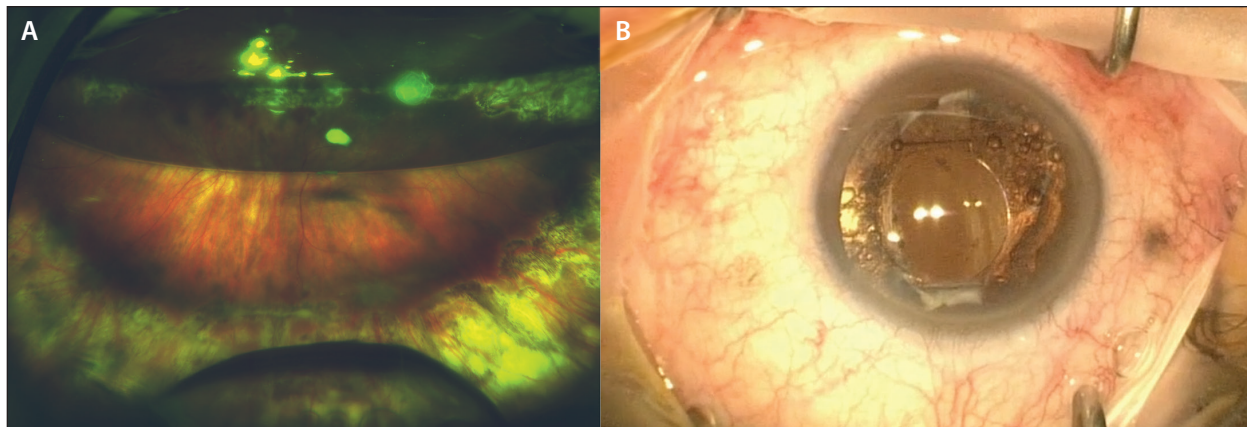
#### Video: The Game Changer for Vitreoretinal Surgery



Some less obvious disadvantages have become apparent in early experience with valved cannula vitrectomy. Occasional episodes of hypotony were paradoxically observed immediately at the start of some vitrectomy cases. We learned, that when valved cannulas are used, it is typically preferable to place all three cannulas first, followed by insertion of the infusion line. If the infusion line is placed in the first cannula before placement of the other two cannulas (as is typically performed for nonvalved cannula vitrectomy), increased IOP from insertion of each of the subsequent two cannulas can repeatedly push vitreous into the infusion line, resulting in a clogged infusion line with subsequent hypotony when cutting and aspiration is initiated. This usually does not occur with nonvalved cannulas because of ongoing flow through the open cannulas, which typically allows the infusion line to remain open.

Additionally, while valved cannulas offer the key advantage of a closed system, caution must be exercised when injecting additional volume into this closed system. Specifically, injection of PFO, silicone oil, or gas may require one of the cannulas to be open, either by inserting forceps or another instrument to open the valve, by placing a “chimney” vent, or by removing a valve. Alternatively, a dual-bore injection cannula may be helpful to allow passive egress of fluid during PFO injection. It is important that sufficient vitreous be removed to prevent blocking of the opened cannula or the dual-bore injection cannula, and perfusion at the optic nerve or tactile assessment of IOP should be continually monitored to prevent excessive IOP elevation.

Surprisingly, although many surgeons at Duke Eye Center predicted a decrease in PFO-related complications with valved cannulas, an unusual cluster of large amounts of postoperative retained intraocular PFO was noted during the transition to valved cannulas. In these cases, the amount of retained PFO in the vitreous and/or anterior chamber was much larger than the small droplets sometimes seen with nonvalved cannulas and was not sufficiently explained by previously known risk factors such as poor surgical view or decreased evaporation during fluid-air exchange (Figure 2).<sup>2</sup> One hypothesis posited that, when using valved cannulas, surgeons are able to fill PFO anterior to cannula insertion, whereas PFO leakage through nonvalved cannulas prevents sustained PFO fill beyond the height of the nonvalved cannula. In valved cannulas, PFO filled anteriorly can gain access to structures such as the anterior chamber, lens capsule, and ciliary sulcus—particularly in aphakic or pseudophakic patients—and be sequestered in these compartments during subsequent surgical maneuvers that torque the eye (eg, laser, additional vitreous base trimming, or fluid-air exchange).



**Figure 2.** Ultra-widefield image demonstrating a significant amount of PFO following retinal detachment repair (A). The large PFO bubble in the inferior vitreous cavity was noted as the C3F8 gas level seen in the superior vitreous cavity was resorbing. Intraoperative photo of a different patient demonstrating numerous small PFO bubbles sequestered within the open capsular bag (B). This patient also had a large bubble in the vitreous cavity. Both cases required vitreous and/or anterior chamber washout with flushing of the capsular bag to remove retained intraocular PFO.

Postoperatively, PFO then accumulates in the vitreous cavity when the gas resorbs. PFO can also float freely between the anterior chamber and vitreous cavity, depending on positioning, in eyes with aphakia or an open posterior capsule. Surgical PFO removal in these cases was often required due either to subjective visual significance of the large bubble or, less commonly, to a suspected inflammatory response.

### COMPLICATION RATES: VALVED VERSUS NONVALVED CANNULAS

In order to determine whether valved cannulas were responsible for any detectable complications compared with nonvalved cannulas, we performed a retrospective, single-institution comparative case series at Duke Eye Center. Investigating a cohort of 163 eyes with both complex and simple retinal detachments operated with either valved or nonvalved cannula vitrectomy, we found no measurable differences in complication rates such as postoperative day 1 hypertony or hypotony, inflammatory response, epiretinal membrane formation with need for secondary peeling, and subretinal or intraocular retained PFO.<sup>3</sup>

Given the retrospective nature of the study, it was difficult to directly compare the amounts of retained PFO between the study groups. However, there was a trend toward increased secondary surgical removal of the intraocular retained PFO in valved cannula cases (100% in valved cases vs. 33% in nonvalved cases,  $P = .08$ ), underscoring our subjective identification of larger quantities of retained PFO in some valved cannula eyes.


It may be that larger studies with more patients are

needed to show differences in this relatively uncommon complication, or that subsequent adjustments in our surgical technique, specifically caution against PFO overfill, have circumvented a statistically measurable increase in this complication.

### CONCLUSION

Minor adjustments in surgical approach may minimize complications potentially associated with the altered fluidics of valved cannulas. In particular, retina surgeons should be wary of high PFO fill to minimize the risk of intraocular retention that is likely associated with valved cannula use. Nonetheless, valved cannulas provide closed system fluidics with numerous associated advantages that, in our opinion, translate immediately into smoother and easier surgery. ■

*Paul Hahn, MD, PhD, is an assistant professor of ophthalmology at Duke University Eye Center in Durham, N.C. He disclosed that he is a consultant for Second Sight Medical Products. Dr. Hahn may be reached at paulhahn@gmail.com.*



*Patrick Oellers, MD, is a third-year ophthalmology resident at the Duke Eye Center in Durham, N.C. He has no relevant financial disclosures. Dr. Oellers may be reached at Patrick.Oellers@dm.duke.edu.*



1. Abulon D, Charles M. The impact of valved and non-valved cannula on intraoperative fluid dynamics and vitreous. Paper presented at: 14th Euretina Congress; September 11-14, 2014; London.
2. Oellers P, Schneider EW, Fekrat S, et al. Retained intraocular perfluoro-n-octane after valved cannula pars plana vitrectomy for retinal detachment. *Ophthalmic Surg Lasers Imaging Retina*. 2015;46(4):451-456.
3. Oellers P, Stinnett S, Mruthunjaya P, Hahn P. Small-gauge valved versus non-valved cannula pars plana vitrectomy for retinal detachment repair. *Retina*. In press.