

# Why Consider the Yellow 577 nm Wavelength?

BY GIOVANNI STAURENGHI, MD



There are numerous reasons to use a laser when we are treating retinal disorders, and there are numerous lasers from which to choose. Most of us have experience with the green 532 nm lasers. Long considered a “standard” in photocoagulation, the green 532 nm wavelength

has proven effective in treating a large variety of pathologies. Nevertheless, it has some limitations, which can be circumvented by the use of the yellow 577 nm wavelength.

The yellow 577 nm wavelength has been used in ophthalmology for more than 2 decades. When it was first introduced, it rapidly became a favorite among retina specialists. But as newer technologies became available, retina specialists began to ignore the yellow 577 nm lasers until just a few years ago when the Supra Scan 577 (Quantel Medical) was introduced, providing improved efficiency and the reliability of solid state technology.

In the literature, the yellow 577 nm wavelength has been described as a safe and versatile wavelength. It provides high penetration through cataracts, low intraocular light scattering, peak absorption of oxyhemoglobin, and negligible macular xanthophylls absorption (Figure 1).

## Diabetic Retinopathy

Laser panretinal photocoagulation is still the primary treatment to consider for proliferative diabetic retinopathy, which we know

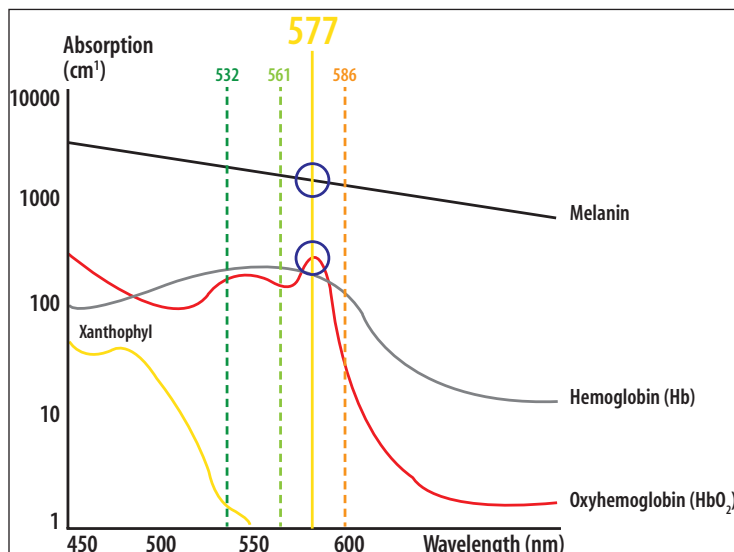


Figure 1. Yellow 577 nm wavelength absorption profile.

from the DRS<sup>1</sup> and ETDRS.<sup>2</sup> The 577 nm yellow laser has excellent absorption characteristics, which means we can perform panretinal photocoagulation with a lower energy level compared to the green light; this in turn results in a better tolerated treatment. Plus, yellow light has a much better transmission through ocular media opacities than other colors, meaning it is easier to use in patients with cataracts.

Long gone are the days where “classic macular grids” were the preferred methods when using macular laser applications; in today’s climate, we must consider subthreshold laser therapies like 577 nm MicroPulse.<sup>3</sup> This technology uses a series of shorter pulses rather than a short continuous laser delivery, allowing us to better preserve the retina by avoiding visible scarring either during or after treatment.

## Choroidal Neovascularization

### Focal Laser Treatment

When treating polypoidal lesions, different treatment options are possible, among them photodynamic therapy. The EVEREST study<sup>4</sup> showed photodynamic therapy was more effective than ranibizumab (Lucentis; Genentech) as the rate of polyp closure was higher.

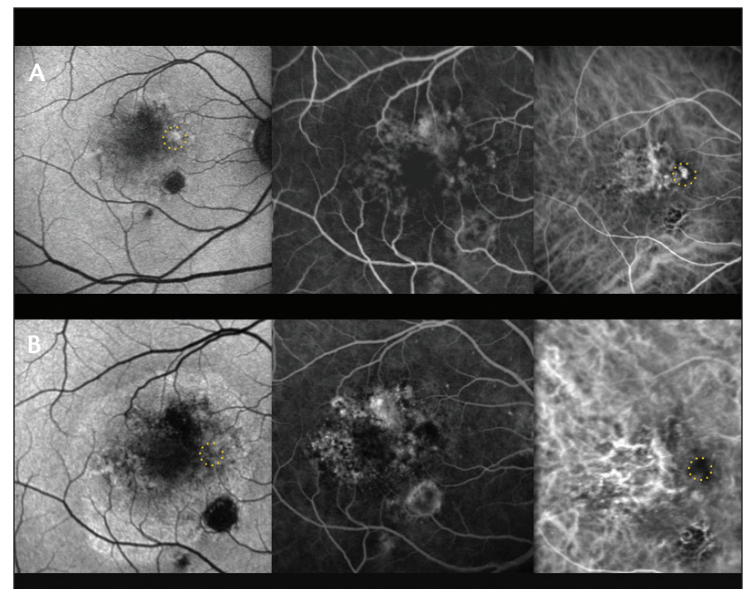


Figure 2. Polypoidal lesion before treatment (A) and one week after treatment (B) with 577 nm yellow laser. The yellow dotted line shows the area of treatment.

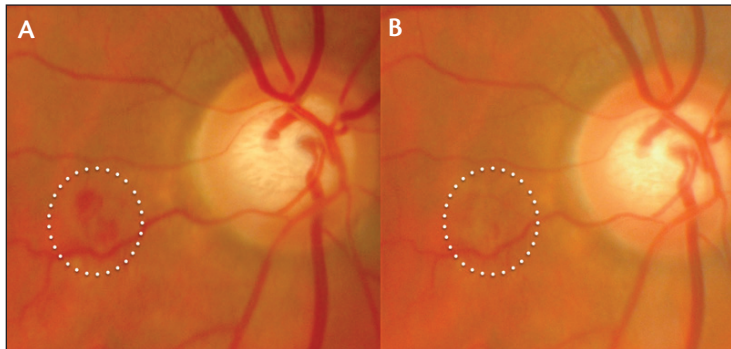


Figure 3. A polypoidal lesion before (A) and after treatment (B).

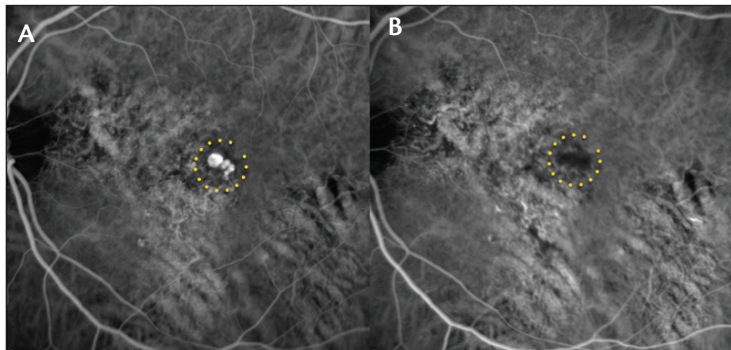


Figure 5. The yellow dotted lines indicate the bulging area before (A) and after (B) 577 nm yellow laser feeder vessel treatment.

However, when the bulging lesion is not located under the fovea, a gentle laser treatment, such as the 577 nm yellow laser, can also be applied directly.

Figure 2 shows a polypoidal lesion before and after treatment with 577 nm yellow laser. It is important to highlight the absence of retinal pigment epithelial (RPE) atrophy in the fundus autofluorescence image. Clinicians should take extra caution against destroying the retina while closing the polyps—and because the 577 nm yellow laser is extremely well absorbed by the oxyhemoglobin, it offers a significant advantage over other treatment modalities.

Figure 3 shows another case of a polypoidal lesion before and after treatment. The white dotted line delineates the area of treatment.

The left image in Figure 3 clearly shows some blood before treatment. In the image to the right, there is a light whitening of the retina.

### Feeder Vessel Laser Treatment

There will be cases where we cannot aim the laser close to the fovea. In these cases, indocyanine green angiography can identify the feeder vessels necessary to treat the polypoidal lesions.

Figure 4 shows before and after treatment with the disappearance of the feeder vessel. Figure 5 shows the bulge, outlined with the yellow dotted line, before and after 577 nm yellow laser feeder vessel treatment.

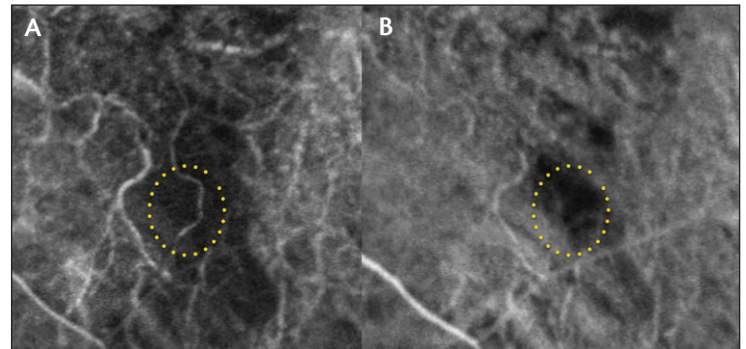


Figure 4. Before (A) and after treatment (B) with the disappearance of the feeder vessel.

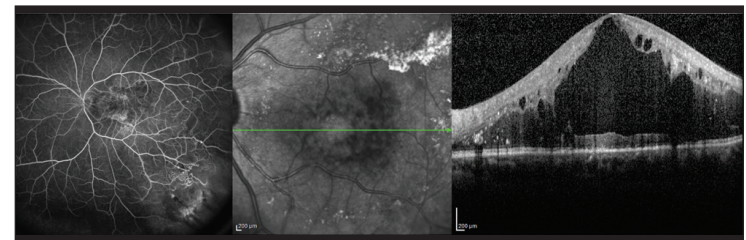


Figure 6. A patient who was 20/400 upon presentation.

### Retinal Microaneurysms

In cases of Coats disease—a diffuse microaneurysm—there are peripheral changes and significant edema and degeneration. Figure 6 tells the story of one case with a patient who was 20/400 upon presentation. He was treated with six injections of anti-VEGF and corticosteroids. The laser treatment targeted the microaneurysm, where the 577 nm yellow laser is very effective. The final image on the right of Figure 6 shows the initial optical coherence tomography image. Figure 7, however, shows the effect of the laser treatment in 22 months.

Figure 8 shows Coats disease in a young patient where focal laser was truly beneficial. In this case, we used the 577 nm focal laser successfully.

Yellow light ranges from 561 nm (yellow green) to 586 nm (yellow orange), but the maximum peak for oxyhemoglobin absorption is centered at 577 nm (pure yellow). There are several benefits of the 577 nm pure yellow wavelength over 532 nm, 561 nm, or 586 nm wavelengths. With the green, yellow-green, or yellow-orange lasers, the effect is secondary to the RPE absorption. We need to aim some of the energy at the RPE level for reflection. Using a 532 nm, 561 nm, or 586 nm laser too close to a microaneurysm means using the RPE as an absorption material (blanching). If a patient has significant edema, the clinician can use an injection to reduce the edema before targeting the microaneurysm with the laser. In that scenario, however, using more power to target the RPE will lead to RPE damage. The 577 nm yellow laser, however, is directly absorbed by the oxyhemoglobin so laser does not need to reach the RPE to coagulate the microaneurysm (Figure 9).

In my opinion, it is easier to focus on the microaneurysm when there is significant edema. When we can treat far from the RPE and

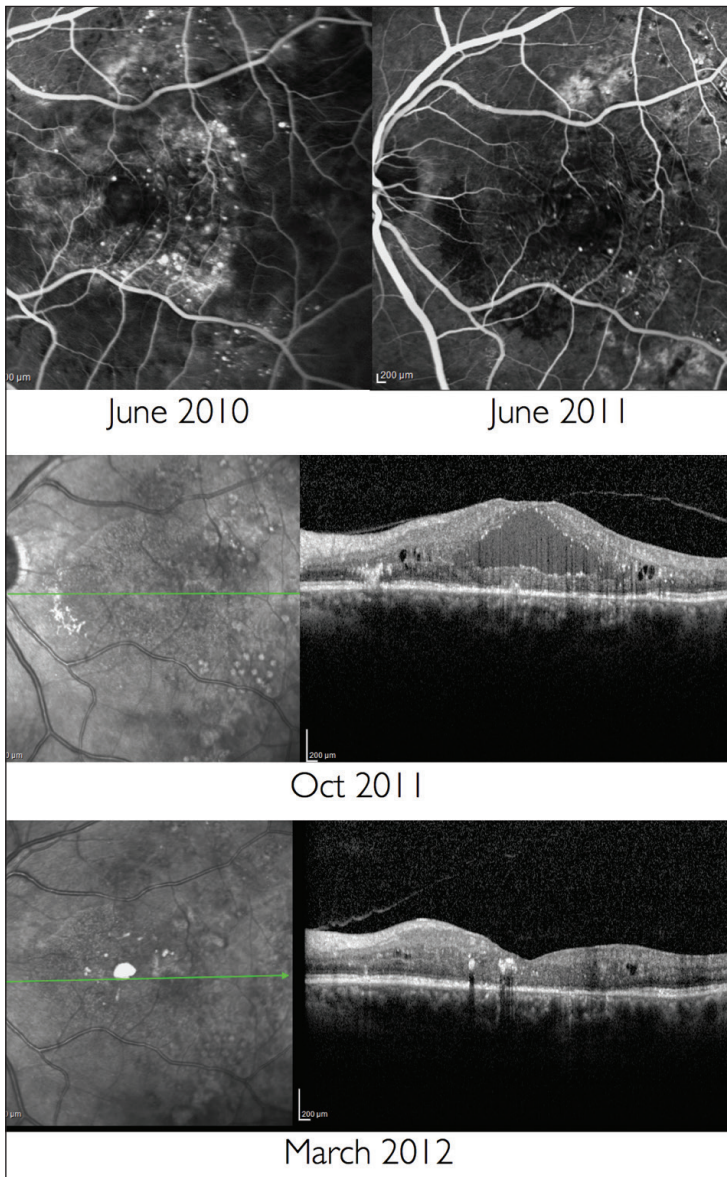


Figure 7. These images show the effects of 577 nm yellow laser treatment over the course of 22 months.

far from the photoreceptors, I believe the the 577 nm laser is a much safer option. It allows clinicians to target the area that needs treatment

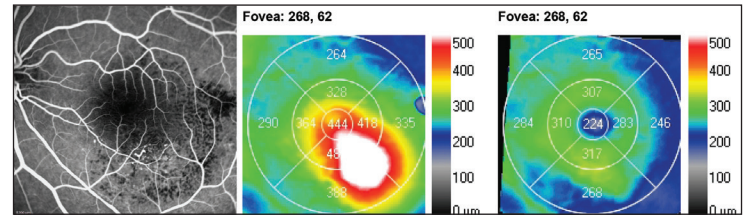


Figure 8. A younger patient where 577 nm focal laser was truly beneficial.

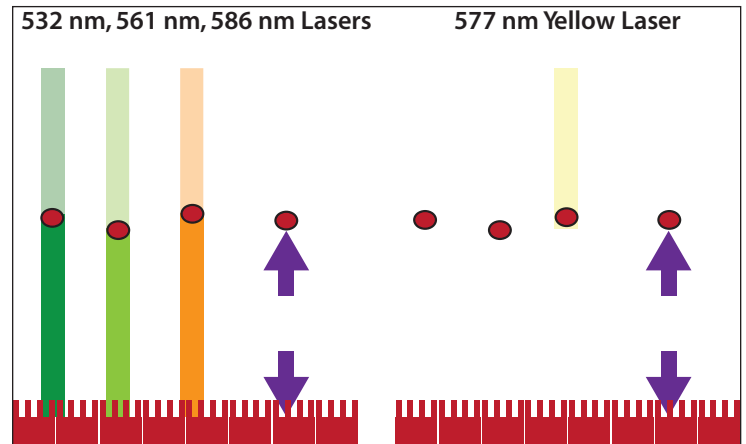


Figure 9. Yellow laser is absorbed by the oxyhemoglobin so the laser does not reach the RPE.

without causing retinal damage. So, if we use 532 nm laser, we should use an injection of anti-VEGF or corticosteroids first to reduce the edema. If we use the 577 nm laser, the laser should be used first, followed by drug injections if we want to speed up the fluid absorption. ■

*Giovanni Staurenghi, MD, is a professor of ophthalmology at the Eye Clinic in the Department of Biomedical and Clinical Sciences “Luigi Sacco” at Luigi Sacco Hospital, University of Milan, Italy. Dr. Staurenghi is a consultant for Quantel Medical. He may be reached at giovanni.staurenghi@unimi.it.*

1. Preliminary report on effects of photocoagulation therapy. The Diabetic Retinopathy Study research group. *Am J Ophthalmol.* 1976;81(4):383-396.
2. Photocoagulation for diabetic macular edema. Early Treatment Diabetic Retinopathy Study report number 1. Early Treatment Diabetic Retinopathy Study research group. *Arch Ophthalmol.* 1985;103(12):1796-1806.
3. Kwon YH, Lee DK, Kwon OW. The short-term efficacy of subthreshold Micropulse yellow (577-nm) laser photocoagulation for diabetic macular edema. *Korean J Ophthalmol.* 2014;28(5):379-385.
4. Koh A, Lee WK, Chen SJ, et al. EVEREST study: efficacy and safety of verteporfin photodynamic therapy in combination with ranibizumab or alone versus ranibizumab monotherapy in patients with symptomatic macular polypoidal choroidal vasculopathy. *Retina.* 2012;32(8):1453-1464.