

REMOVAL OF HYDROGEL SCLERAL BUCKLES

Surgery to remove these devices must involve caution due to risk of complications.

BY NIELS CRAMA, MD



Silicone scleral buckles had been used for years in the treatment of rhegmatogenous retinal detachment, when, in the mid-1980s, an alternative came on the market. This episcleral hydrogel (methylacrylate-2-hydroxyethylacrylate) buckle (Miragel, Mira) was promoted especially because of its soft and pliable characteristics and its ability to absorb and release antibiotics.

Reductions in scleral erosion and in buckle infections were advantages of this material over silicone buckles. However, many years after its introduction, it became evident that this hydrogel buckle undergoes progressive swelling, up to several times its original size. Use of this hydrogel buckle in the United States was discontinued when its US production facilities were closed in 1995, but distribution of the buckle in Europe continued for a few years longer. Clinical experience and continuing reports of swelling-related complications, however, eventually led to complete discontinuation of the use of this material worldwide.

Today, ophthalmologists in general, and retina surgeons in particular, still encounter patients who present with symptoms related to the swelling of hydrogel buckles. When the swelling becomes symptomatic, surgical removal is usually the only option to relieve symptoms. Unfortunately, removal is not without risks. It is important for surgeons to recognize the presenting symptoms and, when planning surgical removal, to be aware of the friable characteristics of this material and the associated risks of removing these hydrogel buckles.¹

SYMPTOMS AND PRESENTATION

Swelling of a hydrogel buckle usually does not become symptomatic earlier than 5 years after surgery, and it can occur even up to almost 25 years after initial placement. How many of these hydrogel buckles will eventually undergo symptomatic swelling is unknown, but it has been calculated that this will occur in at least 34% of the devices implanted.¹

Ocular pain or discomfort, ocular motility disturbance, scleral erosion, conjunctival erosion, cosmetic problems, and ptosis are among the most often reported signs and symptoms, but corneal astigmatism, tear film insufficiency,

and a diagnosis of “orbital tumor” are other possible presentation scenarios. When symptoms arise, they tend to be progressive because of the gradual nature of the swelling. Some symptoms may show a correlation with the orientation of the buckle; conjunctival erosion is more often related to a radially oriented buckle, and ocular motility disturbance is more common with a segmental buckle.

A significantly swollen hydrogel buckle has an almost translucent, gel-like appearance and is usually not difficult to recognize on examination. However, careful history taking, especially regarding previous retinal surgery, is important in making the correct diagnosis and forming a therapeutic plan. When there is a history of retinal detachment surgery between 1985 and 2000, the possibility of a hydrogel buckle should be considered (Figure).

SURGICAL TECHNIQUE

With degradation of the hydrogel buckle, the hydrogel material becomes friable. This is an important aspect when planning to remove a symptomatic swollen buckle because



AT A GLANCE

- Once heralded for its reductions in scleral erosions and buckle infections, the hydrogel buckle is no longer used because of its tendency to swell up to several times its size.
- Although rare, retina surgeons still encounter patients who present with symptoms related to the swelling of hydrogel buckles.
- Surgical removal is usually the only option to relieve symptoms and, irrespective of the material (silicone or hydrogel), is not without risks, such as intraoperative scleral perforation and retinal redetachment.

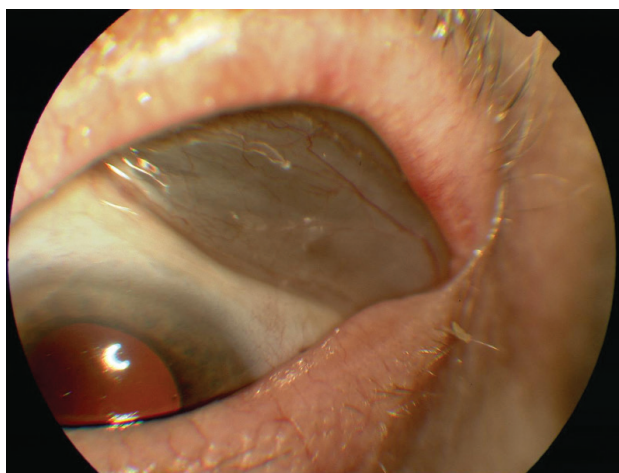


Figure. A swollen radially oriented hydrogel buckle with intact overlying conjunctiva. Note the size and translucent appearance caused by swelling of the material.

it cannot simply be extracted with a forceps. The degraded hydrogel falls apart when the surgeon tries to grasp it and, as a result, it comes out in small pieces. Complete removal is important because remaining material will continue to swell.

It is not uncommon to encounter scleral thinning, either mild or severe, so this should be inspected carefully and kept in mind during manipulation in surgery. Maximizing the visibility and exposure of the buckle by extensive opening of the overlying conjunctiva and the capsule surrounding the buckle is essential to minimizing this manipulation and reducing the risk for intraoperative scleral rupture. If there is an overlying silicone encircling band, this should be cut in order to untrap the hydrogel buckle and facilitate its removal.

Use of blunt, curved Wescott tenotomy scissors is efficient for this procedure. When closed, they form a blunt, gently curved instrument of just the right size, with the capability to reach the posterior sclera and gently manipulate the hydrogel anteriorly. When opened, the scissors can be used to cut tissue or sutures, reducing the need to change instruments.

Two techniques can be used to facilitate the removal of a hydrogel buckle. Boric acid can be used to dry out the buckle and facilitate removal. However this approach should be used with caution, especially in cases with extreme scleral thinning. Another technique to facilitate removal is extraction using cryo-application (Video), which is especially useful in radial-oriented buckles.^{2,3}

Besides the swelling and the friable condition, the hydrogel buckle sometimes also shows formation of local calcification on the sclera. These calcified plaques, which are extremely adherent to the sclera, can be left in place while the rest of the buckle is removed.

“ [I]rrespective of the material (silicone or hydrogel), removing a scleral buckle carries the risks of intraoperative scleral perforation and retinal redetachment.

RISKS OF SURGICAL REMOVAL

For most patients who are symptomatic, removal of the swollen hydrogel buckle is the only option for relief. However, irrespective of the material (silicone or hydrogel), removing a scleral buckle carries the risks of intraoperative scleral perforation and retinal redetachment.

The reported incidence of retinal redetachment and intraoperative scleral perforation when a symptomatic hydrogel buckle is removed varies among studies. In our own recent study of 467 consecutive eyes, a risk of 11% for retinal redetachment or intraoperative scleral perforation was seen, with loss of vision occurring in several of these cases.¹ This is a serious risk, but, as with all surgical indications, this has to be balanced against the severity of the patient's symptoms, status of the fellow eye, and other factors of influence.

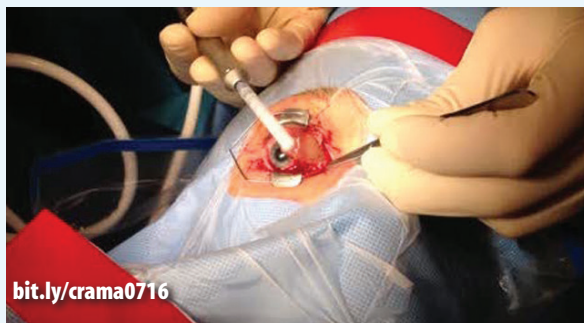Two factors that are independently correlated to an increased risk for scleral rupture are active periocular infection and a history of multiple sessions of retinal surgery.

Knowing that already more than 34% of hydrogel buckles are removed because of symptomatic swelling, there seems to be a fair chance that all hydrogel buckles that have ever



WATCH IT NOW

Dr. Crama removes a swollen hydrogel buckle using a cryoprobe.



bit.ly/crama0716

“ In our study ... there was no significant correlation between a longer duration of the hydrogel buckle and the risk for intraoperative scleral perforation.

been placed have already significantly degraded and will therefore be difficult to remove. An important question to be asked is, therefore, whether all hydrogel buckles should be prophylactically removed, given the risks of removal.

In our study, despite the fact that all patients who had an intraoperative scleral perforation also had a silicone encircling band, there was no significant correlation between a longer duration of the hydrogel buckle and the risk for intraoperative scleral perforation. It may therefore not be necessary to prophylactically remove all swollen hydrogel buckles. However, for symptomatic cases, removal by an experienced surgeon remains the only option for relief of symptoms. The patient's discomfort and desire for relief should be carefully balanced against the known associated risks. ■

1. Crama N, Klevering BJ. The removal of hydrogel explants: an analysis of 467 consecutive cases. *Ophthalmology*. 2016;123(1):32-38.

2. Le Rouic JF, Bejjani RA, Azan F, et al. Cryoextraction of episcleral Miragel buckle elements: a new technique to reduce fragmentation. *Ophthalmic Surg Lasers*. 2002;33(3):237-239.

3. Roldán-Pallarés M, Avila MI, Refojo MF. The use of boric acid solution to help in the removal of biodegraded Miragel episcleral buckles. *Retina*. 2005;25(1):90-93.

Section Editor Albert Augustin, MD

■ professor and chairman of the department of ophthalmology, Staedisches Klinikum Karlsruhe, in Karlsruhe, Germany

Section Editor Ehab N. El-Rayes, MD, PhD

■ professor of ophthalmology, Institute of Ophthalmology in Cairo, Egypt; vitreoretinal consultant, The Retina Clinic, in Cairo, Egypt

Section Editor, Masahito Ohji, MD

■ professor and chairman of the department of ophthalmology, Shiga University of Medical Science, in Otsu, Shiga, Japan

Section Editor, Stanislao Rizzo, MD

■ chair of the department of ophthalmology, University of Florence, in Florence, Italy

Niels Crama, MD

■ associate professor and vitreoretinal surgeon, Radboud University Nijmegen Medical Center, Nijmegen, the Netherlands
 ■ financial interest: none acknowledged
 ■ +31(0)24-36-14448; niels.crama@radboudumc.nl