

LASER THERAPY FOR DIABETIC RETINOPATHY AND DIABETIC MACULAR EDEMA

Laser still plays an important role in the treatment of diabetic eye disease, despite the popularity of anti-VEGF agents.

BY AMEEN MARASHI, MD



For decades, laser photocoagulation was the first-line therapy for both diabetic retinopathy (DR) and diabetic macular edema (DME). In recent years, intravitreal anti-VEGF injections have become popular as treatments for diabetic eye disease, and their safety and efficacy have been demonstrated in clinical trials.

Anti-VEGF injections have shown superiority over laser for several indications in diabetic eye disease, and they are easy to administer and provide rapid improvement in vision. All of this has caused many ophthalmologists to prefer anti-VEGF injections over laser, and as a result, laser has become a second-line therapy for these indications.

However, anti-VEGF agents are far from perfect. They are short-acting and expensive, and they carry the risks of endophthalmitis and stroke, which are not concerns with retinal laser photocoagulation. In addition, the Protocol T clinical trial of the Diabetic Retinopathy Clinical Research Network (DRCR.net) found that 50% of patients with DME required additional laser treatment after 24 weeks of anti-VEGF treatment.¹ Furthermore, the DRCR.net Protocol S trial found that intravitreal ranibizumab (Lucentis, Genentech) was noninferior to panretinal laser photocoagulation (PRP) in terms of visual acuity in eyes with proliferative diabetic retinopathy (PDR) in the absence of DME.²

It is clear, therefore, that laser can still play an important role in the treatment of diabetic eye disease. This article explores some of these roles and describes how laser can best be applied in these cases.

LASER AND DR

Laser photocoagulation is still first-line therapy in the management of PDR, as described in the ETDRS more than 25 years ago.³ However, following certain guidelines can pave the way to better outcomes.

When Should Laser Be Applied in PDR?

PRP can be employed in very severe nonproliferative diabetic retinopathy (NPDR) in the following situations:

- When the patient's contralateral eye had a bad outcome due to PDR without PRP or was treated with PRP only after the disease advanced to PDR; and
- In patients for whom follow-up may be difficult, especially pregnant women and patients with poor glycemic control or cataract.

In patients with PDR but no central DME, PRP is the mainstay treatment; however, in patients with PDR and non-central DME, focal laser may be used in addition to PRP (Figure 1). If the PDR is associated with center-involved DME, then intravitreal anti-VEGF therapy is recommended until both neovascularization and DME are resolved.



AT A GLANCE

- In eyes with vitreous hemorrhage as a complication of PDR, laser can help to prevent further vitreous hemorrhage and encourage its clearance.
- It is important to be very familiar with the laser machine and lenses you plan to use before applying laser treatment in PDR and DME.
- Laser has a place as both first- and second-line therapy for DME, but it should always be combined with good glycemic control (HbA1C of 7% or less).
- When laser treatment for DME is planned, it is recommended to use OCT maps or fluorescein angiography as a guide to ensure accurate laser placement.

Afterward, PRP can be applied if there is poor glycemic control, poor compliance, and/or the prospect of difficult follow-up.

In eyes with vitreous hemorrhage as a complication of PDR, laser can help to prevent further vitreous hemorrhage by halting the proliferation of fibrovascular tissue and the progression of tractional retinal detachment (TRD). Hence, laser application can be used as the main treatment for vitreous hemorrhage, rather than intravitreal anti-VEGF therapy. Protocol N of the DRCR.net showed that in eyes with PDR, there was no clinically significant advantage of ranibizumab over saline in the need for vitrectomy at 16 weeks; rates of vitrectomy were low in both groups.⁴ Anti-VEGF therapy may lead to rapid regression of neovascularization for a short time, although recurrence is common. An anti-VEGF drug can be used in the absence of TRD to speed up the clearance

“ In patients with PDR but no central DME, PRP is the mainstay treatment; however, in patients with PDR and non-central DME, focal laser may be used in addition to PRP.

of vitreous hemorrhage so that laser can be applied, but pars plana vitrectomy with endolaser is indicated in eyes with nonclearing vitreous hemorrhage or in the presence of vision-threatening TRD.

How is Laser Best Applied in PDR?

It is important to be very familiar with the laser machine and lenses you are about to use before applying laser treatment in PDR. There are four main types of laser wavelengths in commercially available ophthalmic lasers: 577, 532, 670, and 810 nm. There is also a vast array of wide-field lenses available, and there are two methods of application—using slit-lamp biomicroscopy or indirect ophthalmoscopy.

Yellow (577 nm) and green (532 nm) lasers are the most popular wavelengths for applying PRP, as they are more comfortable for both patient and physician. With these wavelengths, PRP should be applied with the least power necessary to induce retinal burns and with a large window of treatment. In contrast, infrared laser (810 nm), which can be painful to the patient, requires higher energy with a smaller window of treatment.

Applying laser using indirect ophthalmoscopy has the advantage of the ability to use scleral indentation to treat up to the ora serrata. On the other hand, slit-lamp biomicroscopy is easy to use, and there are many wide-field lenses that can be used to apply laser. The physician should take care regarding magnification and laser spot size; laser burns on the retina should be about 500 μ m in size.

Usually PRP requires 1,200 to 1,600 burns with single-spot lasers or 1,800 to 2,400 burns with multispot lasers, applied in one or more sessions. Treatment should be applied liberally in the temporal retina.

The best way to apply PRP without causing macular edema is to divide it into two sessions or more. I usually do PRP in two sessions 2 weeks apart. In cases of active

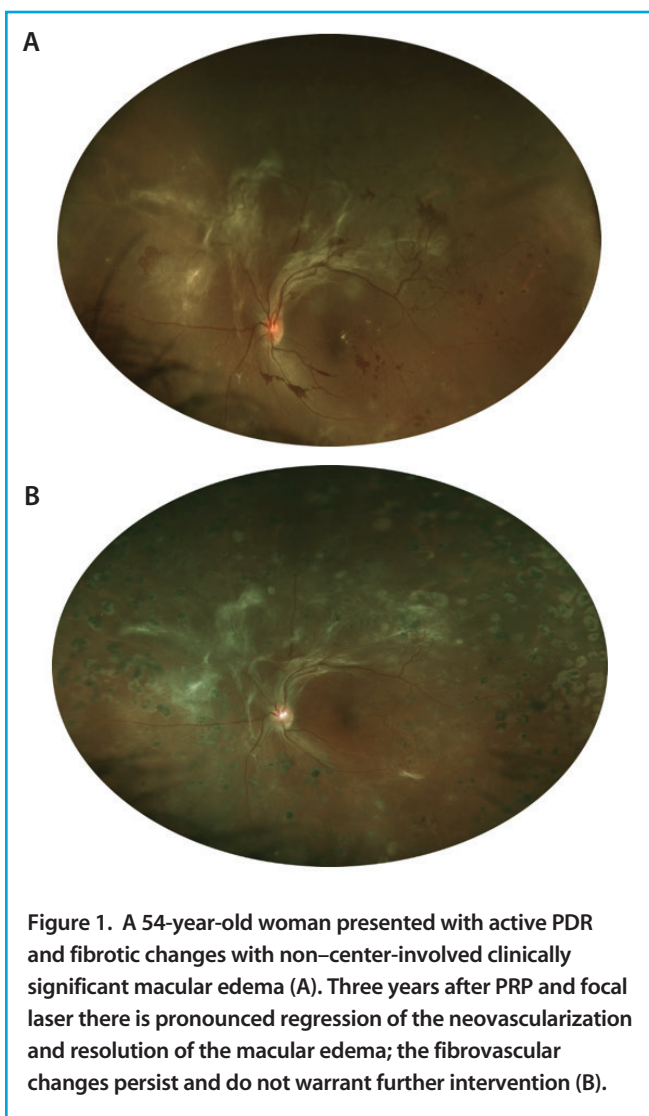


Figure 1. A 54-year-old woman presented with active PDR and fibrotic changes with non-center-involved clinically significant macular edema (A). Three years after PRP and focal laser there is pronounced regression of the neovascularization and resolution of the macular edema; the fibrovascular changes persist and do not warrant further intervention (B).

Images courtesy of EyeCareMD (<https://eyecaremd.com/>).

PDR in eyes previously treated with PRP, additional laser burns can be placed in nontreated areas or between existing burns.

LASER AND DME

Laser has become second-line therapy for center-involved DME, as it has been replaced by intravitreal injections of anti-VEGF and steroidal agents. Laser still has a role in the treatment of DME, but it should always be combined with good glycemic control (HbA1C of 7% or less). Laser needs 2 to 3 months to take effect, and its effect can last up to 18 weeks.

When Should Laser Be Applied in DME?

Laser treatment can be considered as first-line therapy for DME in the following situations:

- For non-center-involving clinically significant macular edema (CSME)⁵;
- For central DME in patients with good vision at baseline (20/25 or better) and good glycemic control (HbA1C 7% or less), using micropulse laser only, when central retinal thickness is 350 μm or less;
- For patients with recent (< 4 months) stroke or heart attack or with high cardiovascular risk;
- When intravitreal injections are contraindicated;
- For patients who decline intravitreal injections.

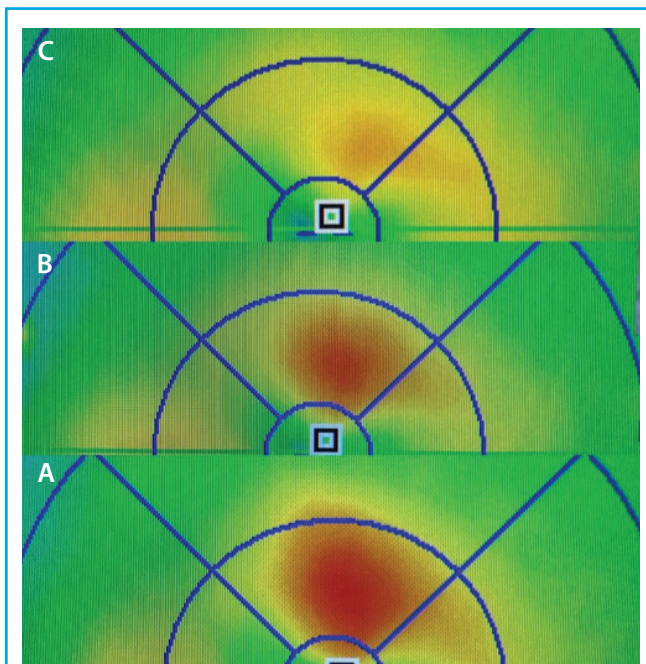


Figure 2. Recurrence of DME despite treatment with an intravitreal corticosteroid implant (A). Three months after micropulse laser application (B). Six months after micropulse laser application (C).

Images courtesy of Charles Mayron, MD, FACS, Capital Retina Associates, Latham, NY.

“ Laser still has a role in the treatment of DME, but it should be always combined with good glycemic control (HbA1C of 7% or less).

Laser treatment can be considered as second-line or adjuvant therapy to intravitreal anti-VEGF or steroid injections in the following situations:

- For DME not fully responding based on optical coherence tomography (OCT) after four to six injections of an intravitreal anti-VEGF agent or two to three injections of intravitreal steroids (Figure 2);
- As adjuvant therapy to intravitreal anti-VEGF or steroid agents whenever retinal thickness is less than 400 μm , to reduce the number of intravitreal injections and delay the interval of DME recurrence.

How is Laser Best Applied in DME?

As in PDR, knowing the laser machine is very important. Lasers operating at 577 nm wavelength can safely target leaking microaneurysms in eyes with thick edema. If a 532-nm laser is to be used, retinal thickness should be reduced to 400 μm or less before treatment.

A single-spot navigated laser system or a pattern scanning laser can be helpful in performing laser treatment for DME. When laser treatment for DME is planned, it is recommended to use OCT maps or fluorescein angiography as a guide to ensure accurate laser placement.

In general, there are two types of laser waves: continuous wave (CW) and subthreshold diode micropulse (SDM) laser. The former raises the temperature of retinal tissue, inducing thermal burns, whereas the latter chops the laser wave into *on* and *off* cycles, giving tissues time to cool and thus avoiding tissue damage. Instead, SDM laser causes photostimulation. Studies have shown that SDM laser is more effective than CW laser in reducing retinal thickness and improving DME,⁶ as SDM laser causes no chorioretinal damage and hence leads to better anatomic outcomes.⁷

When a CW laser is used, burns should be applied to leaking microaneurysms, causing gentle whitening under them, or in a modified grid of gentle burns spaced two burn

widths apart in the areas of edema. The foveal avascular zone should be spared by a margin of at least 500 μm .

SDM laser should be applied using a low-intensity but high-density protocol—that is, many laser applications (500 shots or more) covering the area of edema in a painting motion, but using only a 5% duty cycle (ie, 100 msec on power). When this modality is used, no visible tissue reaction is noted at the time of treatment, which needs 2 to 3 months to take effect. Retreatment can be considered in the event of treatment failure.

HOLDING STRONG

Laser is still the treatment of choice in patients with PDR and non-center-involving CSME. In central DME, laser can be used as an adjuvant treatment to reduce the need for intravitreal injections and to delay the need for retreatment. Use of SDM laser may be safer and more effective than conventional CW laser, with better visual outcomes. ■

1. Wells JA, Glassman AR, Ayala AR, et al; Diabetic Retinopathy Clinical Research Network. Aflibercept, bevacizumab, or ranibizumab for diabetic macular edema: two-year results from a comparative effectiveness randomized clinical trial. *Ophthalmology*. 2016;123:1351-1359.
2. Gross JG. DRCR.net Prompt PRP vs ranibizumab+deferred PRP for PDR study (Protocol S). Paper presented at: American Academy of Ophthalmology Annual Meeting; November 13, 2015; Las Vegas.
3. [No authors listed]. Early photocoagulation for diabetic retinopathy. ETDRS report number 9. Early Treatment Diabetic Retinopathy Study Research Group. *Ophthalmology*. 1991;98(5 Suppl):766-785.
4. Bhavsar AR, Torres K, Beck RW, et al. Randomized clinical trial evaluating intravitreal ranibizumab or saline for vitreous hemorrhage from proliferative diabetic retinopathy. *JAMA Ophthalmol*. 2013;131(3):283-293.
5. Scott IU, Danis RP, Bressler SB, et al; Diabetic Retinopathy Clinical Research Network. Effect of focal/grid photocoagulation on visual acuity and retinal thickening in eyes with non-center-involved diabetic macular edema. *Retina*. 2009;29:613-617.
6. Fazel F, Bagheri M, Golabchi K, Jahanbani Ardakani H. Comparison of subthreshold diode laser micropulse therapy versus conventional photocoagulation laser therapy as primary treatment of diabetic macular edema. *J Curr Ophthalmol*. 2016;28(4):206-211.
7. Luttrull JK, Musch DC, Mainster MA. Subthreshold diode micropulse photocoagulation for the treatment of clinically significant diabetic macular oedema. *Br J Ophthalmol*. 2005;89:74-80.

Section Editor Albert Augustin, MD

■ professor and chairman of the department of ophthalmology, Staetisches Klinikum Karlsruhe, in Karlsruhe, Germany

Section Editor Ehab N. El-Rayes, MD, PhD

■ professor of ophthalmology, Institute of Ophthalmology in Cairo, Egypt; vitreoretinal consultant, The Retina Clinic, in Cairo, Egypt

Section Editor, Masahito Ohji, MD

■ professor and chairman of the department of ophthalmology, Shiga University of Medical Science, in Otsu, Shiga, Japan

Section Editor, Stanislao Rizzo, MD

■ associate professor and chairman, department of ophthalmology, University of Florence, Azienda Ospedaliero Universitaria Careggi, Florence, Italy

Ameen Marashi, MD

■ retina specialist at the Marashi Eye Clinic in Aleppo, Syria
 ■ financial interest: none acknowledged
 ■ ameenmarashi@hotmail.com; www.amretina.tk