

Clinical Applications of Microscope-Integrated OCT

Recent advances have improved the utility of intraoperative visualization, with more innovation on the way.

By Bani Aguirre, MD, MPH; Anjali Saini, BS; Vahid Ownagh, MD; and Lejla Vajzovic, MD



The high resolution and noninvasive nature of OCT have established it as a cornerstone of retinal disease imaging. Recognizing the diagnostic value of this tool, surgeons have sought to incorporate it into surgical settings to enable real-time intraoperative feedback. Continuous investigation has led to the development of intraoperative

microscope-integrated OCT (MIOCT), designed to integrate the optical path of the spectral-domain OCT (SD-OCT) scanner into the surgical microscope, enabling real-time imaging of active vitreoretinal surgical maneuvers.¹⁻³ The feasibility and advantages of MIOCT in macular surgery were reported in a 3-year study, in which information from the device influenced surgical decisions in 29% of cases.⁴

Today, several commercially available systems offer MIOCT for vitreoretinal surgery, differing in the degree of OCT integration and 3D visualization capabilities. Three SD-MIOCT systems provide real-time cross-sectional B-scan imaging: the Zeiss Rescan 700, the Haag-Streit iOCT, and the Leica Proveo 8 with EnFocus, which offers SD-OCT with en face imaging. The Artevo 800 digital microscope (Carl Zeiss Meditec) and Ngenuity (Alcon) 3D visualization system advance this further by integrating SD-OCT with a stereoscopic 4K heads-up display on a single platform, enabling simultaneous real-time OCT imaging and 3D visualization of the surgical field. Notably, none of these systems currently support real-time volumetric quantification of intraocular structures.

However, in the research domain, next-generation

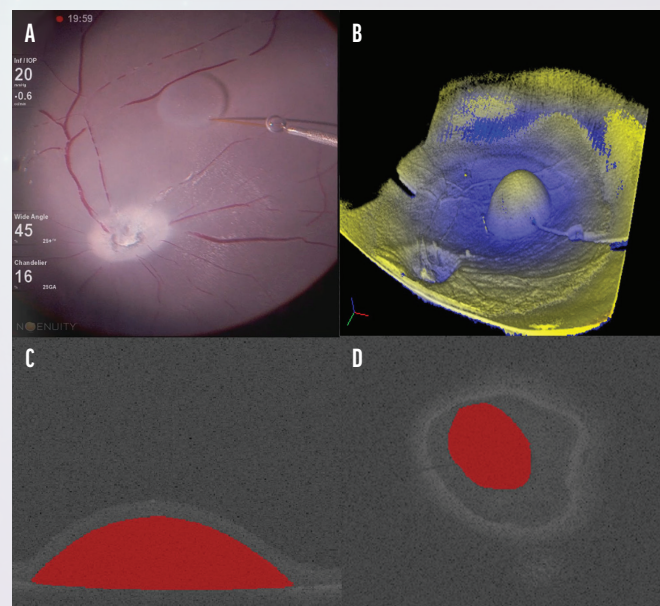


Figure 1. This is the microscope view with the Ngenuity (Alcon) 3D visualization system (A) with a 3D MIOCT volume reconstruction during bleb formation (B). The system provides segmentation of the MIOCT bleb B-scans (C) and a coronal view of the bleb (D).

models have introduced swept-source technology and 4D volumetric imaging.⁵ These enhancements allow dynamic visualization of residual membranes, foveal deformations, and subretinal fluid quantification, resulting in more precise real-time surgical adjustments.⁶⁻⁹

Furthermore, MIOCT has facilitated the integration of novel surgical approaches, including subretinal gene therapy delivery, where precise cannula placement and bleb formation are critical for therapeutic efficiency.¹⁰ Intraoperative OCT has also proven valuable in educational settings, providing retina fellows with immediate visual

Images courtesy of Robert Trout

feedback while they practice advanced surgical procedures.

The rapid evolution of MIOCT continues to redefine standards in vitreoretinal surgery, connecting diagnostic imaging with surgical execution to enhance safety and precision. In this article, we review the clinical applications and future directions of MIOCT to highlight its transformative role in retinal surgery, including real-time volume estimation and image fusion of color microscopy.

VOLUME ESTIMATION

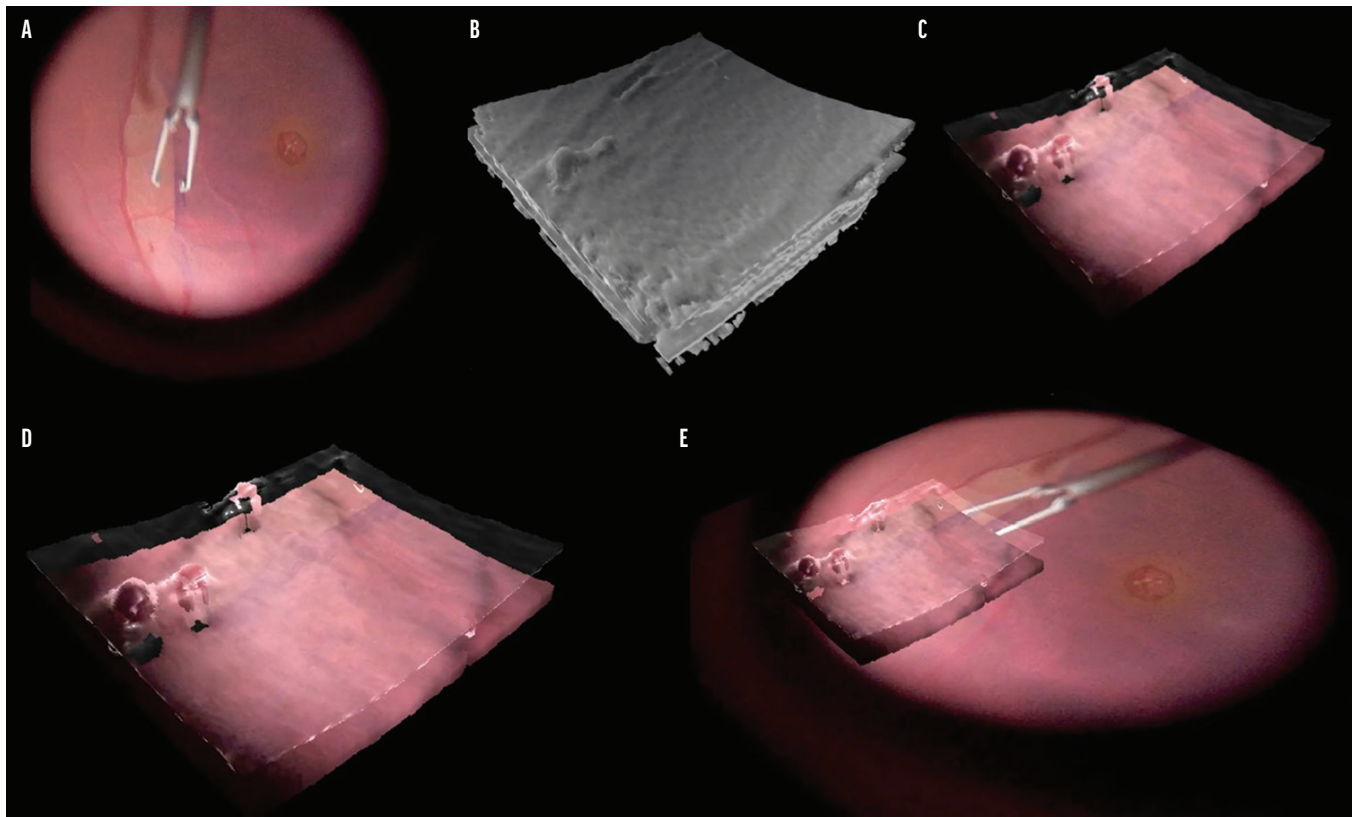
Swept-source MIOCT (SS-MIOCT), such as the investigational Duke MIOCT, has addressed key limitations of SD-MIOCT—most notably depth penetration and scanning speed—enabling the real-time, high-resolution volumetric imaging of subretinal blebs.¹¹ This system, which has been validated in phantom eyes and in vitro, allows for direct 4D visualization of subretinal blebs and suprachoroidal cannulas, and, through voxel dimension calibration, enables a quantitative assessment of segmented scans (Figure 1).^{12,13} Moreover, The Duke MIOCT is currently being used in human clinical trials for subretinal bleb visualization and volumetric quantification, providing real-time volumetric assessment of subretinal structures.

This advance has significantly deepened our

KEY TAKEAWAYS

- ▶ The evolution of intraoperative microscope-integrated OCT (MIOCT) connects diagnostic imaging with surgical execution to enhance safety and precision.
- ▶ In the research setting, swept-source MIOCT technology and 4D volumetric imaging allow dynamic visualization of residual membranes, subretinal fluid, and foveal deformations.
- ▶ In the future, transitioning from side-by-side displays to unified, single-channel visualization platforms will provide surgeons with enhanced depth perception and spatial orientation.

understanding of surgical precision in subretinal gene therapy. Hsu et al compared bleb volumes in porcine eyes measured with SS-MIOCT against the intended injection volume and the surgeon's estimated leakage. In eyes with minimal leakage, surgeons successfully delivered an average



Images courtesy of Robert Trout

Figure 2. The digital microscope view (A) has a corresponding volume render (B) that is integrated to generate a single fused visualization (C). The rendered image (D) is then fused with the 2D image in the periphery (E). Image adapted from Trout et al.¹⁷

of $32 \pm 12.5 \mu\text{L}$ of the intended $50 \mu\text{L}$. To confirm the system's precision, a validation study was conducted in model eyes using an object of known volume. This study demonstrated an accuracy of $1.0 \mu\text{L}$ (6% of the measured volume) with no statistically significant variation across different imaging settings.¹³

Following this work, Sastry et al sought to improve SS-MIOCT quantification by implementing a widefield viewing system capable of capturing larger or more peripheral blebs. Using a suprachoroidal subretinal cannula, the team created subretinal blebs in porcine eyes and demonstrated that 82.48% of the intended injection volume was accurately delivered in ex vivo experiments. Validation studies using ceramic spheres confirmed the accuracy of image-based volume measurements, showing precision to $\pm 0.029 \mu\text{L}$ for objects imaged over the posterior pole and $\pm 0.025 \mu\text{L}$ for those imaged over the peripheral retina.¹²

Recently, Valikodath et al conducted the first human study to implement MIOCT for volumetric bleb measurement. Using an investigational intraoperative MIOCT system with a modified widefield noncontact indirect viewing platform, the team quantified subretinal tissue plasminogen activator delivery in three patients with submacular hemorrhage. This proof-of-concept study revealed discrepancies of 9% to 64% between the intended and actual injection volumes, likely driven by variability in bleb morphology and leakage at the injection site.¹⁰

These studies have shown that MIOCT can enhance the safety, accuracy, and evaluation of subretinal drug delivery.¹⁰ In addition, these insights have motivated the development of next-generation devices that facilitate the more efficient delivery of therapeutic agents and reduce the steep learning curve for surgeons.¹⁴ Additionally, quantification techniques will allow us to understand the dynamics and technique modifications that lead to larger blebs and less leakage.¹⁵

IMAGE FUSION OF COLOR MICROSCOPY

The next transformative event for user-centered surgical visualization is the integration and perception of intraoperative visual information. By transitioning from traditional side-by-side displays to unified, single-channel visualization platforms, surgeons will benefit from enhanced depth perception and spatial orientation (Figure 2).

Our team used boundary-based shading to further refine 3D structural details and adapted virtual reality interfaces to better delineate critical retinal layers. In parallel, these adaptations offer a more immersive and flexible visualization for surgical navigation.¹⁶

As we continue to develop this technology and implement features such as retinal thickness maps, we will be able to study the tissue–tool interactions and surface features that lead to optimized surgical outcomes.¹⁷ ■

1. Tao YK, Ehlers JP, Toth CA, Izatt JA. Intraoperative spectral domain optical coherence tomography for vitreoretinal surgery. *Opt Lett*. 2010;35(20):3315-3317.
2. Ehlers JP, Tao YK, Farsiu S, Maldonado R, Izatt JA, Toth CA. Integration of a spectral domain optical coherence tomography system into a surgical microscope for intraoperative imaging. *Invest Ophthalmol Vis Sci*. 2011;52(6):3153-3159.
3. Hahn P, Migacz J, O'Connell R, Izatt JA, Toth CA. Unprocessed real-time imaging of vitreoretinal surgical maneuvers using a microscope-integrated spectral-domain optical coherence tomography system. *Graefes Arch Clin Exp Ophthalmol*. 2013;251(10):213-220.
4. Ehlers JP, Modi YS, Pecun PE, et al. The DISCOVER study 3-year results: feasibility and usefulness of microscope-integrated intraoperative OCT during ophthalmic surgery. *Ophthalmology*. 2018;125(7):1014-1027.
5. Shen L, Carrasco-Zevallos O, Keller B, et al. Novel microscope-integrated stereoscopic heads-up display for intrasurgical optical coherence tomography. *Biomed Opt Express*. 2016;7(5):1711-1726.
6. Ehlers JP, Griffith JF, Srivastava SK. Intraoperative optical coherence tomography during vitreoretinal surgery for dense vitreous hemorrhage in the pioneer study. *Retina*. 2015;35(12):2537-2542.
7. Jayadev C, Dabir S, Vinekar A, Shah U, Vaid T, Yadav NK. Microscope-integrated optical coherence tomography: A new surgical tool in vitreoretinal surgery. *Indian J Ophthalmol*. 2015;63(5):399-403.
8. Li JD, Viehland C, Dhalla A-H, et al. Visualization of surgical maneuvers using intraoperative real-time volumetric optical coherence tomography. *Biomedical Optics Express*. 2023;14(7):3798-3811.
9. Hesham G, Chen X, Mahmoud TH, et al. Visualization from microscope-integrated swept-source OCT in vitreoretinal surgery for diabetic tractional retinal detachment. *Invest Ophthalmol Vis Sci*. 2017;58(8):3777.
10. Valikodath NG, Li JD, Raynor W, Izatt JA, Toth CA, Vajzovic L. Intraoperative OCT-guided volumetric measurements of subretinal therapy delivery in humans. *J VitreoRet Dis*. 2024;8(5):587-592.
11. Li JD, Raynor W, Dhalla A-H, et al. Quantitative measurements of intraocular structures and microinjection bleb volumes using intraoperative optical coherence tomography. *Biomedical Optics Express*. 2023;14(1):352-366.
12. Sastry A, Li JD, Raynor W, et al. Microscope-integrated OCT-guided volumetric measurements of subretinal blebs created by a suprachoroidal approach. *Transl Vis Sci Technol*. 2021;10(7):24.
13. Hsu ST, Gabr H, Viehland C, et al. Volumetric measurement of subretinal blebs using microscope-integrated optical coherence tomography. *Transl Vis Sci Technol*. 2018;7(2):19.
14. Ownagh V, Antonio-Aguirre B, Hansen B, et al. Volumetric evaluation of novel single-step subretinal injection device using microscope-integrated optical coherence tomography. *Invest Ophthalmol Vis Sci*. 2025;66:269.
15. Ownagh V, Hansen B, McCall M, Stinnett SS, Toth CA, Vajzovic L. Vitrectomy technique modification alters intraocular pressure dynamics during subretinal bleb formation. *Invest Ophthalmol Vis Sci*. 2024;65:903.
16. Trout RM, Viehland C, Li JD, et al. Methods for real-time feature-guided image fusion of intrasurgical volumetric optical coherence tomography with digital microscopy. *Biomedical Optics Express*. 2023;14(7):3308-3326.
17. Tso-Ting Lai, Chiu SI, Tai V, et al. Objective measures of retinal thickness changes over time during macular surgery using microscope-integrated optical coherence tomography. *Invest Ophthalmol Vis Sci*. 2023;64(8):2492.

BANI AGUIRRE, MD, MPH

- Ophthalmology Resident, New York Medical College - Westchester Medical Center, Valhalla, New York
- Financial disclosure: Awardee (Vitreoretinal Disease Foundation Award to research MIOCT)

ANJALI SAINI, BS

- Medical Student, Case Western School of Medicine, Cleveland
- Financial disclosure: None

VAHID OWNAGH, MD

- Vitreoretinal Surgery Fellow, Baylor College of Medicine, Houston
- Financial disclosure: Awardee (Vitreoretinal Disease Foundation Award to research MIOCT)

LEJLA VAJZOVIC, MD

- Director, Duke Surgical Vitreoretinal Fellowship Program, Duke University Eye Center, Durham, North Carolina
- Professor of Ophthalmology with Tenure, Adult and Pediatric Vitreoretinal Surgery and Diseases, Duke University Eye Center, Durham, North Carolina
- Associate Medical Editor, *Retina Today*
- lejla.vajzovic@duke.edu
- Financial disclosure: Consultant (Abbvie, Alcon, Alimera Sciences, Apellis, Astellas, Bausch + Lomb, Beaver-Visitec International, BMC, Clearside Biomedical, Coherus Biosciences, DORC, Genentech/Roche, Guidepoint, Gyroscope, Janssen, Novartis, Ocugen, Ocular Therapeutix, Oculus Surgical, OcuTerra, Outlook Therapeutics, Regenxbio); Honoraria (Evolve Medical Education, Vindico Medical Education); Investigator (AGTC, Alcon, Aldeyra, Genentech/Roche, Heidelberg, NEI, Novartis, Ocular Therapeutix, Regenxbio); Research Grants (Gyroscope, Heidelberg)