

Revisiting Chemical Peels for Facial Resurfacing

Despite availability of several new procedures for resurfacing, chemical peels remain a cost-effective option to improve skin texture and tone.

By Evan H. Schlam, MD

While various new procedures are available today for facial resurfacing, properly performed chemical peels remain a cost efficient and effective treatment modality. Chemical peeling agents are classified as superficial, medium, and deep based on the approximate depth of wound created when they are applied to the skin. Overall, the most versatile of these agents is trichloroacetic acid (TCA), available at several different percentages to achieve various desired depths of cell injury.

The damage from superficial peels tends to be confined to the epidermis and superficial layers of the papillary dermis. Medium depth peels extend through the papillary dermis and into the upper layers of the reticular dermis, while deep peels penetrate to the mid-reticular dermis. The ideal patient for a chemical peel is one whose desired response is confined to the skin texture. This is in contrast to those patients who desire volume expansion or muscle relaxation, which would necessitate the addition of fillers, Botox, or cosmetic surgery for the desired effect.

Superficial Peels

Superficial peeling agents include 70% glycolic acid, 10-20% trichloroacetic acid, and Jessner's solution. These peels are ideal for those patients with dyschromia, acne, and post-inflammatory pigment alterations. As opposed to the depth of penetration of glycolic acid, which is dependant on the time of application and requires neutralization with water or sodium bicarbonate solution, TCA is self-neutralized by the natural protein concentration of the skin. Therefore, with TCA, the penetration is related to the number of application coats, rather than the exposure time.

One can safely obtain efficacious results in a patient with 10-25% TCA. Jessner's solution (also referred to as Combes Solution) is another agent that can be effective for superficial peels. It consists of 14 grams of resorcinol and 14 grams of salicylic acid, mixed with 85% lactic acid combined with 100ml of 95% ethanol. Application of this superficial peeling agent is similar to that for TCA with the presence of blotchy frosting at the endpoint.

Medium Depth Peels

Medium depth peels can be achieved with higher concentrations of TCA (35-40%) alone or in combination with Jessners solution or 70% glycolic acid solution. Concentrations of TCA beyond 35% are not generally recommended as a single solution because results can be unpredictable, and there are increased risks

of scarring and other complications. The combination of TCA with Jessners solution or glycolic acid serves to uniformly weaken the epidermal barrier, thus permitting a stable, controlled result. This serves as a more effective alternative to high concentrations of TCA when attempting to achieve a medium depth peel.

Due to the extent of penetration of medium depth peels into the papillary and upper reticular dermis, collagen remodeling may occur for up to several months after the peel. These peels may be effective for the treatment of pigment irregularities and rhytides and for photodamage, such as actinic keratoses. While superficial peels generally require frequent repetition, medium depth peels can frequently achieve the same results after only a couple of treatments. However, longer patient recovery time is often a drawback.

Deep Peels

Deep chemical peeling agents contain a large concentration of Phenol. The most commonly used is Baker's phenol formula, composed of 3ml of 88% phenol, 3ml of croton oil, 8ml of Septisol liquid soap, and 2ml of distilled water. While this mixture dilutes the phenol concentration to about 50%, it permits a deeper penetration than pure phenol. This type of peel is usually reserved for those patients with heavy wrinkles and severe photodamage. However, these peels are the least commonly performed due to the potential for complications including cardiac arrhythmias as well as renal and hepatic dysfunctions. In addition, patient recovery time can be quite extensive. In contrast to superficial and medium depth peels, deep chemical peels are quite time consuming for the physician as well as the patient, since they require a significant post-operative period. In addition, IV hydration and conscious sedative anesthesia are usually necessary. Constant cardiac monitoring is mandatory during these peels due to the potential toxicity that can result from percutaneous phenol absorption. For these reasons, dermatologic surgeons usually prefer superficial and medium depth peels to phenol peels.

Technique

Topical pre-treatment regimen adherence by the patient is instrumental to attain optimal results. A pre-treatment regimen consisting of tretinoin and hydroquinone is thought to increase the degree of penetration of the peeling agents and to help promote re-epithelialization. The depth of the peel is increased by the diminishing effect of tretinoin on the thickness of the stratum corneum. Aside from treating dyschromia, hydroquinone has also been proposed to block the development of new pigment production in the epidermis during the healing phase.

At the time of treatment, thorough cleansing of the skin surface is very important prior to application of the peeling agent. Acetone is an effective and inexpensive pre-peel cleansing agent. Applied to skin, acetone removes the natural oils and fats. This step is crucial— without pre-treatment cleansing, facial oils will impede penetration of the peeling agent, causing an uneven peel and thus a sub-optimal result.

Prior to application of the peeling agent, it is also important to protect the patient's eyes. This can be accomplished with gauze pads or a thin layer of antibiotic ointment, which will serve as a barrier. Proper positioning of the patient is also necessary. The patient's head should be positioned at approximately a 30-degree angle, this will allow the flow of gravity to help prevent the agent from running into the patient's eyes.

Once the area has been cleaned, the desired peeling agent can be applied with a cotton tip applicator or gauze pad. The cotton tip applicator is very

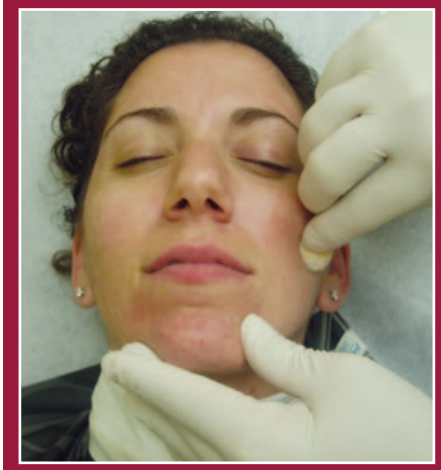

Application of TCA 25% following Jessner's solution.



Frosting begins in a patient after the treatment of Jessner's Solution plus 30% TCA.



A water soaked gauze wrap is placed on the patient in addition to a cooling fan to soothe any temporary discomfort.

Table I. Types of Peels and Depth of Injury

Superficial Depth	*Medium Depth*	*Deep*
• *70% glycolic acid* • *Jessner's solution -* •*TCA 20-30%*	• *35-40% TCA* • *Jessners + 35% TCA* • *70% glycolic acid + 35% TCA*	• *50% or greater TCA* • *Baker's Phenol (Baker-Gordon)*
Depth of injury: *Epidermis and Supeficial Papillary Dermis (0.06 mm)*	*Depth of injury:* *Through the papillary dermis, upper layers of reticular dermis (0.45 mm)*	*Depth of injury:* *Mid-reticular dermis (0.6 mm)*

useful, as it allows for an even, controlled distribution of the peeling agent. A large applicator can be used for the face, while a smaller tip applicator is most useful for delicate areas such as the eyelids and upper lips. If the applicator becomes too saturated, gently squeeze the tip to remove any excess agent. This prevents the uncontrolled splashing of product that can occur if the tip is drowned in the solution.

When performing chemical peels, the agent should be applied uniformly to one region at a time. It is best to start with the forehead, then move to the cheek and the rest of the face in systematic fashion. It is also important to manually stretch out rhytides and areas of redundant skin to allow for uniform penetration. When using glycolic acid, allow the solution to remain on the skin for a period of one to five minutes depending on the desired depth. The exposure time is directly related to the desired depth of penetration. An initial exposure time of one to two minutes is often sufficient for mild hyperpigmentation and facial acne, while longer exposure times (three to five minutes) are necessary for more severe acne scars and photodamage. As opposed to a TCA peel, frosting is not seen with glycolic peels. However, the patient may experience erythema as the agent penetrates the epidermis.

Once the desired application time has been reached, the glycolic acid must be neutralized. This can be done with water or a 5% sodium bicarbonate solution. The patient can then rinse their skin with cold water. It is common for patients to experience a slight burning sensation while rinsing their face.

TCA follows the same basic application techniques as glycolic acid. However, in contrast to glycolic acid, TCA results in a white frost usually within two minutes of application. This results from the coagulation of keratin and is indicative of completion of the TCA reaction. The patient should have an even frost encompassing the desired treated area upon completion of the TCA peel. The patient should be evaluated after about four minutes for an even white frost. If a uniform frost is not present at this time, additional TCA may be applied sparingly to the necessary areas.

It is not uncommon for the patient to experience burning with TCA application, however, burning usually subsides as the frosting develops. At the completion of treatment, application of water soaked gauze or a cooling fan can make the patient more comfortable. Unlike glycolic acid, TCA is self-neutralized, the cooling process is therefore performed to alleviate any temporary patient discomfort.

Post-operative discomfort and erythema may occur for a few days after the peel. Generally a mild wash and emollient applied over the face three times daily for the first four days is sufficient to induce gentle debriment. The addition of a topical corticosteroid cream may also help alleviate any burning, discomfort, or erythema. When irritation is present and until complete reepitheliazation occurs, avoid topical retinoids. Reepitheliazation should occur within two weeks. Another option during the postoperative period is the use of the newer growth factor creams. These also may decrease the recovery time by promoting wound healing.

Paients who undergo superficial peels such as glycolic acid or 20-25% TCA will often benefit from a series. The frequency should be based on the desired depth of reaction along with the patient's individual tolerance level. When additional treatments are performed before complete re-epitheliazation occurs, there is a deeper penetration and therefore an effect of greater magnitude. However, even when superficial to medium depth peels are performed at these higher frequencies, patient morbidity is still significantly lower than with deeper peels performed with higher concentrations of TCA or Phenol. A series of three or four of these superficial peels at weekly to biweekly intervals will often yield an optimal result.

Contraindications/ Complications

Chemical peels should be avoided in certain situations. Peels should not be performed on patients who have been on isotretinoin in the previous six months. Chemical peels are also contraindicated in those patients who have active infections including abscesses, inflammatory acne lesions, and recent facial HSV outbreaks. Antiviral prophylaxis should be strongly considered in those patients with a history of HSV outbreaks. Caution should also be exercised in the treatment of patients with inflammatory dermatologic conditions, such as rosacea, sebopsoriasis, or vitiligo. Patients with

Table 2. Highlights of Procedure

- *Clean the face thoroughly with acetone prior to treatment.*
- *Keep table at a 30-degree angle.*
- *Protect the eyes.*
- *Apply the agent uniformly.*
- *Manually stretch areas of redundant skin.*

Table 3: Possible Complications Secondary to TCA peel

- *Pigment alteration*
- *Prolonged erythema*
- *Acne*
- *Colloid milia*
- *Infection*

these conditions may be at an increased risk for postoperative complications including excess irritation and delayed wound healing. Patients who are exposed to prolonged ultraviolet exposure or radiation as well as those with Fitzpatrick type V and VI skin should also be approached with hesitancy.

Chemical peels can be detrimental and should be avoided in certain patients. These patients are those with a history of noncompliance, who are unlikely to adhere to photoprotection. The patient must exercise strict photoprotection regimens for several months postoperatively. During this time the patient is extremely susceptible to pigment alteration and scarring. Patients who are unable to commit to this level of photoprotection are not good candidates for peels. In addition, those patients who are particularly prone to photodamage tend to be those with existing dyschromia, those on estrogen or progestone supplements, and those patients with darker complexions (Fitzpatrick type III or IV). In these situations, undertake chemical peels on patients only with the most extreme caution.

Complications may occur secondary to superficial and medium depth chemical peels. The most common of these side effects are pigmentary alteration, prolonged erythema, cystic acne, colloid milia, bacterial infection, and reactivation of latent facial herpes virus. Pigmentary alterations are often in the form of hyperpigmentation with those peels that reach superficial and medium depths. This differs from the hypopigmentation that more commonly results from deeper chemical peels, such as those performed with phenol. This hyperpigmentation may be effectively treated with a hydroquinone, tretinoin, and a topical steroid cream in combination. Persistent erythema often responds to a low potency corticosteroid cream two to three time daily.

Cystic acne and colloid milia that result from chemical peels may be treated with simple extraction techniques. If the acne is persistant a short course of oral antibiotics such as doxycyline may be indicated to help alleviate the inflammation. While bacterial infections are very rarely a complication of chemical peels (especially superficial and medium depth peels), one must always entertain the possibility when clinically relevant. Oral antibiotics must be immediately administered to the patient if bacterial infection is suspected. There are few case reports of toxic shock syndrome occurring after phenol peels. For these reasons, patients should be followed closely postoperatively.

Viable and Cost-Effective

While the recent advance of laser technology has caused a large shift in the types of resurfacing procedures performed, chemical peels remain a viable and cost-effective option. Results from chemical peels are often remarkable. In addition, the lack of complexity and low cost of this relatively simple procedure allow physicians to perform it with frequency. As with any cosmetic procedure, patient expectations will dictate the level of satisfaction. It is very important to keep this in mind when consulting with the patient. The patient should not be led to believe that a peel will bring them an immediate resolution of dyschromia or ice pick acne scars. Nor should they be under the impression that chemical peels are a substitute for fillers or Botox therapy, since chemical peels do not have an effect on volume expansion or muscle relaxation. Rather, the patient should be made aware that the chemical peel is one procedure in the armamentarium for facial rejuvenation.

While chemical peels performed alone are often quite effective, many patients could benefit from a combination approach including the use of laser therapy, fillers, and Botox therapy. However, when performed appropriately on the proper patient, chemical peels remain a practical treatment for patients and yield a high degree of patient satisfaction.

1. Monheit GD. Skin preparation: an essential step before chemical peeling or laser resurfacing. Cosmet Dermatol. 1996;9:13-4.

2. Glogau RG, Matarasso SL. Chemical Peels: Trichloroacetic acid and phenol. Dermatol Clin 1995;13:263-275

3. Kligman AM, Grove GL, Hirose R, Leydon JJ. Topical Tretinoin for photaged skin. J Am Acad Dermatol. 1986;15:836-59.

4. Brody HJ. Variations and comparisons in medium depth chemical peeling. J Dermatol Surg Oncol. 1989;15:953-963.

5. Roenigk RK, Brodland DG. A primer of facial chemical peel. Dermatol Clin. 1993; 11:349-359.

6. Monheit GD. Chemical peeling for pigmentary dyschromias. Cosmet Dermatol. 1995;8:10-5.

7. Monheit GD. The Jessner's + TCA peel: A medium-depth chemical peel. J Dermatol Surg Oncol 1989;15:945-950.

8. Coleman WP III, Futrell JM. The glycolic acid trichloroacetic acid peel. J Dermatol Surg Oncol 1994; 20:76-80.

9. Perkins SW, Sklarew EC. Prevention of facial herpetic infections after chemical peels and dermabrasion: new treatment strategies in the prophylaxis of patients undergoing procedures of the perioral area. Plast Reconstr Surg. 1996;98:427-35.

10. Hevia O, Nemeth AJ, Taylor JR: Tretinoin accelerates healing after trichloracetic acid chemical peel. Arch Dermatol 127:678-682, 1991.

11. Brody HJ. Trichloacetic acid application in chemical peeling, operative techniques. Plast Reconstr Surg. 1995;2:127-8.

12. Resnik SS, Resnik BI. Complications of chemical peeling. Dermatol Clin 1995;13:309-312

13. Brody HJ. Complications of chemical peeling. J Dermatol Surg Oncol. 1989;15:1010-1011.

14. LoVerme WE, Drapkin MS, Courtiss EH, et al: Toxic shock syndrome after chemical face peel. Plast Reconstr Surg. 1987;80:115-118.