PD0210CosmeticsChallengeCol 2/9/10 4:44 PM Page 30

A Practical Primer for Dysport Part 4: The Icing on the Cake—More Strategies for Success with Integrative Rejuvenation of the Upper Face

Advanced techniques and an appreciation of the nuances of our newest neurotoxin allow creative clinicians to achieve success and satisfaction when rejuvenating the upper face.

By Hema Sundaram, MD

Skillful use of botulinum neurotoxin A (BoNT-A) gives us the opportunity to actually reshape the aging face via an integrative approach that goes beyond simple targeting of individual muscles. The results are immensely satisfying to patients and clinicians alike. An integrative approach requires consideration of facial anatomy, muscular activity across all facial zones, and the interactions between specific muscles of facial expression. Each patient's unique pattern of aging must also be taken into account; this is influenced by heredity, Fitzpatrick skin type, and by factors that promote extrinsic aging such as ultraviolet light exposure and smoking. BoNT-A is vital to rejuvenation of the upper face, since the development of rhytides due to hyperdynamic musculature features prominently in the aging process here.

We currently have the option of two FDA-approved BoNT-A products for aesthetic use: Dysport (abobotulinumtoxin A, Medicis) and Botox Cosmetic (onabotulinumtoxin A, Allergan). Clinical studies show that both products are essentially the same in terms of their efficacy, safety and tolerability, which are all excellent. Either Dysport or Botox Cosmetic may be selected for integrative facial rejuvenation, just as the two products are equally suitable for targeting of specific facial muscles. In my last article, I presented four strategies that I find useful when applying an integrative approach to treatment of the upper face with Dysport.[1] In this article, I will discuss four more strategies that may be of help. The first three pertain to specific characteristics of Dysport-onset of effect, field of effect and longevity. However, it is important to note that both Dysport and Botox Cosmetic may be considered gold standard therapies, and that both give excellent results when employed appropriately for facial rejuvenation.

Strategy 5: Take Advantage of Quicker Onset

Based on patient diaries kept during US clinical studies, the onset of clinical effects after Dysport injection is relatively rapid: The median time to onset is three days, with some study subjects reporting onset as soon as within 24 hours.[2] (Figs. 1 and 3) There may be both practical and psychological benefits to this rapid onset. Patients like quick gratification, and they also tend to feel more comfortable psychologically when the time lag between treatment and results is minimized.[3] Psychological comfort, in turn, facilitates the development of trust and rapport between patient and clinician.

As a fast-acting neurotoxin, Dysport can be combined with dermal fillers selected and injected with the appropriate technique to decrease or eliminate tis-

PD0210CosmeticsChallengeCol 2/9/10 4:44 PM Page 31



In Repose Before Dysport



In Repose After Dysport



Frowning Before Dysport

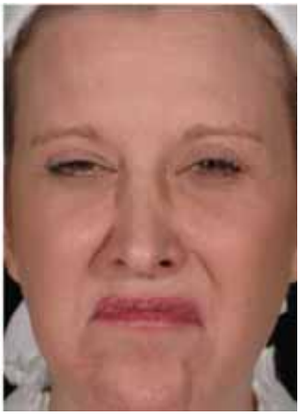

Frowning 42 Days After Dysport

Fig. 1. 47-year-old woman in repose before and on animation (frowning) 42 days after Dysport. Patient reported onset of clinical effects within 48 hours of Dysport injection. Treatment objectives for the upper face, with primary target muscles in parentheses, were to improve lines on the glabella (Procerus and Corrugators), and forehead (Frontalis), to improve transverse nasal lines (Nasalis) and crow's feet (Orbicularis oculi), to shape the eyebrows (Orbicularis oculi, Corrugators, Procerus, Frontalis), and to open the eyes (Orbicularis oculi). Note: This patient was also injected during the same session with Dysport to the lower face (Depressor anguli oris and Mentalis), a hyaluronic acid filler (Prevelle Silk, Mentor Corp.) to the lower eyelids, midface and lower face, and a collagen filler (Evolence, Ortho Dermatologics) to the lower face. These Injection strategies will be discussed in subsequent articles.

sue ecchymosis and edema. This provides an ideal rejuvenation protocol for patients who seek quick results with little or no down time-for example, those who receive treatment during the second half of the work week with the aim of looking better in time for a weekend event. A non-ablative chemical peel, laser or light-based energy device can be added to improve skin texture and tone. These short-notice, multi-modality treatment paradigms will be discussed in later articles.

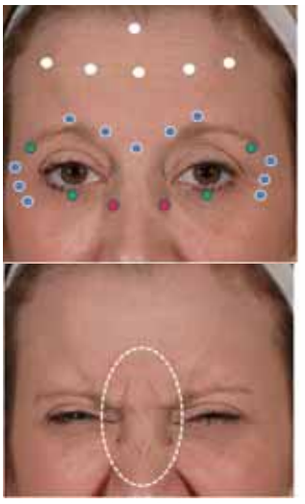

Scrunching Nose Before Dysport



Scrunching Nose After Dysport

Fig. 1 and 2: Patient treated by Hema Sundaram, MD. Photographic images courtesy of the i.e. Aesthetics/USF CME initiative, "Beyond the Nasolabial Fold."

Fig. 2. Top: Same woman in repose (left) showing Dysport injection points. For reference, woman is shown at right before treatment when animating (scrunching nose).

Glabella: 10 DU at each of 5 injection points
Forehead: 7.5 DU at each of 6 injection points
Crow's Feet: 10 DU at each of 3 injection points
Bunny lines: 5 DU at each of 2 injection points
Brow Shaping: 2.5 DU at each of 2 injection points
Eye Opening: 2.5 DU at each of 2 injection points

Key
DU=Dysport Units
● = 10 DU
○ = 7.5 DU
● = 5 DU
● = 2.5 DU

Bottom: Same patient on animation (scrunching nose) before and 42 days after Dysport. Note improvement in glabellar and transverse nasal "bunny lines" (circled) with smooth transition zone between these areas of improvement.

Strategy 6. Achieve Smoother Transition Zones

There are specific situations in which Dysport may have a slightly wider zone of activity, also referred to as "field of effect," than Botox Cosmetic. Clinical studies have established that the fields of effect of Dysport and Botox Cosmetic are not associated with any increase in adverse effects - including eyelid ptosis, which is indicative of undesirable spread or diffusion of BoNT-A after glabellar injection. The incidence of eyelid ptosis is low and comparable after glabellar injection of either Dysport or Botox: Combined data from Dysport studies and the Dysport package insert show ptosis rates of 2.1 and two percent respectively,[4] while the package insert for Botox Cosmetic reports a ptosis rate of five percent based on literature reports[5] and 3.2 percent from study data.[6] As discussed in my

PD0210CosmeticsChallengeCol 2/9/10 4:44 PM Page 32

last article,[1] a wider field of effect may allow reduction in the number of injection points required to achieve desired clinical endpoints. In my experience, Dysport's wider field of effect can also facilitate the achievement of smoother transition zones when adjacent areas of the upper face are injected.

One example is when treating transverse nasal rhytides—commonly known as "bunny lines"—in conjunction with glabellar rhytides. "Bunny lines" are hyperdynamic rhytides caused by overactivity of the Nasalis muscle. The age at which they appear varies significantly and depends on various patient characteristics, including heredity. (As an anecdotal point of interest, I have noted that many patients of color have significant mass and/or activity of the Nasalis muscle and develop "bunny lines" at a relatively early age, in their teens, twenties or thirties.) Although "bunny lines" typically are limited in both extent and depth, they can be frustrating to patients, and their incomplete eradication with BoNT-A can result in patient dissatisfaction even when other areas of the upper face have been treated to perfection. It can be especially challenging to smooth out the uppermost transverse nasal rhytides, which lie just below the glabellar rhytides. When treating glabellar rhytides by injection of Dysport at the five standard points to target the Procerus, Depressor supercilii and Corrugator supercilii muscles, significant improvement can be achieved in the transverse nasal rhytides by concomitantly injecting the Nasalis muscle with 5 to 15 Dysport Units (DU) at a single point on each side. This results in global improvement of the "bunny lines" and a smooth, continuous field of effect from the glabella to the root of the nose. (Fig 2)

Another situation in which Dysport's distinct field of effect may be of benefit is when treating the lateral periocular rhytides (commonly known as "crow's feet") in patients who have significant activity of the Zygomaticus major muscle on facial animation. These patients are easily detected during pre-treatment assessment because they strongly contract Zygomaticus major when they smile, causing visible elevation and folding of the superior midface. This contributes to the formation of pronounced "crow's feet" that extend beyond the lateral periocular region onto the cheek itself. If the "crow's feet" of such patients are treated by targeting of the Orbicularis oculi muscle alone with BoNT-A, residual activity of the untreated Zygomaticus major causes a bunching effect due to upward movement of the cheek. This is aesthetically unappealing and looks unnatural. One strategy that I have employed with Botox Cosmetic to avoid bunching is to reduce the number of Botox Units (BU) injected into the most inferolateral portion of Orbicularis oculi or to forgo injection of this muscular zone altogether, so that there is a less abrupt transition from the treated Orbicularis oculi to the untreated Zygomaticus major. However, this strategy carries the risk of suboptimal improvement in the lowermost "crow's feet." With Dysport, I have found that these lowermost "crow's feet" can often be improved without injecting them directly, via injection of the "crow's feet" that lie above them. The resultant smooth transition from the lateral periocular region to the midface is presumably a manifestation of an enhanced field of effect.

Another interesting method to address overactivity of Zygomaticus major is inject a small dose of BoNT-A subdermally over this muscle. This procedure must be performed with great caution and only by experienced injectors, since over-treatment will result in impairment of facial movement and expressivity. The technique is best reserved for patients with good skin elasticity, as BoNT-A injection into the mid or lower face of patients with pre-existing skin laxity may exacerbate this problem and may be more likely to cause functional impairment. In appropriately selected patients, I have found that a small dose of Dysport injected subdermally at only one point on each side over the Zygomaticus major gives excellent results across an extended area of the cheek with no functional impairment. (Fig. 3)

Strategy 7: Leverage Longevity

When patients contemplate treatment with an injectable neurotoxin or filler, one of their primary considerations is how long their results will last. An injectable product that yields longer-lasting results is generally viewed as more desirable. For many patients, the decision as to whether or not to have

PD0210CosmeticsChallengeCol 2/9/10 4:44 PM Page 33



Before | 3 Days, 19 Hours After | 33 *Days After*

Fig. 3. Top. 45-year-old man in repose before (left); three days, 19 hours (center); and 33 days (right) after Dysport. Patient noted onset of clinical effect within 24 hours of injection. Note improvement in forehead and cheek rhytides in photos taken three days, 19 hours and 33 days after injection. In photo taken 33 days after treatment, patient has external hordeolum of right upper eyelid unrelated to BoNT-A . **Below.** Note improvement in hyperdynamic activity of Zygomaticus major (arrowed) and in crow's feet, with smooth transition zone between these areas of improvement and preservation of lower face mobility and symmetry.





Key DU=Dysport Units
- = 10 DU
- = 5 DU
- = 2.5 DU

Dysport injection points to the lateral periocular and mid face regions. Treatment objectives for these regions, with primary target muscles in parentheses, were to improve crow's feet (Orbicularis oculi) and scarring of the cheeks, and to prevent post-treatment bunching of the midface (Zygomaticus major). Note the inclusion of a single, low-dose subdermal injection point to Zygomaticus major on each side. ○ Open white circle indicates additional injection points to the glabella, forehead and Depressor anguli oris.

Patient treated by Hema Sundaram, MD. Photographic images courtesy of the PharmAdura CME initiative, "Advances in Cosmetic Therapy—A Focus on Botulinum Neurotoxin."

treatment at all rests largely upon its perceived value, and expected longevity of the treatment factors prominently into that perception of value. In my experience, it is as important to meet patients' expectations with respect to longevity as it is to appropriately address their treatment objectives.

In this regard, the data for Dysport are quite striking. Randomized, placebo-controlled single- or repeat dosing studies of 469 subjects showed a median duration of full response of 85 days in those subjects who received a dose of 50 Dysport Units (DU) to their glabellar lines.[7] In a randomized, placebo-controlled single dosing study of 816 subjects, the median duration of full response was 109 days in those subjects who received Dysport at a dose varying from 50 to 80 DU to the glabellar lines (dosage variation was based upon study subjects' gender and glabellar muscle mass).[8]

It is worth stepping back from these data and considering what they mean in the clinical context. Median durations of 85 and 107 days signify that 50 percent of subjects who received Dysport were still scored as full responders at these time points. Full response was defined rather stringently, as it tends to be in BoNT-A studies, as a composite 2+ grade improvement on the wrinkle severity scale based on assessment by blinded evaluators, by blinded investigators, and by study subjects themselves. To be scored as full responders with a 2+ grade improvement, subjects' glabellar lines at maximal frown had to improve from a "Moderate" or "Severe" rating before treatment to a rating of "None" or "Mild" after treatment. Subjects who maintained less than this 2+ grade point improvement at any given time point after Dysport injection would be scored as non-responders even if they remained clinically improved. Given these considerations, it is noteworthy that in a randomized, double-blinded, placebo-controlled study of 300 subjects, 200 of whom received Dysport at a single dose of 50 DU to their glabellar lines, investigator assessment 150 days after injection showed that 16.8 percent of Dysport-treated subjects remained full responders at maximal frown and 35.9 percent were scored as responders.[9]

PD0210CosmeticsChallengeCol 2/9/10 4:44 PM Page 34

Strategy 8: See the Big Picture

A thorough understanding of Dysport dosing is a prerequisite for integrative treatment. Dosing of Dysport is easily mastered, whether you prefer to think directly in Dysport Units (DU) or to convert from Botox Units (BU). I find it more logical to think directly in Dysport Units, with 10 DU being a standard dose per injection point, 7.5 DU or 5 DU per injection point being used for smaller doses, and 2.5DU per point being used for the smallest dose {Table 1). In the upper face, I use this smallest dose of 2.5 DU for conservative brow shaping, eye-opening and minor adjustment of previous treatment.

When assessing the results of integrative facial rejuvenation, it is essential to evaluate general facial reshaping while remaining aware of what has been specifically improved in each individual facial zone. In the vernacular sense, this entails an appreciation of the whole forest in addition to the individual trees. I believe that it is only through this dual appreciation that we can advance and refine our skills with BoNT-A. This process parallels the balance we strive for when consulting with our patients. Like us, patients sometimes have a tendency to over-focus on the trees. The most extreme example is the patient who brings a magnifying mirror into the consultation room to point out flaws invisible to the naked eye, and who requires encouragement to consider the big picture—the overall improvement that is possible.

I have found evaluation of high quality, digital pre- and post-treatment photographs to be immensely helpful in developing my strategies for integrative facial rejuvenation with BoNT-A. Full-face images provide an overview of the improvement that has been achieved, while close-ups allow a more in-depth analysis of results. A number of new Continuing Medical Education (CME) initiatives refine this evaluation process. One, "Advances in Cosmetic Therapy - A Focus on Botulinum Neurotoxin A" (ACT), comprises local and regional workshops that present innovative, synchronized video of BoNT-A injection techniques and results, within the framework of a comprehensive program that includes consensus recommendations for on-label and off-label aesthetic use of Dysport and Botox Cosmetic. ■

Table 1. Simple Dysport Dosing

- Standard Dysport dose per injection point: 10 DU
- Smaller Dysport dose per injection point: 7.5 or 5 DU
- Smallest Dysport dose per injection point: 2.5 DU

Thinking in Tens and Fives

Glabella: Inject 10 DU at each of the 5 standard glabellar injection points (Total 50 DU)

Forehead: Inject 10 DU at 3 to 5 points (Total 30 to 50 DU)

Crow's feet: Inject 10 DU at 2 to 5 points on each side (Total 40 to 100 DU on both sides)

Brow Shaping: Inject 2.5 to 10 DU on each side at 1 point (under lateral eyebrow margin)

Eye Opening: Inject 2.5 to 5 DU on each side at 1 point (at lower ciliary margin in mid-pupillary line)

As clinicians gain experience with Dysport they may wish to modify these suggested starter doses for further individualization of treatment.

Dr. Sundaram serves on the Steering Committee for The PharmAdura Continuing Medical Education initiative, "Advances in Cosmetic Therapy - A Focus on Botulinum Neurotoxin A" (ACT), supported by independent educational funding from Medicis Pharmaceutical Corp. Physicians may register to attend an ACT progam by calling (877) 252-5100 ext.29 or by faxing information to PharmAdura, LLC: (845) 398-5108.

Dr. Sundaram has performed media work for Allergan, Inc., and serves as an Advisor, Clinical Investigator, Consultant, and/or Speaker for Bioform Medical, Johnson & Johnson, Medicis Pharmaceutical Corp., SkinMedica, Inc. and Syneron Medical. She has no stocks, shares, or other financial interests in these or any other pharmaceutical or device companies.

1. Sundaram H. Practical Primer for Dysport Part 3: Putting It All Together-Strategies for Success with Integrative Rejuvenation of the Upper Face. Practical Dermatology 2009; 6(11):47-52.

2. Rubin, M, Dover J, Glogau R et al. The efficacy and safety of a new U.S. botulinum toxin type a in the retreatment of glabellar lines following open-label treatment: Results from a randomized, controlled phase 3 clinical trial. J Drugs Dermatol 2009. 8(5):439-44.

3. Sundaram H. Expanding the Field: A New Botulinum Neurotoxin A Enters the US Arena. Practical Dermatology 2009; 6(6):17-20.

4. Dysport Summary of Product Characteristics. Ipsen, Ltd. June 2007.

5. Botox Cosmetic Package Insert, Allergan, Inc. 2008.

6. Botox Cosmetic Product Monograph, Allergan, Inc. Revised March 2002. Accessible online at www.fda.gov/cder/foi/label/2002/botuall041202LB.pdf

7. Brandt F, Swanson N, Baumann L, et al. Randomized, Placebo-Controlled Study of a New Botulinum Toxin Type A for Treatment of Glabellar Lines: Efficacy and Safety. Derm Surg 2009. 35(12): 1893 - 1901.

8. Kane M, Brandt F, Rohrich R, et al. Evaluation of variable dose treatment with a new US botulinum toxin type a (DysportTM) for correction of moderate to severe glabellar lines: results from a phase 3, randomized, double-blind, placebo-controlled study. Plast Reconstr Surgery 2009. 124(5):1619-29.

9. Data on file, Medicis Pharm. Corp.