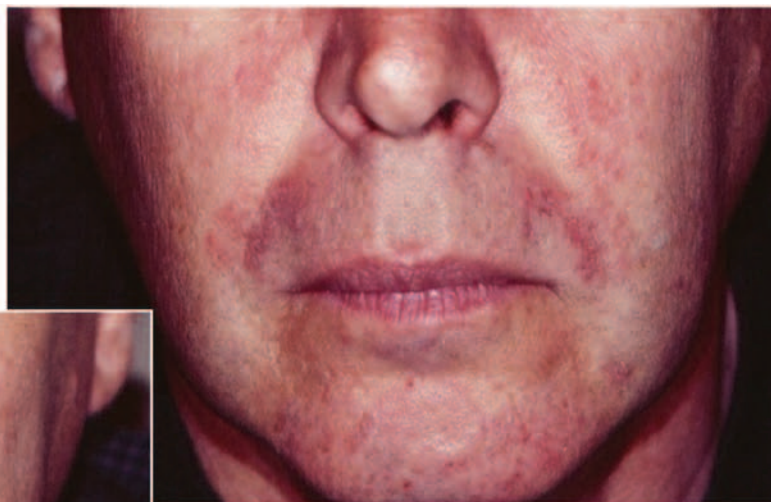
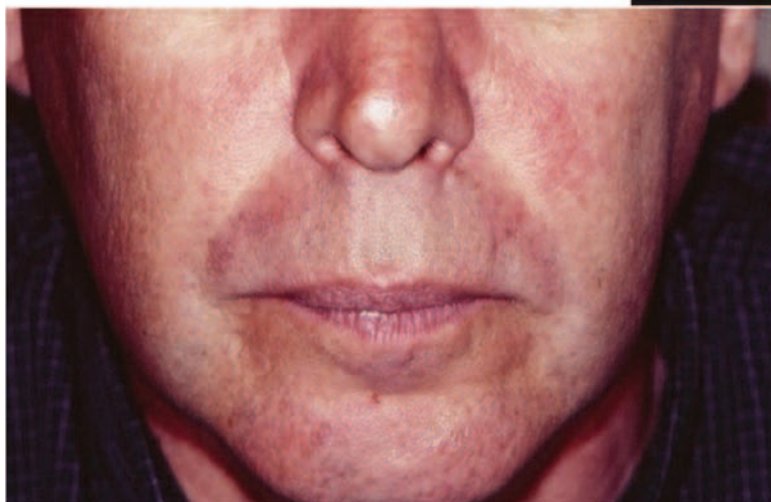


Revisiting Facial Seborrheic Dermatitis: A New Therapeutic Option

A popular topical agent offers anti-inflammatory, antibacterial, and sebo-suppressive effects that could prove useful for management of seborrheic dermatitis.

By Joseph Bikowski, MD

Seborrheic dermatitis is a chronic superficial mycotic disorder that usually appears as areas of erythema covered by greasy yellow-to-brown flakes or scales. The condition most often affects the nasolabial folds, glabella, forehead, scalp, ears, trunk, and other areas of increased sebaceous gland activity. In some patients, the axil-

lae, groin, and other intertriginous areas are involved. Distribution is usually symmetrical.¹⁻³ Although seborrheic dermatitis is included among the “red face” disorders, it is not usually accompanied by flushing or inflammatory papules and pustules, although it often coexists with rosacea or other papulopustular dermatoses.⁴ Severity is variable, ranging from barely per-

ceptible scales and erythema to coarse, thick scales and intense erythema that does not blanch to the touch.⁵ The lesions may be generalized or even erythrodermic, and pruritus may be present, as well.^{1,2} Because the typical clinical course includes remissions and relapses and may be progressive,⁶ it is important to provide directed therapy both for exacerbations and prophylaxis.

An extremely common disorder, seborrheic dermatitis is estimated to occur in about one to five percent of the US population,^{1,2} peaking within the first three months of life and again during the fourth to the seventh decades.¹ Dandruff, considered by many to be the mildest form of seborrheic dermatitis, may occur in as many as 50 percent of the world's population.⁷ The risk is increased by as much as 83 percent in people who are immunocompromised,⁸ and it is also raised to a lesser extent in those with Parkinson's disease or other neurologic disorders,⁹ and those with mood disorders.¹⁰ Other triggers, including stress³ and reduced exposure to sunlight, have also been reported.²

Although no conclusive etiology has been established, certain contributing factors are widely recognized. Hormones probably play a role: androgens stimulate development of the pilosebaceous unit, and seborrheic dermatitis is in fact more common in men than in women and reappears after puberty.²

One factor important in current approaches to therapy is the relationship between seborrheic dermatitis and lipid-dependent *Malassezia* yeasts (formerly *Pityosporum ovale*), normal inhabitants of the skin.¹¹ That is supported by evidence of reduction of symptom severity with use of antifungals active against *Malassezia*¹² as well as correlation between *Malassezia* yeast density and clinical severity of the condition.¹³ Exactly how *Malassezia* contributes to seborrheic dermatitis is in question. Suggested mechanisms include underlying abnormal immune response,¹⁴ defective skin barrier function,¹¹ and inflammation resulting from yeast-mediated release of irritant free fatty acids.¹¹ The link between seborrheic dermatitis and neurologic disorders such as Parkinson's disease is not well understood; one hypothesis is that neurogenic immobility prevents proper skin hygiene, leading to a larger residual pool of sebum that thus encourages the growth of *Malassezia* yeasts.¹¹

The differential diagnosis of seborrheic dermatitis is wide, including many common disorders, such as psoriasis, atopic dermatitis, acne vulgaris, rosacea, Demodex dermatitis, and tinea infections. Scalp and face lesions may be similar to those of impetigo and intertriginous lesions to those of candidiasis.¹ Other disorders to rule out are dermatophytoses, pityriasis versicolor, irritant/allergic contact dermatitis, systemic lupus erythematosus, Langerhans cell histiocytosis, and secondary syphilis.^{1,3}

Although diagnosis of seborrheic dermatitis is usually clinical, based on history and the appearance and site of the lesions, a negative KOH examination may help to rule out candidiasis,

tinea infection, or Demodex dermatitis. Histology may also be helpful: the characteristic spongiform appearance of early seborrheic dermatitis can help distinguish it from psoriasis, although differentiation in later stages is more difficult.²

An important point for both diagnosis and management is that seborrheic dermatitis is often accompanied by other dermatologic disorders. Among the most common concurrent disorders are acne vulgaris, rosacea, and Demodex dermatitis. Among patients with rosacea, the incidence of seborrheic dermatitis may be as high as 35 percent,¹⁵ with facial symptoms present in more than one quarter of cases.⁴ Therapy that addresses coexisting conditions is, of course, preferred; otherwise, treatment of one of these disorders may well exacerbate the other.

Extending the Therapeutic Armamentarium

There is no cure for seborrheic dermatitis, but it can be lessened and controlled with one or more of the agents shown to be effective in the condition. Most are topical or shampoo formulations. Current treatment and prophylaxis regimens usually include antifungal agents, most often azoles. Antikeratolytic agents such as selenium sulfide, propylene glycol, sulfur, and coal are used to address scaling and flaking.^{1,3} Mild topical steroids, which should be used primarily during exacerbations, can help control erythema and pruritus.¹ The immunomodulatory activity of topical calcineurin inhibitors such as tacrolimus and pimecrolimus may be particularly useful in patients with concomitant rosacea. Oral antifungal agents or phototherapy are reserved for the most severe cases.¹ Equally important with choice of agent is an appropriate skin care regimen, including cleansers and moisturizers that help restore the skin barrier—especially ceramide-containing preparations that provide balanced physiologic lipid replacement.

Azelaic acid is currently indicated in the United States for topical treatment of inflammatory papules and pustules of mild to moderate rosacea and indicated elsewhere for acne. In addition, it appears potentially effective for seborrheic dermatitis. The clinical efficacy and safety of azelaic acid 15% gel for rosacea is well known; studies show significant, rapid improvement in signs and symptoms with this agent, as well as good tolerance.¹⁶⁻¹⁷ Its mechanisms of action address both symptomatic and suggested etiologic aspects of seborrhea as well as rosacea. Studies confirm antimicrobial properties, sebosuppressive activity,¹⁸ antikeratinizing activity,¹⁹⁻²⁰ anti-inflammatory and immunomodulatory effects,²¹⁻²³ and antimycotic activity²⁴—including specific activity against *Malassezia*.²⁵ Azelaic acid may therefore be considered a useful addition to the armamentarium for seborrheic dermatitis. It may be especially valuable because of its concomitant action against rosacea, a common accompanying disorder. Two patient histo-

Seborrheic Dermatitis

ries are presented in which azelaic acid provided effective treatment for seborrheic dermatitis.

Case 1

A 32-year-old man came to the office with multiple symmetrical confluent scaly red patches on his lower face, to include the nasal creases, nasolabial fold, and chin (Fig. 1a). These were associated with minimal to moderate itching and burning. He also had minimal scalp flaking. The patches and flaking had developed over the previous two years, waxing and waning, but gradually becoming more severe, especially during the winter. The patient had been treating himself with over-the-counter lotions and preparations, but he was becoming worried because the condition seemed to be getting worse, especially on his face. A potassium hydroxide preparation showed no evidence of tinea infection. He was diagnosed with seborrheic dermatitis and prescribed a daily cleansing and moisturizing regimen using a ceramide-containing preparation along with twice-daily application of azelaic acid 15% gel to the affected areas. On a follow-up visit two weeks later, the lesions had improved notably (Fig. 1b). He was instructed to continue to use the prescribed regimen. He continued the medication over several months without any adverse effects.

Discussion. This case history illustrates the typical progressive onset of seborrheic dermatitis during adulthood. Because the condition—like rosacea, acne, and atopic dermatitis—features a skin barrier dysfunction, use of a barrier-repair cleanser and/or lotions is important. Balanced ceramide-containing lotions will help restore normal skin barrier function and may in fact aid in absorption of medications. In this case, azelaic acid, which addresses many other underlying processes of seborrheic dermatitis,¹⁸⁻²⁵ along with a cleansing/moisturizing regimen aimed at strengthening barrier function, provided a quick-acting, effective, well-tolerated therapeutic regimen for an acute exacerbation.

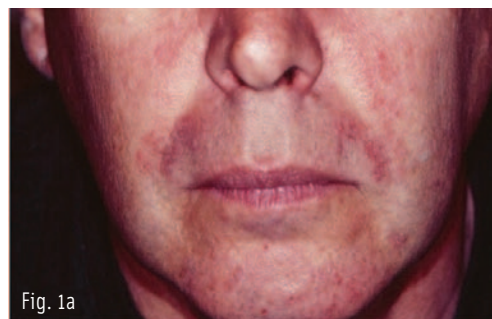

Fig. 1a

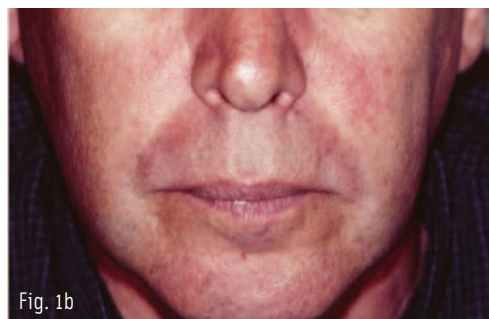

Fig. 1b

A 32-year-old man with an exacerbation of seborrheic dermatitis at presentation (1a) and two weeks after starting a regimen of azelaic acid 15% gel plus a balanced barrier-repair cleansing/moisturizing regimen (1b)

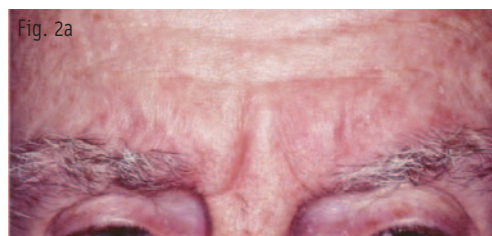

Fig. 2a

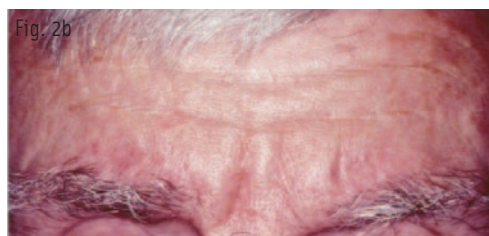


Fig. 2b

A 67-year old man with a flare-up of seborrheic dermatitis not responding to topical steroids at presentation (2a) and after four weeks of treatment with after azelaic acid 15% gel (2b)

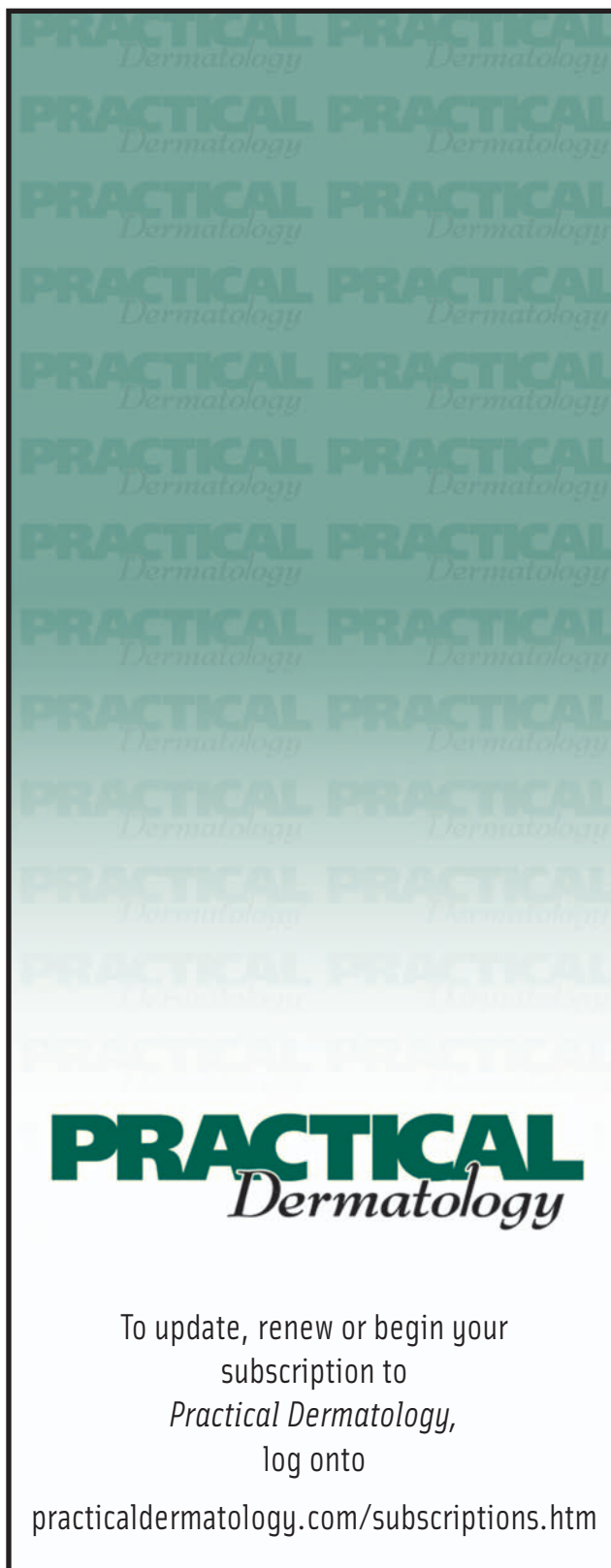
Case 2

A 67-year old man presented with a flare-up of his long-standing seborrheic dermatitis that was no longer responding to topical steroids. He had been using a regimen of over-the-counter topical corticosteroids, along with moisturizers and cleansers, as the mainstay of therapy. He was taking no medication for his concomitant mild rosacea, which appeared as a few scattered facial papules and pustules. On examination, the patient had red patches with scaling on his forehead, eyebrows, glabella, and nasolabial folds, as well as behind the ears (Fig. 2a). He was instructed to stop using the steroid preparation and prescribed azelaic acid 15% gel twice daily. His signs and symptoms began to abate immediately. On his return for follow-up visit four weeks later, the lesions had almost disappeared and his rosacea had also lessened (Fig. 2b).

Discussion: Topical steroids will treat inflammation and erythema but are not ideal in seborrheic dermatitis because they have no fungicidal or keratinolytic properties, and long term use may lead to cutaneous atrophy or, paradoxically, steroid use/abuse/misuse dermatitis.¹ Azelaic acid's constellation of properties matches the known mechanisms underlying seborrheic dermatitis. In this patient, the agent has the additional advantage of working to reduce concurrent rosacea signs and symptoms. Azelaic acid is a promising alternative to current antifungal and anti-inflammatory agents. ■ ☒

Dr. Bikowski has served on the advisory board, served as a consultant, received honoraria, and/or served on the speaker's bureau for Allergan, Barrier, CollaGenex, Coria, Galderma, Intendis, Medicis, OrthoNeutrogena, PharmaDerm, Quinnova, Ranbaxy, Sanofi-Aventis, SkinMedica, Stiefel, UCB, and Warner Chilcott.

1. Plewig G, Jansen T. Seborrheic dermatitis. In: Wolff K, Goldsmith LA, Katz AI, Gilchrist BA, Paller A, Leffell DJ, eds. Fitzpatrick's Dermatology in General Medicine. 7th ed. New York, NY: McGraw-Hill Professional. 2007: 219-225.
2. Gupta AK, Bluhm R. Seborrheic dermatitis. J Eur Acad Dermatol Venereol. 2004;18(1):13-26.
3. Schwartz RA, Janusz CA, Janniger CK. Seborrheic dermatitis: an overview. Am Fam Physician. 2006;74(1):125-130.
4. Del Rosso J. The prevalence of seborrheic dermatitis in patients with other commonly encountered facial dermatoses. Poster presentation, American Academy of Dermatology Summer Academy, New York, New York. July 28 to August 1, 2004.
5. Swinyer LJ, Decroix J, Langner A, Quiring JN, Blockhuys S. Ketoconazole gel 2% in the treatment of moderate to severe seborrheic dermatitis. Cutis. 2007;79(6):475-482.
6. Crutchfield CE 3rd. Pimecrolimus: a new treatment for seborrheic dermatitis. Cutis. 2002;70(4):207-208.
7. Cardin C: Isolated dandruff. In: Baran R, Maibach H (eds). Textbook of Cosmetic Dermatology. Malden, MA: Blackwell Science, 1998; 193-200.
8. Mathes BM, Douglass MC. Seborrheic dermatitis in patients with acquired immunodeficiency syndrome. J Am Acad Dermatol. 1985;13(6):947-951.
9. Cowley NC, Farr PM, Shuster S. The permissive effect of sebum in seborrheic dermatitis: an explanation of the rash in neurological disorders. Br J Dermatol. 1990;122(1):71-76.
10. Maietta G, Fornaro P, Rongioletti F, Rebora A. Patients with mood depression have a high prevalence of seborrheic dermatitis. Acta Derm Venereol. 1990;70(5):432-434.
11. DeAngelis YM, Gemmer CM, Kaczvinsky JR, et al. Three etiologic facets of dandruff and seborrheic dermatitis: Malassezia fungi, sebaceous lipids, and individual sensitivity. J Investig Dermatol Symp Proc. 2005;10(3):295-297.
12. Ortonne JP, Lacour JP, Vitetta A, Le Fichoux Y. Comparative study of ketoconazole 2% foaming gel and betamethasone dipropionate 0.05% lotion in the treatment of seborrheic dermatitis in adults. Dermatology. 1992;184(4):275-280.
13. Zaidi Z, Wahid Z, Cochinwala R, Soomro M, Qureshi A. Correlation of the density of yeast Malassezia with the clinical severity of seborrheic dermatitis. J Pak Med Assoc. 2002;52(11):504-506.
14. Piérard-Franchimont C, Arrese JE, Pierard GE. Immunohistochemical aspects of the link between Malassezia ovalis and seborrheic dermatitis. J Eur Acad Dermatol Venereol. 1995;4:14-19.
15. International Rosacea Foundation Web site. What is rosacea? Available at <http://www.internationalrosaceafoundation.org>. Accessed May 8, 2008.
16. Thiboutot D, Thieroff-Ekerdt R, Graue K. Efficacy and safety of azelaic acid (15%) gel as a new treatment for papulopustular rosacea: results from two vehicle-controlled, randomized phase III studies. J Am Acad Dermatol. 2003;48:836-845.
17. Elewski BE, Fleischer AB Jr, Pariser DM. A comparison of 15% azelaic acid gel and 0.75% metronidazole gel in the topical treatment of papulopustular rosacea: results of a randomized trial. Arch Dermatol. 2003;139(11):1444-1450.
18. Stinco G, Bragadin G, Trotter D, Pillon B, Patrone P. Relationship between sebostatic activity, tolerability and efficacy of three topical drugs to treat mild to moderate acne. J Eur Acad Dermatol Venereol. 2007;21:320-325.
19. Del Rosso JQ, Baum EW, Draelos ZD, et al. Azelaic acid gel 15%: clinical versatility in the treatment of rosacea. Cutis. 2006;78(5 Suppl):6-19.
20. Passi S, Picardo M, De Luca C, Nazzaro-Porro M. [Mechanism of azelaic acid action in acne] G Ital Dermatol Venereol. 1989;124(10):455-463.
21. Passi S, Picardo M, Zompetta C, et al. The oxyradical-scavenging activity of azelaic acid in biological systems. Free Radic Res Commun. 1991;15(1):17-28.
22. Passi S, Picardo M, De Luca C, Breathnach A, Nazzaro-Porro M. Scavenging activity of azelaic acid on hydroxyl radicals "in Vitro." Free Radic Res Commun. 1991;11(6):329-338.
23. Akamatsu H, Komura J, Asada Y, Miyachi Y, Niwa Y. Inhibitory effect of azelaic acid on neutrophil functions: a possible cause for its efficacy in treating pathogenetically unrelated diseases. Arch Dermatol Res. 1991;283(3):162-166.
24. Brasch J, Christophers E. Azelaic acid has antimycotic properties in vitro. Dermatology. 1993;186(1):55-58.
25. Data on file, Intendis, GmbH.



PRACTICAL
Dermatology

To update, renew or begin your
subscription to
Practical Dermatology,
log onto
practicaldermatology.com/subscriptions.htm