

## An Entirely New Category Changes the Face of Laser Resurfacing: The Hybrid Fractional Laser



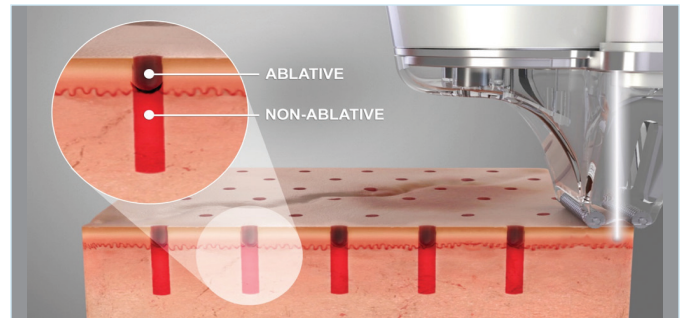
Jason Pozner, MD, FACS; Sanctuary Medical Center, Boca Raton, FL

Chris W. Robb, MD, PhD; Skin and Allergy Center, Spring Hill, TN

The binary options of full-field ablative Er:YAG resurfacing or fractional ablative resurfacing meant that patients had to choose between extended downtime and fewer treatments (full-field) or less downtime but more treatments (fractional). In the meantime, non-ablative fractional lasers arose, using sub-ablative pulses to coagulate tissue instead of ablating and vaporizing it. Non-ablative fractional resurfacing allowed patients to heal more quickly, but the procedure did not entirely meet patient or physician expectations.

Based on the performance of non-ablative and ablative fractional lasers, the idea to combine the two in a singular dual-wavelength laser was born. Halo, the first hybrid fractional laser (HFL), delivers both 1470nm and 2940nm wavelengths to the same microscopic thermal zone (MTZ). The HFL works by delivering ablation sequentially followed by coagulation to the MTZ. Using the 2940nm Er:YAG, Halo delivers 100% pure ablation between 0 and 100 microns into the epidermis; using the 1470nm diode, Halo delivers 100% coagulation between 100 to 700 microns to the epidermis and dermis. The precision of delivery in the epidermis and dermis gives Halo the unprecedented ability to provide customized treatments in the epidermis and dermis.

Beyond the unique hybrid technology that Halo offers are features that improve usability and safety. Both the 2940 and 1470nm wavelengths feature tunable depth and coverage on the skin. Additionally, Halo uses intelligent energy-based parameters to ensure a consistently even treatment by measuring the size of

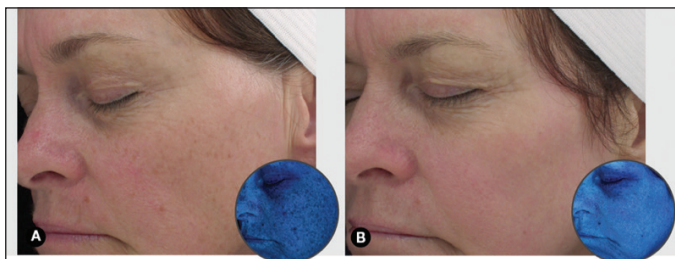


the area being treated and calculating the energy necessary to complete the treatment. New Dynamic Thermal Optimization (DTO) technology ensures treatments that are even from start to finish, monitoring the temperature of the skin before each pulse and adjusting the pulse energy to ensure that the depth of the treatment matches the depth displayed on the user screen.

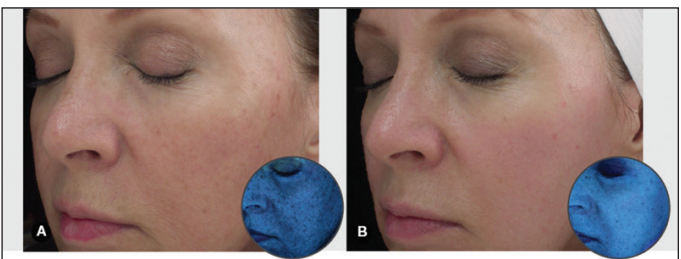
In clinical testing patients treated with Halo showed remarkable improvement in pigment and texture. Within 1-2 treatments, patients saw the type of results typically seen with 5-6 treatments with older non-hybrid technology. The residual improvement in pore size and number was also unanticipated. Patients in the initial Halo clinical study preferred the healing experience to other laser resurfacing treatments, citing less overall pain after treatment, the ability to put on makeup in one day, short duration of peeling, and ease of the treatment (i.e., no need for nerve blocks).

In summary, Halo, from Sciton, is changing the face of laser resurfacing by offering a tunable, effective, and safe alternative to existing resurfacing treatments. ■

1. Laubach HJ, et al. Skin responses to fractional photothermolysis. *Lasers Surg Med*;38:142-9. • 2. Cohen JL, Ross EV. Combined fractional ablative and nonablative laser resurfacing treatment: a split-face comparative study. *J Drugs Dermatol*;12(2):175-8.
- 3. Orringer JS, et al. Intraepidermal erbium:YAG laser resurfacing: impact on the dermal matrix. *JAAD*;64(1):119-28. • 4. Paithankar DY, et al. Subsurface skin renewal by treatment with a 1450-nm laser in combination with dynamic cooling. *J Biomed Opt*;8(3):545-51. • 5. Laubach H, et al. Effects of skin temperature on lesion size in fractional photothermolysis. *Lasers Surg Med*. 2007 Jan;39(1):14-8.



HALO A) before and B) after 2 treatments | 1470 nm: 350  $\mu$ m, 45%; 2940 nm: 20  $\mu$ m, 30%  
courtesy of Sanctuary Medical Center



HALO A) before and B) after 2 treatments | 1470 nm: 350  $\mu$ m, 35%; 2940 nm: 50  $\mu$ m, 30%  
courtesy of Sanctuary Medical Center

## A Possible Renaissance for Resurfacing Lip Lines?



*Joel L. Cohen, MD, FAAD: AboutSkin Dermatology and DermSurgery, Englewood, CO*

During the 1990s, ablative CO<sub>2</sub> laser skin resurfacing largely supplanted chemical peels and dermabrasion because it gave physicians greater control over the depth of injury, and hence results.<sup>1</sup> However, patients had to accept typically at least two weeks of healing downtime, during which they experienced erythema (which could last for months), inflammation, and edema. To avoid these problems, fractional photothermolysis was developed to enhance the safety and healing of fractional CO<sub>2</sub>, but yielded results that were lower than what many patients desired.<sup>2</sup>

### THE UNTAPPED POTENTIAL FOR PERIORAL RESURFACING USING 2940nm VS. CO<sub>2</sub>

Because skin absorbs the CO<sub>2</sub> wavelength less efficiently, some of the laser pulse energy used with CO<sub>2</sub> resurfacing remains in the tissues after treatment, destroying collagen and creating a zone of necrotic tissue extending from the base of each column of tissue ablation. The more necrotic tissue the body must dispose of, the longer the accompanying erythema and edema lasts.<sup>3-5</sup> In contrast, the erbium laser's higher absorption in water results in near-pure ablation, leaving virtually no heat within treated tissues.<sup>6</sup>

Unfortunately, the fact that aqueous tissues absorb the erbium wavelength so efficiently coupled with the low power of first-generation erbium lasers fueled the misperception that erbium lasers could only ablate to shallow depths. The good news is that today's higher-powered, more sophisticated third-generation scanners produce significantly deeper ablation quickly without leaving much char, thus allowing for faster healing than full-field CO<sub>2</sub>. Additionally, the lack of heat created by full-field erbium ablation leads to low rates of persistent erythema and virtually no long-term hypopigmentation. Thus, far from being limited to superficial resurfacing, full-field erbium resurfacing can outperform fractional or full-field CO<sub>2</sub> for deep perioral wrinkles; CO<sub>2</sub> fails to adequately address deeply etched perioral lines.

### SEEING IS BELIEVING

My own clinical experience treating perioral rhytides with 2940nm wavelength suggests the unique absorption characteristics of skin for this wavelength make it more effective than full-field CO<sub>2</sub> ablation, while at the same time decreasing associated

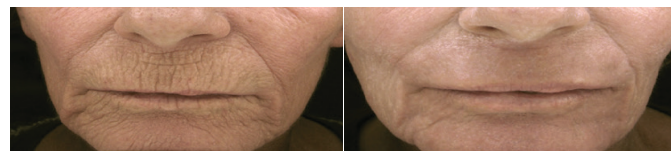
recovery times, and avoiding the hypopigmentation and unnatural textural changes commonly seen after full-field CO<sub>2</sub> ablation.<sup>2,3</sup> I believe there is no better modality than 2940nm erbium to help avoid the pitfalls of fully ablative CO<sub>2</sub> resurfacing while not sacrificing results in the perioral and periorbital areas.

Here is a quick summary of my methods. For pre-procedure anesthesia, I typically use an infraorbital block for the peri-ocular area, and a lip sulcus ring block for the perioral area (with 2% lidocaine without epinephrine to help visualize the endpoint of pinpoint bleeding). To treat significant photodamage etched-in lines on the upper lip, I perform 3 to 4 passes with a dual-mode Er:YAG tunable resurfacing laser (Contour TRL, Sciton, Inc.). Using a computer-scanned 4mm spot, the laser is tuned to provide 150μ of ablation per pass. Pinpoint bleeding that occurs at this juncture should be gently wiped off. If etched lines remain, patients require an additional pass at 150μ ablation. At that point, any very focal residual etched-in lines are treated with the scanner set for a very small spot size (setting 3) placed directly over the line at 30μ ablation until few or no lines remain.

A far cry from early erbium lasers, the dual-mode erbium laser provides the most power and versatility of any available laser, allowing for unparalleled success in treating deep perioral wrinkles. ■

*Dr. Cohen is a speaker and consultant for Sciton.*

1. Khatri K, et al. Patient views of comparison of erbium:YAG and CO<sub>2</sub> laser resurfacing. *Lasers Surg Med.* 1998; 10(Suppl):76.
2. Manstein D, et al. Fractional photothermolysis: a new concept for cutaneous remodeling using microscopic patterns of thermal injury. *Lasers Surg Med.* 2004; 34:426-38.
3. Weinstein C. Carbon dioxide laser resurfacing. In: *Cosmetic Surgery of the Skin.* Coleman WP, Hanke CW, Alt TH, Asken S, eds. St. Louis: Mosby, 1997:152-177.
4. Hruza GJ, Dover JS. Laser skin resurfacing. *Arch Dermatol.* 1996; 132:451-5.
5. Perez MI, Bank DE. Facial skin resurfacing with the Erbium:YAG laser: new findings. *Cosmetic Dermatol.* 1998; 11:27-37.
6. Fleming D. Controversies in skin resurfacing: the role of erbium. *J Cutan Laser Ther.* 1999; 1:15-21.



65-y/o female at baseline and 6 weeks after treatment 2 (23 weeks post treatment 1).

TABLE 1 – PERIORAL SETTINGS

		Ablation	Coag. setting	Laser	Passes
Treatment 1	Upper lip	150 μ	0	Erbium TRL	3
	Lower lip	150 μ	0	Erbium TRL	1
		100 μ	0	Erbium TRL	1
Treatment 2	Upper lip	150 μ	0	Erbium TRL	3
	Lower lip	150 μ	0	Erbium TRL	1
		200 μ	1	ProFractional-XC	1