

# WHERE WE ARE TODAY WITH MIGS

## The Trabecular Meshwork and Schlemm Canal

### iStent Trabecular Micro-Bypass Stent

BY LEON W. HERNDON, MD



The number of people suffering from glaucoma worldwide is expected to exceed 70 million by 2020,<sup>1</sup> making the need for safe, effective treatment greater than ever. The popularity of microinvasive glaucoma surgery has been growing, because these procedures can effectively and consistently reduce IOP with distinctly low complication rates and shorter recovery times, in many cases eliminating the need for medication. The iStent Trabecular Micro-Bypass Stent (Glaukos; Figure) has proven to be effective. Draining aqueous flow into Schlemm canal from the anterior chamber, effectively bypassing the damaged or blocked trabecular meshwork, the device can help lower IOP and manage mild to moderate

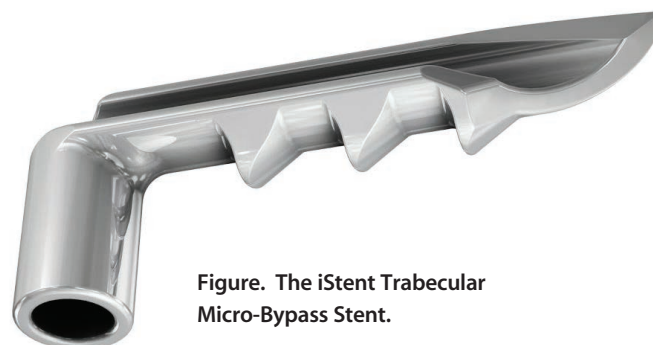


Figure. The iStent Trabecular Micro-Bypass Stent.

glaucoma without the significant cost, inconvenience, and adherence issues often associated with the use of topical medical therapy. There are other ab interno procedures that target the trabecular meshwork (discussed elsewhere in this issue), but the iStent is the only device currently available that is left in Schlemm canal, allowing for continuous aqueous outflow. (See *Watch It Now*.)

#### SAFETY AND EFFICACY

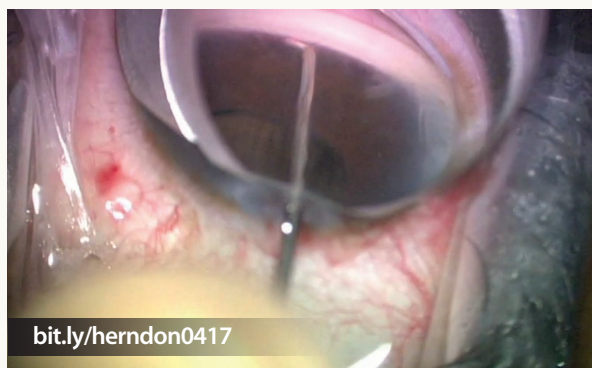Although cataract surgery on its own modestly reduces IOP,<sup>2</sup> numerous clinical trials have now shown that the implantation of a single iStent in conjunction with the cataract procedure can result in an even greater reduction of IOP and decrease the patient's need for medications.<sup>3-6</sup> The pivotal trial illustrated the device's excellent safety and efficacy profile.<sup>3</sup> With regard to efficacy, 66% of iStent subjects achieved an IOP reduction of at least 20% without medication at 1 year compared to only 48% of the control group. The impeccable safety record of cataract surgery was maintained with the iStent.

#### MORE STENTS

As surgeons' overall understanding of the iStent's effectiveness increases, new possibilities arise. Currently in the United States, the device is indicated for use in conjunction with cataract surgery to reduce IOP in patients with mild to moderate glaucoma who are being treated with medication. If one stent does not produce the desired outcome, the iStent is titratable, although implanting multiple devices is an off-label use in this country. The placement of two or three stents in a solo procedure has also been found to be effective in lowering IOP and reducing or eliminating the need for medication.<sup>7-10</sup>

## WATCH IT NOW

Leon W. Herndon, MD, implants the iStent Trabecular Micro-Bypass Stent after performing cataract surgery and placing an IOL.



bit.ly/herndon0417

## THE NEXT GENERATION

The iStent Inject (Glaukos) is not yet approved by the FDA and is currently being studied for use both in conjunction with cataract surgery and as a solo procedure. The iStent Inject comes loaded with two stents, which can be inserted a few clock hours apart in the same procedure. In trials, this device has maintained the safety and efficacy profile of the first-generation iStent.<sup>10-12</sup>

1. Tham YC, Li X, Wong TY, et al. Global prevalence of glaucoma and projections of glaucoma burden through 2040: a systematic review and meta-analysis. *Ophthalmology*. 2014;121(11):2081-2090.
2. Mansberger SL, Gordon MO, Jampel H, et al. Reduction in intraocular pressure after cataract extraction: the Ocular Hypertension Treatment Study. *Ophthalmology*. 2012;119(9):1826-1831.
3. Samuelson TW, Katz LJ, Wells JM, et al; US iStent Study Group. Randomized evaluation of the trabecular micro-bypass stent with phacoemulsification in patients with glaucoma and cataract. *Ophthalmology*. 2011;118:459-467.
4. Fea AM. Phacoemulsification versus phacoemulsification with micro-bypass stent implantation in primary open-angle glaucoma: randomized double-masked clinical trial. *J Cataract Refract Surg*. 2010;36(3):407-412.
5. Craven ER, Katz LJ, Wells JM, Giamporcaro JE. Cataract surgery with trabecular micro-bypass stent implantation in patients with mild-to-moderate open-angle glaucoma and cataract: two-year follow-up. *J Cataract Refract Surg*. 2012;38:1339-1345.
6. Malvankar-Mehta MS, Iordanous Y, Chen YN, et al. iStent with phacoemulsification versus phacoemulsification alone for patients with glaucoma and cataract: a meta-analysis. *PLoS ONE*. 2015;10(7):e0131770.
7. Ahmed IK, Katz LJ, Chang DF, et al. Prospective evaluation of microinvasive glaucoma surgery with trabecular microbypass stents and prostaglandin in open-angle glaucoma. *J Cataract Refract Surg*. 2014;40(8):1295-1300.
8. Belovay GW, Naqi A, Chan BJ, et al. Using multiple trabecular micro-bypass stents in cataract patients to treat open-angle glaucoma. *J Cataract Refract Surg*. 2012;38(11):1911-1917.
9. Donnenfeld ED, Solomon KD, Voskanyan L, et al. A prospective 3-year follow-up trial of implantation of two trabecular microbypass stents in open-angle glaucoma. *Clin Ophthalmol*. 2015;9:2057-2065.
10. Arriola-Villalobos P, Martínez-de-la-Casa JM, Díaz-Valle D, et al. Mid-term evaluation of the new Glaukos iStent with phacoemulsification in coexistent open-angle glaucoma or ocular hypertension and cataract. *Br J Ophthalmol*. 2013;97(10):1250-1255.
11. Fea AM, Belda JJ, Rekas M, et al. Prospective unmasked randomized evaluation of the iStent inject versus two ocular hypotensive agents in patients with primary open-angle glaucoma. *Clin Ophthalmol*. 2014;8:875-882.
12. Voskanyan L, García-Feijóo J, Belda JJ, et al; Synergy Study Group. Prospective, unmasked evaluation of the iStent Inject system for open-angle glaucoma: Synergy Trial. *Adv Ther*. 2014;31(2):189-201.

## Hydrus Microstent

BY OLUWATOSIN U. SMITH, MD



The Hydrus Microstent (Ivantis) is an intracanalicular scaffold for the treatment of primary open-angle glaucoma. The 8-mm stent is made from a highly flexible, biocompatible alloy of nickel and titanium (Nitinol), which has been used in different medical devices. The 1-mm inlet segment rests in the anterior chamber, while the 7-mm scaffold segment resides in the lumen of Schlemm canal without obstructing collector channel ostia located along the posterior wall (Figure 1). This microinvasive glaucoma surgery (MIGS) device has been shown to increase outflow facility and reduce outflow resistance in perfusion models of human cadaver eyes.<sup>1</sup>

### TECHNIQUE

The Hydrus is currently in FDA phase 3 trials. The stent is only available as an investigational device in the United States, but it is available for use in other countries. The device falls into the trabecular bypass category of MIGS—bypassing trabecular resistance as aqueous gains direct

access to Schlemm canal. The Hydrus is designed to be implanted in conjunction with cataract surgery. The implantation technique is relatively quick through the same small incisions created during cataract surgery (see *Watch It Now* on p. 26).

### RESULTS

Enrollment is complete in the Hydrus IV Pivotal Trial, a prospective, multicenter, single-masked, controlled, randomized trial in patients with mild to moderate glaucoma undergoing cataract surgery. The trial has 556 subjects with a 2:1 randomization, making it the largest MIGS study conducted so far. Patients will undergo follow-up evaluation at the 1- and 2-year time points. Expected to close in a few years, the study will be fundamental to analysis of the device's efficacy during the US regulatory review process.

The Hydrus II study was similar to the Hydrus IV in method (see *Watch It Now* on p. 26). Results of the 100 patients (1:1 randomization) showed that the percentage with a 20% reduction in washed-out diurnal IOP was higher in patients undergoing Hydrus implantation combined with cataract surgery versus the MIGS procedure alone (80% vs 46%,  $P = .0008$ ; Figure 2) at 24 months. The proportion of patients who were free of medication was also higher in the combined group (73% vs 38%,  $P = .0008$ ).<sup>2</sup> Adverse events were similar in both groups except for the formation of peripheral

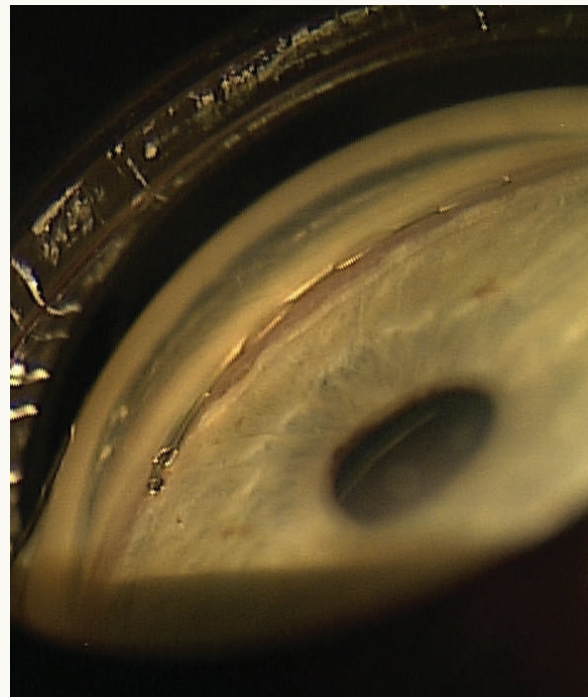


Figure 1. The Hydrus Microstent in situ. Reprinted with permission of Elsevier from Pfeiffer et al.<sup>3</sup>

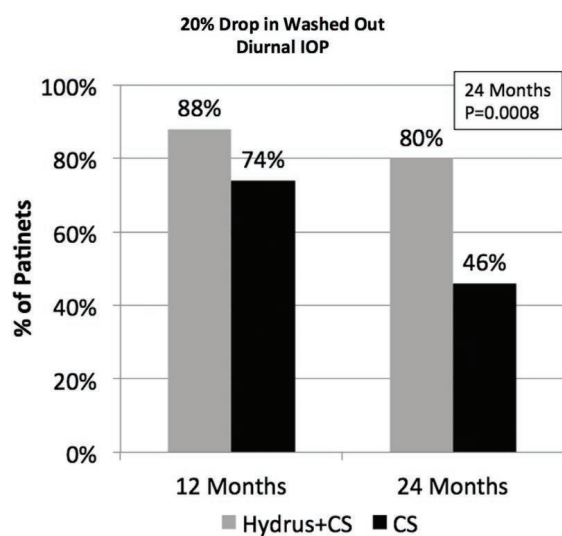


Figure 2. IOP reduction with the combined procedure compared with cataract surgery (CS) alone. Reprinted with permission of Elsevier from Pfeiffer et al.<sup>3</sup>

anterior synechiae, which was the only noted adverse event related to the device.

A recent prospective interventional case series compared the Hydrus to selective laser trabeculoplasty (SLT) for the treatment of primary open-angle glaucoma. The MIGS group achieved a significant reduction in IOP and medication use, whereas the SLT group obtained a decrease in IOP only. Postoperatively, 47% of Hydrus patients were medication free versus 4% of the SLT group.<sup>3</sup>

## CONCLUSION

The Hydrus appears to be unique in its ability to scaffold Schlemm canal over several clock hours while creating a connection with the anterior chamber unlike other trabecular bypass devices/procedures. In addition, the Hydrus has the advantage of potentially avoiding scarring in the angle, because trabecular meshwork is not removed and is minimally traumatized at the point of the device's insertion. Based on the published studies, the sustained IOP reduction at the 24-month time point will make this MIGS device a useful option for IOP reduction in patients when the procedure is performed in combination with cataract surgery. Although the data are promising so far, US surgeons must await the results of the Hydrus IV study.

1. Gulati V, Fans S, Hays CL, et al. A novel 8-mm Schlemm's canal scaffold reduces outflow resistance in a human anterior segment perfusion model. *Invest Ophthalmol Vis Sci.* 2013;54(3):1698-704.
2. Fea AM, Ahmed II, Lavia C, et al. Hydrus Microstent compared to selective laser trabeculoplasty in primary open angle glaucoma: one year results [published online ahead of print July 23, 2016]. *Clin Exp Ophthalmol.* doi:10.1111/ceo.12805.
3. Pfeiffer N, Garcia-Feijoo J, Martinez-de-la-Casa JM, et al. A randomized trial of a Schlemm's canal microstent with phacoemulsification for reducing intraocular pressure in open-angle glaucoma. *Ophthalmology.* 2015;122(7):1283-1293.

## Ab Interno Canaloplasty Using the iTrack 250A Microcatheter

BY MAHMOUD A. KHAIMI, MD



Microinvasive glaucoma surgery (MIGS) has emerged as a safe alternative to conventional surgeries for patients with mild to moderate open-angle glaucoma (OAG). The notable downside of MIGS procedures is that they treat specific areas of the outflow tract, even though there is no way of knowing that the pathology lies only in the treated area. This limitation was the impetus for the development of ab interno canaloplasty (ABiC). Unlike other MIGS procedures, ABiC treats the whole drainage system, thereby removing the "guesswork."

## DIFFERENCES

With stent-based MIGS, the aim is to bypass the diseased trabecular meshwork by placing the distal end of the device in Schlemm canal and the anterior end in the anterior chamber. No diagnostic tool exists, however, for visualizing the exact site of obstruction in OAG. For that reason, surgeons simply cannot determine how much of the canal or outflow system is not working. There is therefore a chance that the area of blockage will be missed or suboptimally treated.

ABiC, in contrast, opens up the whole outflow system and viscodilates all sites involved in the control of aqueous outflow. This stent-free procedure is performed with an illuminated microcatheter (iTrack 250A; Ellex) that is inserted via a corneal microincision (1.8 mm). It restores the natural outflow pathway with minimal tissue trauma and leaves no foreign body (tensioning suture or stent) in the eye.

ABiC is also the only MIGS procedure that addresses collector channel blockages, which studies have shown can be caused by herniated trabecular meshwork tissue. ABiC's viscodilation opens these herniations to restore full access to collector channel ostia for aqueous outflow.<sup>1,2</sup>

## RESULTS

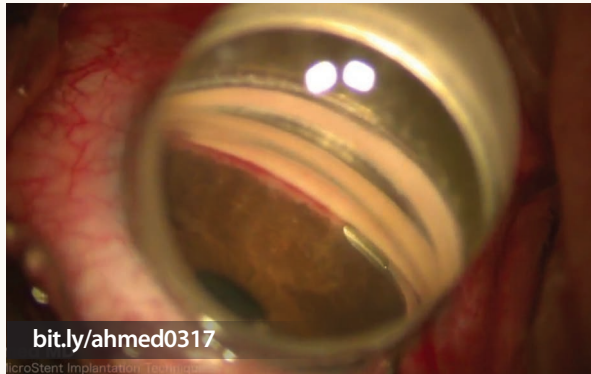
I believe the complete opening of the outflow system is the key to the encouraging results I have observed with ABiC to date. I compiled data on 86 of my patients with mild to moderate OAG whom I treated with this procedure. Their mean IOP and medication use fell by 19.1% and 78.7%, respectively, 1 year after surgery.<sup>3</sup> Some patients (n = 29) underwent ABiC only, whereas others (n = 57) also had phacoemulsification cataract surgery. Those who had ABiC alone experienced a 24.4% reduction in mean IOP and a 64.5% reduction in medication use 1 year postoperatively.

The 57 patients who underwent combined ABiC and cataract surgery had acceptable IOP levels preoperatively

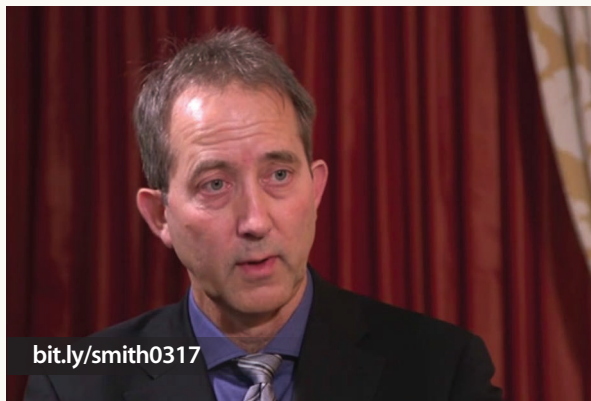

## WATCH IT NOW

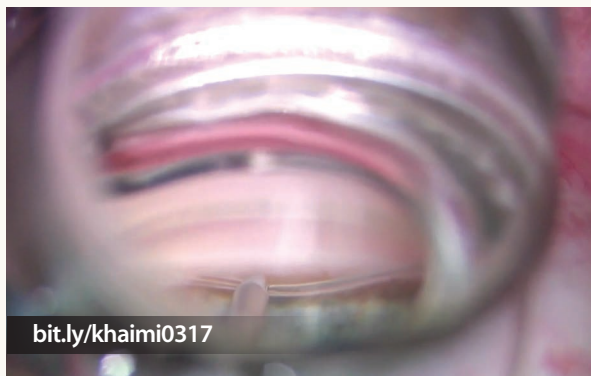Watch Iqbal Ike Ahmed, MD, implant the Hydrus Microstent.



Thomas Samuelson, MD, and Steven Vold, MD, discuss the Hydrus II study in this episode of Glaucoma Today Journal Club.



Mahmoud A. Khaimi, MD, demonstrates ab interno canaloplasty to restore the aqueous outflow pathway.



(mean, 17.92 mm Hg). Nonetheless, postoperatively, they experienced notable falls in mean IOP and medication use of 16.3% and 88.6%, respectively. This is an impressive improvement considering that their glaucoma was already controlled preoperatively and the primary reason for their surgery was to remove troublesome cataracts. More importantly, these results demonstrate a key strength of ABiC: its ability to deliver effective outcomes in a broad population, including both phakic and pseudophakic patients.

### CONCLUSION

By treating the entire outflow system (see *Watch It Now*), ABiC eliminates the guesswork that limits the efficacy of other MIGS procedures. Furthermore, because ABiC effectively reduces IOP and the medication burden, even for patients with advanced glaucoma, it presents a much-needed stent-free solution for patients with all types of OAG.

1. Gong H, Francis A. Schlemm's canal and collector channels as therapeutic targets. In: Samples JR, Ahmed I, eds. *Innovations in Glaucoma Surgery*. New York: Springer; 2014:3-25.
2. Cha EDK, Xu J, Gong H. Variations in active areas of aqueous humor outflow through the trabecular outflow pathway. *Invest Ophthalmol Vis Sci*. 2015;56(7):4850.
3. Khaimi M. Twelve-month follow-up of ab interno canaloplasty as a standalone treatment and in adjunct to cataract surgery for the treatment of primary open-angle glaucoma. Poster presented at: The 27th Annual AGS Meeting; March 9, 2017; Coronado, CA.

## Trabectome

BY SAMEH MOSAED, MD



The FDA approval of the Trabectome (NeoMedix) in 2006 introduced the first procedure for microinvasive glaucoma surgery (MIGS), ab interno trabecular ablation. The surgeon uses microelectrocautery to ablate the trabecular meshwork and inner wall of Schlemm canal. Trabectome surgery may be performed independently or in conjunction with other intraocular procedures such as cataract extraction/IOL placement (see *Watch It Now* on p. 28). It may be performed on pediatric, adult, pseudophakic, and phakic patients and is an option for treating the spectrum of glaucoma severity (ocular hypertension to end-stage disease).

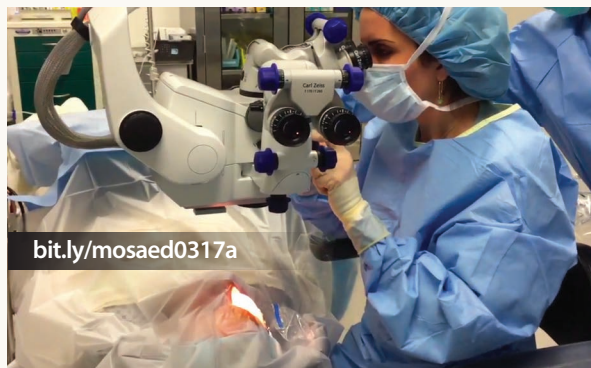### THE PROCEDURE

With a direct gonioscope, the surgeon visualizes the nasal angle structures and inserts the Trabectome's handpiece, which has built-in continuous irrigation to maintain chamber control and aspiration to optimize visibility during the procedure (see *Watch It Now*). Next, he or she gently inserts the tip of the Trabectome into the trabecular meshwork and depresses the foot pedal to activate the bipolar

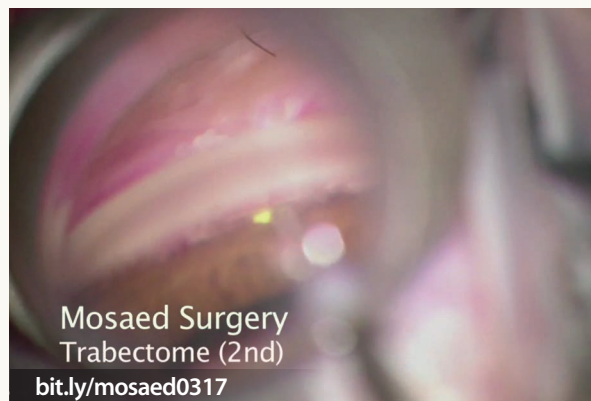

## WATCH IT NOW

Sameh Mosaed, MD, demonstrates how to set up the Trabectome and provides surgical instruction.



Dr. Mosaed combines the procedure with cataract extraction.



electrocautery, which ablates the trabecular meshwork and inner wall of Schlemm canal. The handpiece is advanced through an arc of clear visualization, which is usually between 120° and 180°. This approach ensures that the ends of the ablated tissue are not in apposition to one another, thereby minimizing fibrosis and closure of the opening. This is the key advantage of the Trabectome compared with traditional goniotomy. The procedure avoids risks typically associated with intraocular implants such as erosion, extrusion, infection, malposition, and corneal decompensation.

### RESULTS

Dozens of investigators have evaluated the long-term safety and efficacy of the Trabectome in various clinical settings. Typically, postoperative IOP measures in the midteens

regardless of the preoperative level.<sup>1</sup> The highest success rates are seen in cases of steroid-induced glaucoma, pseudoexfoliation, and other conditions where the trabecular meshwork is the site of primary pathology.<sup>1,2</sup> The lowest success rates are in patients with very low IOP targets (8-12 mm Hg).<sup>1</sup> Concurrent cataract extraction is not necessary to achieve a significant IOP reduction.<sup>3</sup>

Prior glaucoma surgery (tube shunt or trabeculectomy) does not affect the outcome of the Trabectome procedure<sup>4,5</sup> and vice versa.<sup>6</sup> The most common adverse event is transient postoperative hyphema.<sup>1,2,7-9</sup> No unexpected long-term adverse events have been reported after a decade of follow-up.<sup>2</sup>

A recent study looking at the 10-year outcomes of 5,435 cases showed that, at 90 months, IOP had decreased from an average preoperative level of 23.0 ± 7.9 mm Hg to 16.5 ± 3.8 mm Hg and that the number of glaucoma medications dropped from 2.6 ± 1.3 to 1.6 ± 1.3. These results represent an approximately 30% reduction in IOP from baseline, with a significant decrease in medication reliance.<sup>2</sup>

Another study specifically analyzed Trabectome outcomes in steroid-induced glaucoma.<sup>4</sup> The researchers reported that IOP decreased from an average of 33.8 ± 6.9 mm Hg preoperatively to 15.00 ± 3.46 mm Hg at 12 months. The survival rate at 12 months was 93%. This is one of the highest published success rates of any glaucoma procedure and is paired with minimal risks and complications.

### CONCLUSION

When ophthalmologists are selecting a MIGS procedure to incorporate into their armamentarium, it is important to choose one that is easy to learn, is low risk, is applicable to a broad population of patients with various pathologies and stages of disease, and has known long-term outcomes. The Trabectome stands apart from other options in that it can be used successfully across the spectrum of disease severity; it may be performed in phakic, pseudophakic, pediatric, and adult patients; and it has the longest proven track record of safety and efficacy of all MIGS procedures. Also worth noting is that no major modifications have been needed or made to the device since the first units were released.

1. Kaplowitz K, Bussell II, Honkanen R, et al. Review and meta-analysis of ab-interno trabeculectomy outcomes. *Br J Ophthalmol*. 2016;100(5):594-600.
2. Mosaed S. The first decade of global Trabectome outcomes. *Eur Ophthalmic Rev*. 2014;8(2):113-119.
3. Parikh HA, Bussell II, Schuman JS, et al. Coarsened exact matching of phaco-Trabectome to Trabectome in phakic patients: lack of additional pressure reduction from phacoemulsification. *PLoS One*. 2016;11(2):e0149384.
4. Ngai P, Kim G, Chak G, et al. Outcome of primary trabeculectomy ab interno (Trabectome) surgery in patients with steroid-induced glaucoma. *Medicine (Baltimore)*. 2016;95(50):e5383.
5. Wecker T, Neuberger M, Bryniok L, et al. Ab Interno trabeculectomy with the Trabectome as a valuable therapeutic option for failed filtering blebs. *J Glaucoma*. 2016;25(9):758-762.
6. Mosaed S, Chak G, Haider A, et al. Results of Trabectome surgery following failed glaucoma tube shunt implantation: cohort study. *Medicine*. 2015;94(30):e1045.
7. Jea SY, Mosaed S, Vold SD, Rhee DJ. Effect of a failed Trabectome on subsequent trabeculectomy. *J Glaucoma*. 2012;21(2):71-77.
8. Jordan JF, Wecker T, van Oterendorp C, et al. Trabectome surgery for primary and secondary open angle glaucomas. *Graefes Arch Clin Exp Ophthalmol*. 2013;251(12):2753-2760.
9. Maeda M, Watanabe M, Ichikawa K. Evaluation of Trabectome in open-angle glaucoma. *J Glaucoma*. 2013;22(3):205-208.

## The Kahook Dual Blade


BY MICHAEL D. GREENWOOD, MD



The trabecular meshwork (TM) is thought to be the main site of resistance to aqueous outflow. Incising or removing this tissue should lower this resistance, leading to improved IOP control. Previous methods of simply incising the TM with various instruments, including a microvitrectomy blade and the Trabectome (NeoMedix),

have provided suboptimal IOP lowering,<sup>1</sup> perhaps due to the incomplete removal of tissue or membrane formation across the remaining leaflets with a subsequent increase in IOP.

Rather than just incise the TM, the Kahook Dual Blade (KDB; New World Medical) removes tissue more



(courtesy New World Medical)

Figure. The KDB cuts the trabecular meshwork.

completely, making the surgically created cleft more resistant to closure and producing more sustained IOP control.<sup>2</sup> The sharp tip of the KDB allows it to pierce the TM

### TABLE 1. RESULTS FOR ALL EYES

	Preoperatively (n = 120)	Day 1 (n = 120)	Week 1 (n = 120)	Month 1 (n = 119)	Month 3 (n = 115)	Month 6 (n = 89)	Month 9 (n = 38)
Mean IOP, mm Hg	18.7 ± 6.7	13.0 ± 4.5	14.5 ± 6.6	14.2 ± 4.3	13.5 ± 3.9	12.9 ± 2.5	12.9 ± 4.2
Mean difference, mm Hg	Reference	-5.7 <sup>a</sup>	-4.2 <sup>a</sup>	-4.5 <sup>a</sup>	-5.2 <sup>a</sup>	-5.8 <sup>a</sup>	-5.8 <sup>a</sup>
Mean number medications	1.8 ± 1.3	0.7 ± 1.1	0.9 ± 1.2	0.9 ± 1.1	1.0 ± 1.1	1.0 ± 1.1	0.7 ± 0.8
Mean difference	Reference	-1.1 <sup>a</sup>	-0.9 <sup>a</sup>	-0.9 <sup>a</sup>	-0.8 <sup>a</sup>	-0.8 <sup>a</sup>	-1.1 <sup>a</sup>

Courtesy of New World Medical.

<sup>a</sup>Significant at an alpha of 0.05.

### TABLE 2. RESULTS FOR CATARACT SURGERY COMBINED WITH KAHOOK DUAL BLADE

	Preoperatively (n = 71)	Day 1 (n = 71)	Week 1 (n = 71)	Month 1 (n = 71)	Month 3 (n = 70)	Month 6 (n = 57)	Month 9 (n = 25)
Mean IOP, mm Hg	17.4 ± 5.2	13.3 ± 3.9	13.4 ± 4.8	13.6 ± 3.4	12.6 ± 2.6	12.7 ± 2.3	12.4 ± 3.4
Mean difference, mm Hg	Reference	-4.1 <sup>a</sup>	-4.0 <sup>a</sup>	-3.8 <sup>a</sup>	-4.8 <sup>a</sup>	-4.7 <sup>a</sup>	-5.0 <sup>a</sup>
Mean number medications	1.6 ± 1.3	0.4 ± 0.9	0.7 ± 1.1	0.7 ± 0.9	0.9 ± 1.1	0.9 ± 1.1	0.6 ± 0.8
Mean difference	Reference	-1.2 <sup>a</sup>	-0.9 <sup>a</sup>	-0.9 <sup>a</sup>	-0.7 <sup>a</sup>	-0.7 <sup>a</sup>	-1.0 <sup>a</sup>

Courtesy of New World Medical.

<sup>a</sup>Significant at an alpha of 0.05.

and be seated in Schlemm canal, along which the instrument can be easily guided. The ramp of the KDB elevates the TM and directs it toward the two blades, which cut the tissue and leave an intact strip of TM (Figure).

### THE PROCEDURE

The KDB procedure can be performed alone or simultaneously with cataract surgery through a single clear corneal incision, and it requires no additional materials or equipment. First, the surgeon places viscoelastic in the anterior chamber. The patient's head is rotated 30° to 45° away from the surgeon, and the microscope is tilted 30° to 45° toward him or her. The ophthalmologist then places a direct gonioscopy on the cornea and identifies the anatomical landmarks. Next, he or she inserts the KDB via the clear corneal incision and advances the device along Schlemm canal in a clockwise or counter-clockwise manner. The KDB is rotated 180°, the blade is advanced in the opposite direction to join the previously incised TM, and a free-floating TM strip is created. This strip is then easily removed by either a secondary instrument or the irrigation and aspiration handpiece (see *Watch It Now* on p. 32).

### RESULTS

The available data are encouraging. A recent multicenter, prospective, cohort study included 120 eyes that were treated with the KDB as a standalone procedure, combined with cataract surgery, or combined with other procedures.<sup>3</sup> The eyes in this study had glaucoma ranging in severity from mild to end-stage.

In all cases, the mean IOP at baseline was 18.7 ± 6.7 mm Hg, and 9 months postoperatively, the mean IOP was 12.9 ± 4.2 mm Hg ( $P < .001$ ), a reduction of 5.8 mm Hg or 31.0%. The mean number of hypotensive medications decreased from 1.8 ± 1.3 to 0.7 ± 0.8 at 9 months ( $P < .001$ ; Table 1).

Seventy-one eyes underwent cataract surgery combined with the KDB procedure. The baseline IOP in this group was 17.4 ± 5.2 mm Hg, and the mean number of hypotensive medications was 1.6 ± 1.3 preoperatively. Nine months postoperatively, the mean IOP was 12.4 ± 3.4 mm Hg, a decrease of 5.0 mm Hg or 28.7% ( $P < .001$ ), and the number of medications decreased to 0.6 ± 0.8 ( $P = .005$ ; Table 2).

The safety profile of the KDB is favorable. The most common observation is intraoperative blood reflux, which occurs with many microinvasive glaucoma procedures. It may result in retained blood in the anterior chamber 1 day postoperatively but usually clears by the 1-week visit.

1. Jea SY, Francis BA, Vakili, et al. Ab interno trabeculectomy versus trabeculotomy for open-angle glaucoma. *Ophthalmology*. 2012;119:36-42.

2. Seibold LK, SooHoo JR, Ammar DA, Kahook MY. Preclinical investigation of ab interno trabeculectomy using a novel dual-blade device. *Am J Ophthalmol*. 2013;155:524-529.e2.

3. Greenwood MD, Abdullah S, Radcliffe NM, et al. A novel dual blade device for goniotomy: 9 month follow up. Poster presented at: ASCRS/ASOA Congress & Symposium; May 5-9, 2017; Los Angeles, CA.

## Trab360

BY STEVEN R. SARKISIAN JR, MD



Good surgeons are always looking to “build a better mousetrap” to help their patients. Great surgeons find ways of doing so that are efficient and that have as few side effects and use the smallest incision possible. In this regard, the Trab360 (Sight Sciences; Figure 1) offers several advantages over traditional incisional glaucoma surgery and even other currently performed microinvasive glaucoma surgical procedures.

### RATIONALE

Traditional filtration surgery is fraught with complications, including bleb leaks, hypotony, suprachoroidal hemorrhages, blebitis, and endophthalmitis. The Trab360 procedure spares the conjunctiva and creates no bleb. If the patient requires a lower IOP postoperatively, filtration surgery is still an option.

Research has already demonstrated the safety and efficacy of trabeculotomy in the adult population.<sup>1-5</sup> Traditionally, the procedure has been performed externally, either for 180° or 360°.<sup>1</sup> The Trab360 allows me to unroof 360° of the trabecular meshwork. Other methods of ab interno trabeculotomy can have downsides such as only doing a partial trabeculotomy,<sup>2,3</sup> the capital cost of equipment,<sup>3</sup> and the need for a power source.<sup>3</sup>

### SURGICAL PROCEDURE

I create a temporal incision with a keratome (the same 1.8-mm diamond knife I use for cataract surgery), after which I instill lidocaine and a cohesive viscoelastic on the cornea and in the anterior chamber. As during other angle procedures, I tilt the patient's head and the microscope to give myself the best view of the angle.

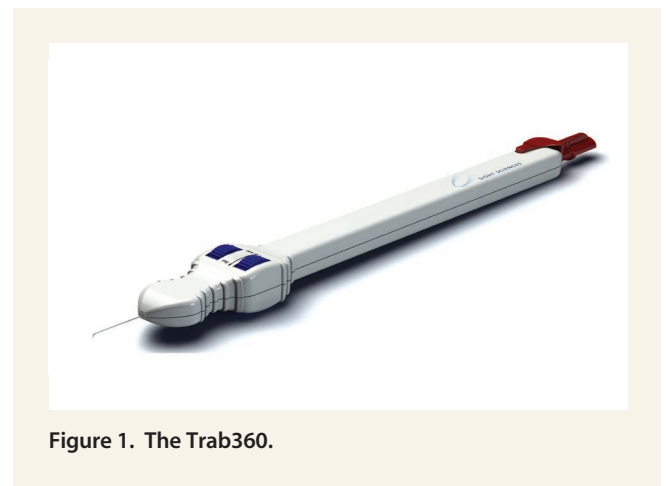


Figure 1. The Trab360.


**WATCH IT NOW**

John Berdahl, MD, incises the trabecular meshwork with the Kahook Dual Blade.



In this episode of Glaucoma Today Journal Club, Steven Sarkisian Jr, MD, explains how to perform ab interno trabeculotomy with the Trab360.



In this episode of Ophthalmology Insider, Dr. Sarkisian joins Keith Barton, MD, and moderator Mark Kontos, MD, to discuss the future of glaucoma therapy.

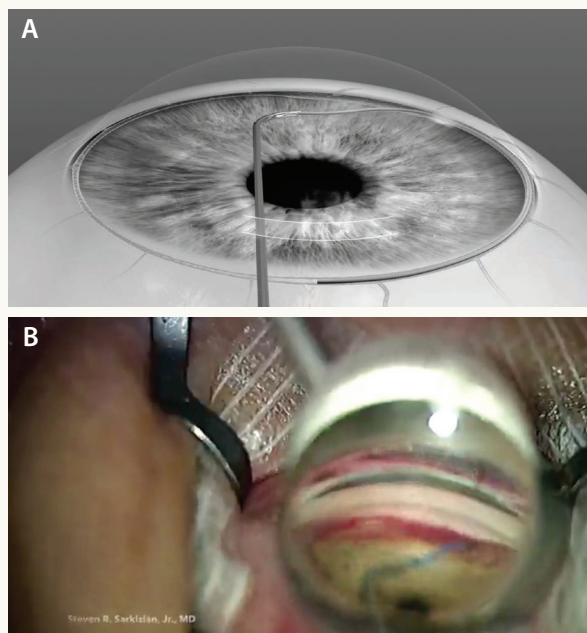


Figure 2. Animation of the procedure (A). Intraoperative view (B).

Using a surgical gonioprism to view the angle, I incise the trabecular meshwork with the tip of the Trab360 and advance the probe into Schlemm canal. I like to unroof about 1 clock hour of the trabecular meshwork with the device's tip and then place it flush with the back wall of the canal before advancing the probe. After it passes 180°, I use a push-pull motion to unroof the trabecular meshwork to achieve a 180° trabeculotomy. I instill a cohesive viscoelastic to tamponade bleeding and reverse the device to perform the same procedure on the other 180° of the angle. I then remove the viscoelastic from the eye with irrigation and aspiration using balanced salt solution on a cannula (Figure 2; see *Watch It Now*).

## RESULTS

Chin and colleagues demonstrated that a 360° trabeculotomy lowers IOP more than a partial trabeculotomy.<sup>1</sup> Based on my initial 8- to 12-month results,<sup>4</sup> my patients' postoperative IOPs are similar to what Chin et al<sup>1</sup> and Grover et al<sup>5</sup> have reported for 360° trabeculotomy. There does not seem to be a difference between ab interno and ab externo techniques in terms of IOP lowering.

My patients' mean IOP measured  $19.8 \pm 6.4$  mm Hg preoperatively and  $13.5 \pm 4$  mm Hg at final follow-up. Their average number of medications dropped from  $1.1 \pm 1.2$  before surgery to  $0.2 \pm 0.5$  at final follow-up. I am currently collecting long-term, 3-year data. Postoperative complications have been the same as reported with all of the other



trabeculotomy procedures—primarily transient hyphema that usually resolves within a few days after surgery.


## CONCLUSION

The Trab360 is a novel device that can be used to perform a circumferential trabeculotomy. Initial results show it to be safe and efficacious, but long-term follow-up of more patients is needed. Research thus far shows ab interno trabeculotomy to be an important and less invasive method for lowering IOP than a similar procedure with a suture, blade, cautery, or catheter.<sup>1,5</sup> Moreover, surgery with the Trab360 need not be combined with cataract extraction to be effective or on label. It is my opinion that this device is a more complete and more efficient technique than the other methods of ab interno trabeculotomy currently available.<sup>2-5</sup>

1. Seibold LK, SooHoo JR, Ammar DA, Kahook MY. Preclinical investigation of ab interno trabeculotomy using a novel dual-blade device. *Am J Ophthalmol*. 2013;155(3):524-529 e522.
2. Vold SD. Ab interno trabeculotomy with the Trabectome system: what does the data tell us? *Int Ophthalmol Clin*. 2011;51(3):65-81.
3. Chin S, Nitta T, Shinmei Y, et al. Reduction of intraocular pressure using a modified 360-degree suture trabeculotomy technique in primary and secondary open-angle glaucoma: a pilot study. *J Glaucoma*. 2012;21(6):401-407.
4. Grover DS, Godfrey DG, Smith O, et al. Gonioscopy-assisted transluminal trabeculotomy, ab interno trabeculotomy: technique report and preliminary results. *Ophthalmology*. 2014;121(4):855-861.
5. Sarkisian SR, Allen E, Ding K, et al. New way for ab interno trabeculotomy: initial results. Poster presented at: ASCRS/ASOA Symposium & Congress; April 17, 2015; San Diego, CA.

## Excimer Laser Trabeculostomy

BY MICHAEL BERLIN, MD, MS; VIGAN ROKA, MD; MICHAEL RIGGS; AND ULRICH GIERS, MD



Unlike argon and selective laser trabeculoplasty, excimer laser trabeculostomy (ELT; not FDA approved) precisely excises tissue without causing thermal injury to or scarring of the surrounding tissue.<sup>1-3</sup> This procedure uses a XeCl (308-nm) excimer laser coupled to an intraocular fiber optic delivery system to create long-term anatomic openings that connect the anterior chamber directly to Schlemm canal.

Unlike argon and selective laser trabeculoplasty, excimer laser trabeculostomy (ELT; not FDA approved) precisely excises tissue without causing thermal injury to or scarring of the surrounding tissue.<sup>1-3</sup> This procedure uses a XeCl (308-nm) excimer laser coupled to an intraocular fiber optic delivery system to create long-term anatomic openings that connect the anterior chamber directly to Schlemm canal.

## THE PROCEDURE

ELT is performed as an outpatient procedure under topical or peribulbar anesthesia (see *Watch It Now*). The surgeon creates a paracentesis and then stabilizes the anterior chamber by injecting a viscoelastic. A fiber optic probe is then advanced through the paracentesis, across the anterior chamber, to contact the trabecular meshwork. An optical fiber is required to deliver the 308-nm UV laser radiation energy to circumvent corneal

and aqueous humor absorption of this energy. The surgeon visualizes the placement by gonioscopy or via an endoscope. Adequate pulsed photoablative energy is then applied to create the channels (Figure).

In current protocols, the surgeon creates 10 channels in one or two inferior quadrants. A small amount of blood reflux from Schlemm canal confirms each channel's patency. The surgeon then removes the probe from the eye and exchanges the viscoelastic for balanced salt solution.

Postoperatively, patients administer topical antibiotic and steroid drops for 1 to 2 weeks. The IOP decreases immediately after surgery. The postoperative care of patients undergoing ELT in the European Union generally consists of two to three visits over the course of 1 to 2 months.

## CLINICAL RESULTS

Numerous clinical studies have demonstrated ELT's ability to achieve a long-term reduction in IOP while also decreasing and often eliminating the need for glaucoma medications in phakic and in pseudophakic patients with open-angle glaucoma (OAG) or ocular hypertension (OHT), whether the procedure is performed alone or in combination with cataract surgery. In a study presented in 2013, 46 phakic eyes with medically treated OAG or OHT underwent ELT, and 37 eyes with medically treated OAG or OHT underwent ELT combined with phacoemulsification.<sup>4,5</sup> The primary outcome measures were mean change in IOP (without washout) and the number of glaucoma medications from baseline. Secondary outcome measures included change in visual acuity (BCVA), surgical complications, and adverse events.

Eight years postoperatively, the mean IOP in the ELT-alone group had decreased 29.7% from a preoperative level of 22.9

## WATCH IT NOW

Michael Berlin, MD, MS, demonstrates excimer laser trabeculostomy.



[bit.ly/ELT0317](http://bit.ly/ELT0317)

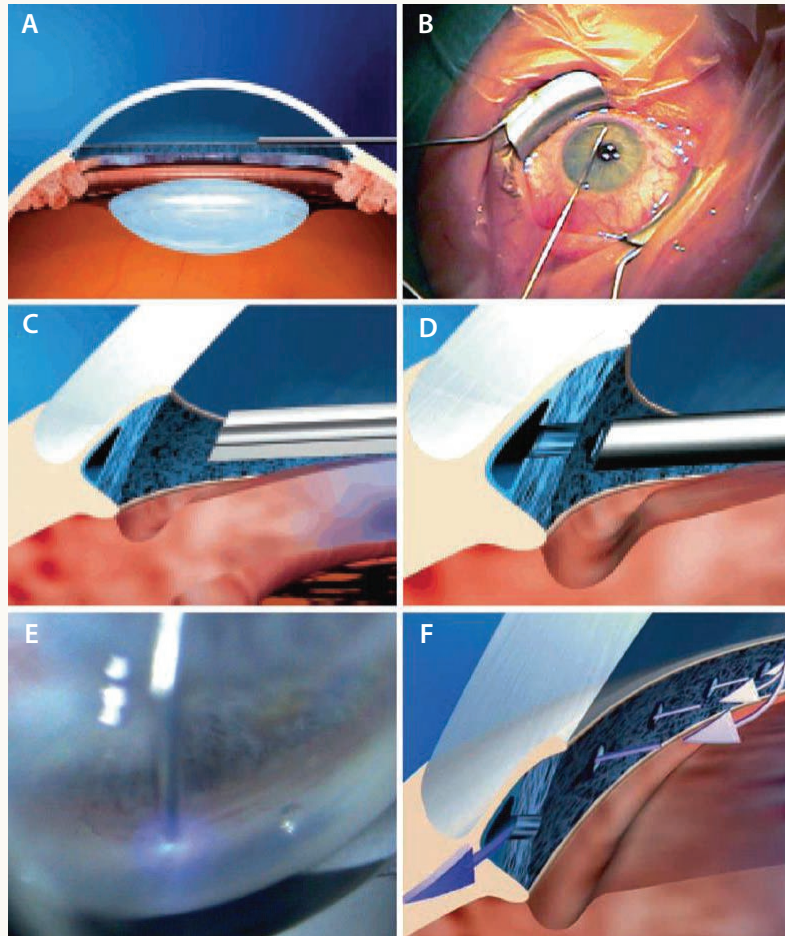


Figure. Paracentesis, viscoelastic, and probe across the anterior chamber during the ELT procedure (A). Probe across the chamber (B). Probe contacts the trabecular meshwork. Laser pulses ablate tissue into gas (C). Ten openings into Schlemm canal are created (D). Laser pulses excise the trabecular meshwork (E). Patent trabeculostomies enable outflow into Schlemm canal (F).

$\pm 5.4$  to  $16.1 \pm 3.4$  mm Hg ( $P < .001$ ). In the combined group, the mean IOP decreased 43.4% from a preoperative level of  $25.1 \pm 6.1$  to  $14.2 \pm 3.1$  mm Hg ( $P < .001$ ). The number of glaucoma medications for ELT alone changed from  $1.6 \pm 0.7$  to  $1.2 \pm 1.2$  ( $P < .152$ ) and, for ELT combined with phacoemulsification, from  $1.3 \pm 0.7$  to  $1.8 \pm 0.8$  ( $P < .087$ ).

### PNEUMATIC CANALOPLASTY

An additional advantage of ELT is that it enables pneumatic canaloplasty. During ELT, both coaxial endoscopic views and gonioscopic views reveal the expansion of gas bubbles seen coming through the adjacent channel when Schlemm canal is entered at each subsequent ELT site. The phenomenon results from the photoablative conversion of trabecular meshwork tissue into gas. These bubbles are presumed to confirm patency and continuity of fluid flow into and through Schlemm canal. The pressure of this gas may also dilate the canal and the adjacent collector channels to improve aqueous outflow.

### CONCLUSION

ELT has been approved for use in the European Union for more than a decade. Unlike alternative microinvasive trabecular meshwork glaucoma surgeries to reduce outflow obstruction, ELT does not require the implantation of foreign bodies or cause coagulative damage. Unlike argon and selective laser trabeculoplasty, which may be performed in an office setting but do not create anatomic outflow channels, ELT is an intraocular procedure performed in a surgical suite. As with other microinvasive glaucoma surgical procedures, the initial learning curve is somewhat steep, but ELT devices that require no gonioscopy or endoscopy are in development.



## LISTEN UP

In this episode of the podcast *Ophthalmology off the Grid*, Ike Ahmed, MD, and John Berdahl, MD, discuss the evolution of microinvasive glaucoma surgery with moderator Gary Wörtz, MD.

[bit.ly/herndon0317](http://bit.ly/herndon0317)

- Berlin MS, Rajacich G, Duffy M. Excimer laser photoablation in glaucoma filtering surgery. *Am J Ophthalmol*. 1987;103:713-714.
- Berlin MS, Latina MA, Amital A. New developments in glaucoma laser surgical procedures. In: Stamper RL, ed. *Ophthalmology Clinics of North America*. Philadelphia: W. B. Saunders; 1998;11:187-189.
- Berlin MS, Ahn R. Laser sclerostomy: the state of the art. In: Stamper RL, ed. *Ophthalmology Clinics of North America*. Philadelphia: W. B. Saunders; 1993:415-424.
- Stodtmeister R, Kleinerberg L, Berlin M, et al. Excimer laser trabeculostomy: five year post-op observations. *Invest Ophthalmol Vis Sci*. 2013;54:2141.
- Berlin MS, Giers U, Kleinerberg L, et al. Intraocular pressure-lowering efficacy of combined excimer-laser-trabeculostomy and phacoemulsification in glaucoma patients consistent over 5 years. Presented at: ASCRS/ASOA Congress and Symposium; April 19-23, 2013; San Francisco, CA.

## Supraciliary Space

## Supraciliary Microstents

BY STEVEN D. VOLD, MD



The rationale for supraciliary outflow as a target for glaucoma treatment has been debated for more than a century. The supraciliary space is delineated by the internal surface of the sclera and the external surface of the choroid. The point of highest resistance is the ciliary body. Physiologically, it is a potential space held captive by a constantly maintained negative hydrostatic pressure. In

1906, surgeons placed horse hair in the supraciliary space to enhance uveoscleral outflow. In 1912, they used silk thread for the same purpose. Ophthalmic surgeons used intraocular instrumentation to induce cyclodialysis clefts to lower IOP. Unfortunately, these techniques were fraught with numerous complications, including bleeding, hypotony, sudden IOP spikes, and frequent failure.<sup>1,2</sup>

Considering the dismal past of surgical procedures involving the supraciliary space, why are newer devices a viable option for glaucoma therapy?

## DESIGNING THE IDEAL SUPRACILIARY DEVICE

In recent years, doctors and industry have sought to unlock the secrets of the supraciliary space as a means of improving glaucoma management. The FDA approved the CyPass Micro-Stent (Alcon) in 2016,<sup>3,4</sup> and the iStent Supra (Glaukos; Figure) and Miniject (iStar) are in clinical trials. In addition, iStar is exploring implantation of an IOP sensor with the company's suprachoroidal device.

Nearly a decade of work in the supraciliary space and with these devices has taught me a few critical lessons about the design of supraciliary devices.

**No. 1. An ab interno technique is almost certainly preferable to ab externo implantation of a supraciliary device.** One reason is that implantation via an ab interno approach is less traumatic. Direct visualization of the angle allows surgeons to avoid angle vessels and to place the device between the scleral and choroidal vasculature without inducing significant bleeding. Furthermore, the proximal end of the device can be more easily positioned properly between Schwalbe's line (where Descemet membrane ends) and the pigmented trabecular meshwork.

**No. 2. The supraciliary device must be made of an anti-inflammatory material.** Gold is less than an ideal material for supraciliary devices, as evidenced by the dense fibrotic membranes that frequently developed over time

around the Solx Gold Shunt (Solx; not FDA approved). Materials such as polyimide appear to be less inflammatory in nature, with many patients achieving a sustained reduction in IOP for nearly a decade after microstent placement.

**No. 3. Design appears to be important.** Although the ideal characteristics of a supraciliary microstent have yet to be fully elucidated, the configuration of the device, the size of the supraciliary lake after the implant's placement, the potential advantage of using adjunctive antifibrotic medications inside the device at implantation, and the potential use of these devices as a means of delivering pharmaceutical products to the retina via the choroidal vasculature seem to hold promise. Already, the

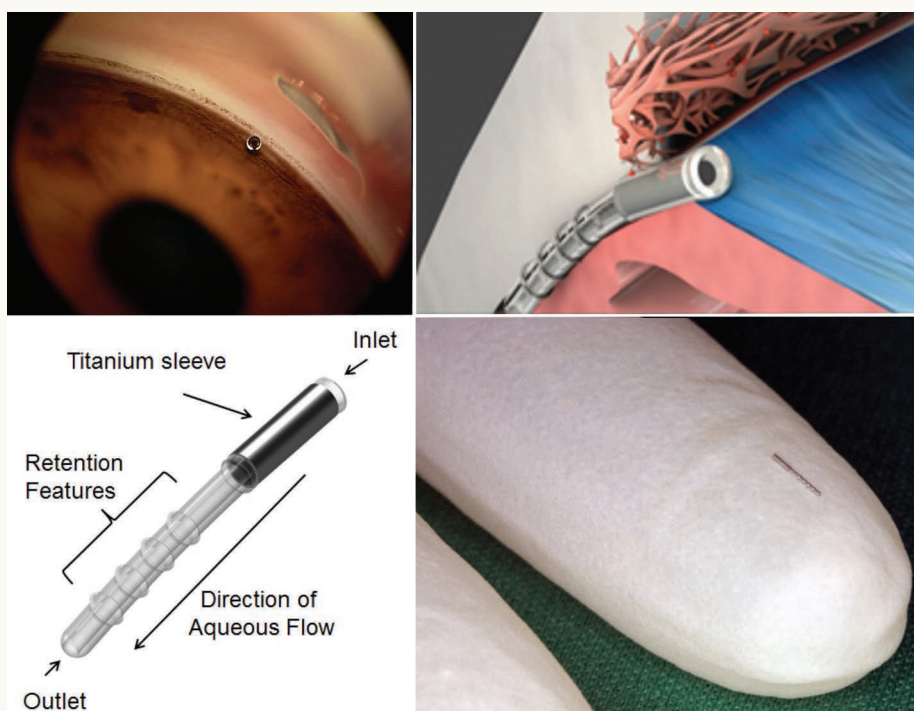


Figure. The iStent Supra.

injection of viscoelastic through the CyPass Micro-Stent is being evaluated.

### PERIOPERATIVE CONSIDERATIONS

Proper surgical technique and perioperative care seem to be critical to optimizing outcomes with supraciliary microstents. I have three observations in this area.

**No. 1. Combining the implantation of a supraciliary microstent with cataract surgery may maximize success.** Removing the cataract deepens the anterior chamber and thus facilitates the implantation of a supraciliary device. I find that hyperinflating the anterior chamber with either a dispersive or a cohesive viscoelastic enhances safety during the microstent's placement. The proximal end of the device should be positioned between Schwalbe's line and the pigmented trabecular meshwork. Placing a microstent anterior to Schwalbe's line increases the risk of late corneal endothelial failure. Devices inserted more posterior than the pigmented trabecular meshwork may become occluded by peripheral iris tissue and fail. Patients with mild open-angle glaucoma may be candidates for a presbyopia-correcting IOL, thus maximizing their refractive outcomes.

**No. 2. Topical glaucoma medication should be discontinued after supraciliary microstent surgery.** In clinical trials, it was common for glaucoma medical therapy to stop approximately 1 month before surgery. In my experience, cessation helps to prevent postoperative hypotony as well as potential choroidal effusion and hypotony maculopathy due, at least in part, to the IOP-lowering effect of topical glaucoma medications in the early postoperative period. If IOP begins to rise postoperatively, it may be advisable to prescribe a prostaglandin analogue rather than an aqueous suppressant in order to maintain the aqueous lake within the supraciliary space. Uveoscleral outflow must be encouraged to ensure successful long-term outcomes with this type of microinvasive glaucoma surgery (MIGS). Further clinical study is required to confirm or contradict this hypothesis.

**No. 3. Postoperative care is comparable to that after cataract surgery alone.** Patients are typically encouraged to administer prednisolone acetate 1% or difluprednate three to four times a day for 4 to 6 weeks postoperatively. Patients with more ocular inflammation than usual, perhaps related to retained cortex, may continue topical steroid therapy for a longer period of time. Loteprednol is likely a reasonable alternative to prednisolone acetate 1% or difluprednate. Many surgeons also routinely prescribe a topical nonsteroidal anti-inflammatory drug to prevent postoperative pain and cystoid macular edema.

### CONCLUSION

Supraciliary surgical options enhance uveoscleral outflow and may potentially lower IOP more than trabecular bypass procedures, especially in patients who have a compromised

collector system.<sup>4</sup> With proper surgical technique and thoughtful perioperative care, these MIGS devices have promising safety and efficacy profiles for patients with mild to moderate open-angle glaucoma. At this time, understanding of the supraciliary space, the ideal supraciliary device profile, and perioperative care remains in its infancy. Recent advances are encouraging, however, and continued progress will likely allow surgeons and more of their patients to avoid the risks of filtration blebs in the future.

1. Jordan JF, Dietlein TS, Dinslage S, et al. Cycloidalysis ab interno as a surgical approach to intractable glaucoma. *Graefes Arch Clin Exp Ophthalmol.* 2007;245:1071-1076.

2. Emi K, Pederson JE, Toris CB. Hydrostatic pressure of the suprachoroidal space. *Invest Ophthalmol Vis Sci.* 1989;30:233-238.

3. Hoeh H, Ahmed II, Grisanti S, et al. Early postoperative safety and surgical outcomes after implantation of a suprachoroidal micro-stent for the treatment of open-angle glaucoma concomitant with cataract surgery. *J Cataract Refract Surg.* 2013;39:431-437.

4. Vold S, Ahmed II, Craven ER, et al; CyPass Study Group. Two-year COMPASS Trial results: supraciliary microstenting with phacoemulsification in patients with open-angle glaucoma and cataracts. *Ophthalmology.* 2016;123(10):2103-2112.

## CyPass Micro-Stent

BY MARC TÖTEBERG-HARMS, MD, FEBO



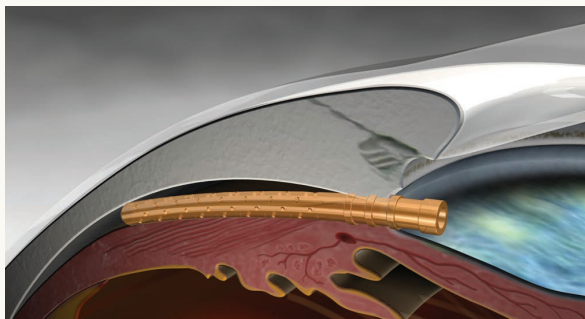
Most microinvasive glaucoma surgery (MIGS) procedures target trabecular (conventional) outflow into Schlemm canal but cannot completely overcome the problem of impaired subsequent outflow obstruction (ie, collector channels, deep venous plexus, and episcleral veins). The CyPass Micro-Stent (Alcon; Figure 1) is the first

FDA-approved MIGS procedure that targets alternative uveoscleral outflow. This system is independent from trabecular outflow, and a negative pressure gradient between the anterior chamber and the supraciliary space is the principle behind this outflow route. The FDA approved the CyPass for implantation through a single clear corneal incision in combination with phacoemulsification cataract surgery plus IOL implantation.

### THE PROCEDURE

The CyPass procedure is probably one of the easiest MIGS procedures to learn. Because implantation of the device in the supraciliary space is intuitive, ophthalmologists who are already familiar with angle surgery should be able to incorporate the CyPass into their practice without much difficulty. For those unfamiliar with angle surgery, the greatest challenge is likely visualization of the anterior chamber angle with a gonioscope at the microscope in the operating theater. Miosis is achieved with acetylcholine chloride (10 mg/mL). A crucial step in visualization of the anterior chamber angle is turning the patient's head approximately 45° away from the surgeon and tilting the microscope by approximately

(courtesy of Alcon.)



**Figure 1.** Schematic view of the CyPass Micro-Stent. Note the fluid lake at the end of and around the device.

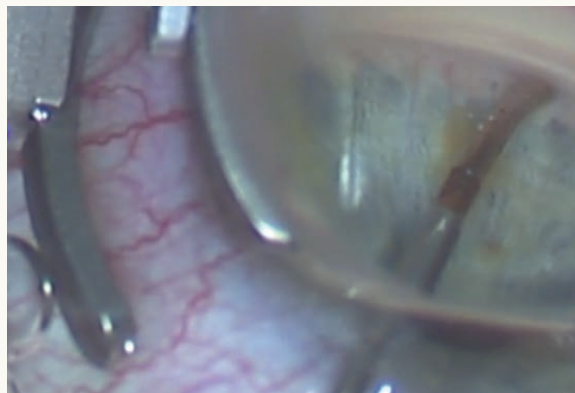
the same degree in the opposite direction for a temporal approach. A gonioscopic lens with a Thornton ring (eg, Volk Transcend TVG Surgical Goniolens [Volk Optical]) can help the surgeon stabilize and move the eye into the desired direction.

The ophthalmologist introduces the microstent sidewise into the anterior chamber through a corneal incision into the anterior chamber (filled with viscoelastic), turns the implant 90° to align its curvature with that of the sclera, and advances the device toward the opposite side of the eye. He or she should aim directly below the scleral spur (Figure 2). If the guide wire is too close to the iris, the surgeon will observe this tissue moving; if the guide wire is too far away from the iris route, he or she will encounter resistance during implantation. In the correct location, the CyPass glides into the supraciliary space with little to no resistance. The device should be advanced in the supraciliary space but not so far that none of the retention rings is visible in the anterior chamber (Figure 3). The number of rings visualized may vary, depending on the depth of the angle. Ideally, the proximal end of the microstent should be positioned between the pigmented trabecular meshwork and Schwalbe's line. The guide wire is retracted, and the viscoelastic is washed out using irrigation and aspiration (see *Watch It Now* on p. 38).

Patients follow a standard postcataract regimen of topical medication, and glaucoma medication may be discontinued and restarted as needed.

## RESULTS


The multicenter, interventional, randomized COMPASS clinical trial included 2 years of follow-up.<sup>1</sup> All patients had primary open-angle glaucoma and a mean diurnal unmedicated IOP between 21 and 33 mm Hg. After cataract surgery, subjects were randomized in a 1:3 ratio to either cataract surgery with IOL implantation alone (control group, n = 131) or in conjunction with CyPass implantation (microstent group, n = 374). Both groups had similar baseline



**Figure 2.** Gonioscopic view through the operating microscope. Approximately one-third of the microstent has been implanted into the supraciliary space.

characteristics. Sixty percent of control eyes and 77% of eyes that received the CyPass achieved a reduction in unmedicated IOP of at least 20% at 2 years compared to baseline. IOP decreased by 7.4 mm Hg in the microstent group versus 5.4 mm Hg in the control group ( $P < .001$ ), and 61% of the microstent group and 44% of the control group had an unmedicated IOP between 6 and 18 mm Hg. In addition, 59% of the control subjects versus 85% of microstent subjects were free of medication postoperatively. There were no vision-threatening adverse events related to the microstent, and more than 98% of eyes achieved 20/40 or better BCVA.

In the microstent group, 2.9% of eyes had transient hypotony (IOP  $\leq$  5 mm Hg); all cases resolved within the first

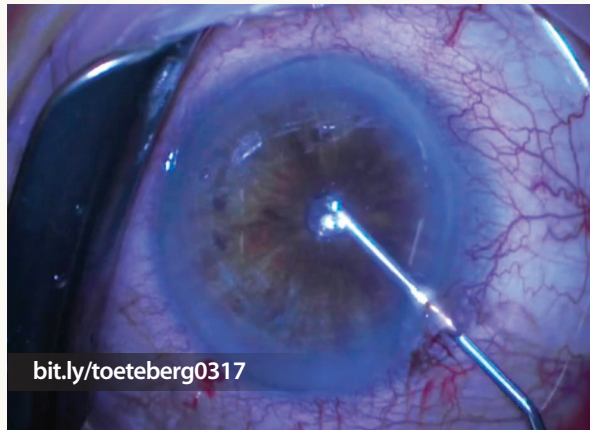


**Figure 3.** Gonioscopic view 1 week postoperatively. One retention ring is visible in the anterior chamber. The microstent has no contact with the endothelium, and no iris incarceration or contact is evident. A localized cyclodialysis cleft is visible directly around the device.



## WATCH IT NOW

Marc Töteberg-Harms, MD, FEBO, demonstrates implantation of the CyPass Micro-Stent.



2 weeks. Whereas hyphema often occurs after trabeculectomy (7.6% in the Tube Versus Trabeculectomy [TVT] study)<sup>2</sup> and with MIGS procedures that bypass the trabecular meshwork (eg, up to 100% after ab interno trabeculectomy with the Trabectome [NeoMedix]),<sup>3</sup> this complication was observed in only 2.7% of eyes that received the CyPass.

1. Vold S, Ahmed II, Craven ER, et al. Two-year COMPASS Trial results: supraciliary microstenting with phacoemulsification in patients with open-angle glaucoma and cataracts. *Ophthalmology*. 2016;123:2103-2112.
2. Gedde SJ, Herndon LW, Brandt JD, et al; Tube Versus Trabeculectomy Study Group. Postoperative complications in the Tube Versus Trabeculectomy (TVT) study during five years of follow-up. *Am J Ophthalmol*. 2012;153(5):804-814.
3. Jea SY, Francis BA, Vakili, et al. Ab interno trabeculectomy versus trabeculectomy for open-angle glaucoma. *Ophthalmology*. 2012;119(1):36-42.

### Subconjunctival Space

## Xen Glaucoma Treatment System

BY ERIK L. MERTENS, MD, FEBOPHTH



Microinvasive glaucoma surgery (MIGS) is safer and less invasive than traditional surgery but reduces IOP less dramatically.<sup>1,2</sup> MIGS is characterized by minimal external dissection, a short operating time, a good safety profile, and patients' rapid postoperative recovery.

The procedures are logically classified by their target for aqueous outflow: Schlemm canal, the subconjunctival space, or the supraciliary space. The Xen Glaucoma Treatment System (Allergan) aims to lower IOP by creating a subconjunctival drainage pathway.

### THE SYSTEM

In November 2016, the FDA approved the Xen Glaucoma Treatment System, which consists of the Xen45 Gel Stent and Xen Injector. The implant is a hydrophilic tube composed of a porcine gelatin cross-linked with glutaraldehyde.<sup>3</sup> The biocompatibility properties of gelatin are well established and do not cause any foreign body reaction. The optimal diameter of the tube is based on the laminar flow, as calculated using the Hagen-Poiseuille equation, which predicts that flow depends on tube length, inner diameter, and flow viscosity. In an eye with healthy, mobile conjunctiva, not much outflow resistance comes from the subconjunctival space. To avoid a drop in IOP after surgery, all outflow resistance must come from the tube itself, which is approximately 6 mm long and has an inner diameter of about 45  $\mu$ m. Flow is 0.02 mL/sec or 1.2 mL/min (at a pressure gradient of 5 mm Hg), thus providing approximately 6 to 8 mm Hg of flow resistance, which essentially eliminates hypotony.<sup>2</sup>

### THE PROCEDURE

Surgery is usually performed under a sub-Tenon block, which achieves effective intraoperative akinesia and analgesia without the possibly sight-threatening complications of retrobulbar injections. Typically, surgeons implant the stent after cataract extraction and IOL placement but before removing the viscoelastic, but Xen surgery can also easily be performed as a solo procedure.

Ab interno glaucoma surgery requires excellent gonioscopic visualization for the ophthalmologist to ensure that the angle is open prior to delivering the implant. The preferred placement of the stent is in the superior-nasal quadrant. The surgeon measures 3 mm from the limbus and places two dye marks in the target area. He or she makes the 1.8-mm main incision opposite the target area and creates a 1-mm sideport 60° to 90° away from the main incision.

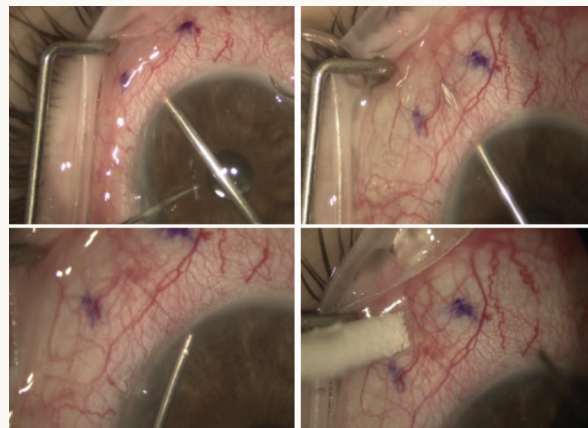


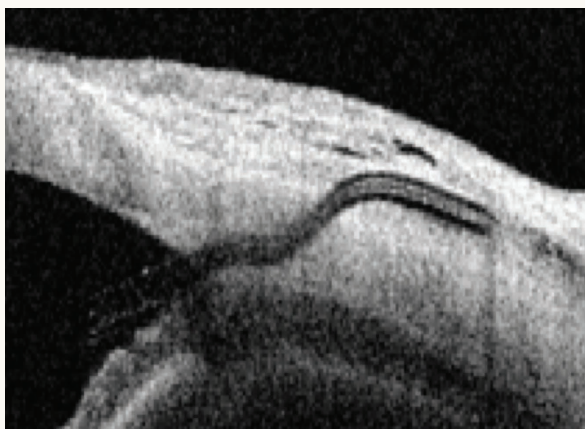Figure 1. The needle tip exits the sclera  $\pm$ 3 mm from the limbus before delivery of the Xen45 Gel Stent.

“ Successful glaucoma surgery must safely provide long-term IOP reduction.”  
—Erik L. Mertens, MD, FEBOPhth

Then, the surgeon injects a high-viscosity viscoelastic into the anterior chamber (Figure 1).

To lower the incidence of fibrosis, 0.1 mL of 0.02% mitomycin C may be delivered central to the superior-nasal quadrant and massaged with a Weck-Cel sponge (BVI) to the delivery area. The injector is then inserted through the main incision under gonioscopic control, and the goal is to enter high in the angle. The needle tip needs to exit the sclera  $3 \pm 0.5$  mm from the limbus. The surgeon then rotates the bevel  $90^\circ$  toward the 12-o'clock position. With slight forward bias applied to the injector, the stent is delivered. If the correct position is achieved, the injector can be retracted without lateral movement. The surgeon removes the viscoelastic with irrigation and aspiration, during which a distinct, responsive bleb should form, and he or she checks the incisions for leakage.

After implantation, the stent softens in 1 to 2 minutes. In its natural hydrated state, the device is straight, but it conforms to the shape of surrounding tissue. This flexibility is important to avoiding migration and potential erosion (Figure 2).<sup>2</sup>



**Figure 2.** Ultrasound biomicroscopy shows the intrascleral course from the anterior chamber until the subconjunctival space.

## WATCH IT NOW

In this episode of Glaucoma Today Journal Club, Arsham Sheybani, MD, describes his experience with the Xen45 Gel Stent.



### RESULTS

Enrollment in the European phase 4 APEX trial has closed, with 216 patients included who have mild to moderate primary open-angle glaucoma and no history of intraocular surgery. The study has two arms: patients receive the Xen45 either as a standalone procedure or in combination with cataract surgery. The first 42 patients who have reached the 12-month visit achieved a mean reduction in IOP of  $-8.6$  mm Hg ( $-40\%$ ) from the medicated preoperative level ( $21.4$ - $12.8$  mm Hg) and a simultaneous mean decrease of  $-1.9$  ( $-73\%$ ) in antiglaucoma medication ( $2.6$ - $0.7$  medications; data on file with Johnson & Johnson Vision).

### CONCLUSION

Successful glaucoma surgery must safely provide long-term IOP reduction. In my opinion, subconjunctival drainage of aqueous is the most effective method of achieving sustained lowering of IOP. The combination of an ab interno approach to minimize tissue trauma with a stable, nondegrading, flexible, gelatin stent protects the conjunctiva-Tenon tissue to enhance the surgical outcomes of filtering surgery. The length, lumen diameter, and tube rigidity of the Xen45 Gel Stent restrict flow and avoid hypotony.<sup>2</sup>

1. Kerr NM, Wang J, Barton K. Minimally invasive glaucoma surgery as primary stand-alone surgery for glaucoma [published online ahead of print December 8, 2016]. *Clin Exp Ophthalmol*. doi:10.1111/ceo.12888.

2. Lewis RA. Ab interno approach to the subconjunctival space using a collagen glaucoma stent. *J Cataract Refract Surg*. 2014;40(8):1301-1306.

3. Condon GP, Moser MR. Minimizing the invasiveness of traditional trabeculectomy surgery. *J Cataract Refract Surg*. 2014;40(8):1307-1312.

## InnFocus MicroShunt

BY HOWARD BARNEBEY, MD



The InnFocus MicroShunt (Santen; not FDA approved) was developed in response to the limitations and challenges of trabeculectomy and glaucoma drainage device procedures. With trabeculectomy, the main problem is the unpredictability of postoperative healing, which presents complications such as conjunctival and Tenon wound

fibrosis as well as hypotony, inflammation, shallow chambers, and choroidal detachments. With glaucoma drainage devices, the most common challenges are excessive flow early in the healing process and, late in the postoperative phase, excessive Tenon fibrosis over the silicone plate. In addition, these large drainage devices often require a patch graft to prevent erosion through the conjunctiva.

### THE DEVICE

The InnFocus MicroShunt is a minimally invasive, plateless glaucoma drainage microshunt made from an inert biomaterial called SIBS (polystyrene-*block*-isobutylene-*block*-styrene; Figure 1). The device shunts aqueous humor from the anterior chamber to the sub-Tenon capsular space (Figure 2). Originally developed as a nonreactive coating material for cardiovascular stents, SIBS has more than a 15-year safety profile in humans and was hypothesized to be an ideal material to address the concerns of glaucoma outflow surgery.<sup>1</sup>

### THE PROCEDURE

There are few surgical challenges with the MicroShunt, and the learning curve is quick and relatively flat. In brief, similar to a trabeculectomy, creation of a fornix-based conjunctival pocket and the application of mitomycin C (MMC) are important. The crucial step of the procedure (unique and easy to master) is the creation of the scleral tunnel, which has been standardized with a specially

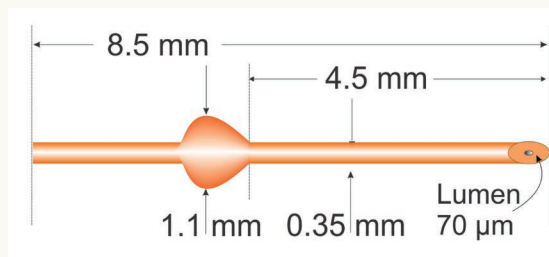


Figure 1. The InnFocus MicroShunt is made from SIBS.

designed tunneling blade. The surgeon inserts the blade 3 mm posterior to the surgical limbus and advances until the instrument's tip is visible in the anterior chamber. The implant is fed into the tunnel until the 1.1-mm-wide supporting fins (4.5 mm distal from the entrance) advance into the distal end of the 1-mm-wide entrance to the tunnel. Flow usually starts immediately and is confirmed with moistening of a dry Weck-Cel sponge (BVI). Rarely, the MicroShunt needs to be primed with balanced salt solution injected over its distal end via a 23-gauge irrigating cannula (Figure 3).

At the conclusion of surgery, the ophthalmologist advances the overlying Tenon and conjunctival tissues to the surgical limbus with care to ensure that the Tenon tissue has not retracted over the device. Both tissues are reapproximated with traditional 9-0 or 10-0 sutures (Figure 4).

### ADVANTAGES AND DIFFERENCES

The MicroShunt procedure is straightforward, requiring no manipulation of the anterior chamber, no special equipment, no scleral dissection, and no sclerectomy or iridectomy. Hemostasis is readily controlled with bipolar cautery. If the MicroShunt is not placed correctly, it can be simply pulled out and repositioned.

The implant's unique biomechanical properties and material are well tolerated in the eye and minimize clinically significant fibrotic capsule formation or tissue response at the distal end of the shunt.<sup>2</sup> Another advantage of this device is the prevention of chronic hypotony with the 8.1-mm-long, 70- $\mu$ m lumen. In addition, the soft nature of the SIBS material and its ability to take on the shape of the globe eliminate erosion and the need for a patch graft. According to Santen, erosion of the device through the conjunctiva has not been observed to date with any of the more than 1,000 devices implanted over the past decade.

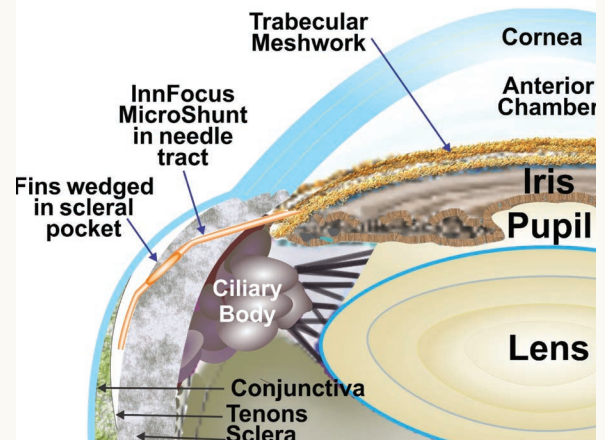
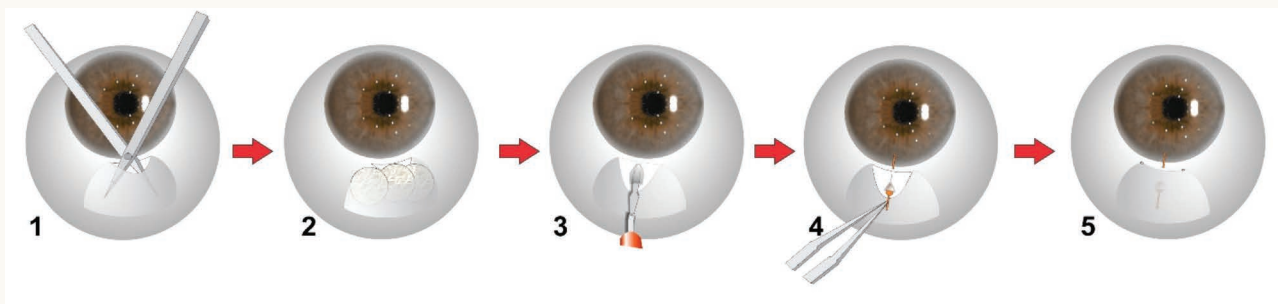


Figure 2. Positioning of the device in the eye.





**Figure 3.** Implantation procedure. The surgeon dissects a fornix-based subconjunctival/Tenon pouch deep to the equator and 90° to 120° wide (1). After ensuring the sclera is free of blood, the surgeon inserts three LASIK shields soaked in MMC into the pouch, leaves them for 2 to 3 minutes, removes the sponges, and rinses the area well with buffered saline (2). Next, the surgeon inserts the double-stepped knife under the limbus and into the anterior chamber to form a knife tract and pocket (3). The MicroShunt is advanced through the pocket and knife tract into the anterior chamber, and the fins are wedged firmly into the pocket (4). After checking for flow, the surgeon tucks the shunt's tail under Tenon capsule and closes the conjunctiva with a 10-0 suture (5).

The MicroShunt differs from the Xen45 Gel Stent (Allergan) in several ways. The former is implanted ab externo and does not require the use of a gonioscope, which is often used during ab interno implantation of the Xen. The MicroShunt requires incising the conjunctiva, which would suggest more scarring than with the Xen; both procedures benefit from the use of MMC, however,<sup>3,4</sup> and a recent report suggests that the Xen requires more postsurgical bleb needling (43%) than trabeculectomy (31%).<sup>3</sup> With the MicroShunt, postoperative needling of the bleb is rarely required (4.3%).<sup>5</sup> Possible reasons for minimal scarring with this device are the biocompatibility of the SIBS material, less trauma to the sclera, deep and wide dissection of Tenon capsule from the sclera, a wide application of MMC, and the control of hemostasis. There have been no head-to-head comparisons of the two devices to date, but Santen is currently enrolling subjects in an FDA-sanctioned

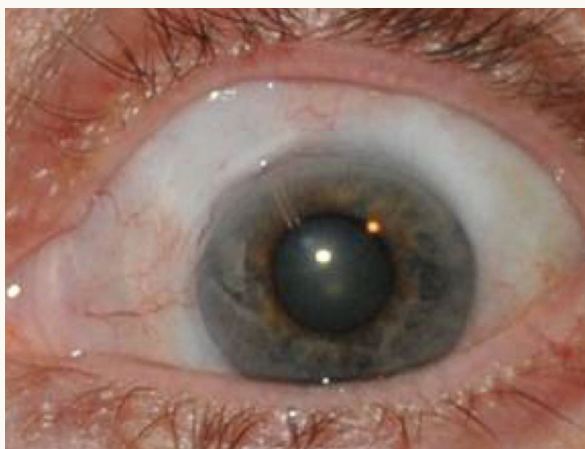prospective randomized trial to compare the MicroShunt to trabeculectomy, both with low doses of MMC.

## RESULTS

In a 3-year study, the MicroShunt was implanted with the application of 0.4 mg/mL MMC in 23 patients.<sup>5</sup> The procedure had a qualified success rate (IOP  $\leq 14$  mm Hg and IOP reduction  $\geq 20\%$ ) of 95%. The IOP decreased from  $23.8 \pm 5.3$  to  $10.7 \pm 3.5$  mm Hg, and the mean number of glaucoma medications per patient dropped from  $2.4 \pm 0.9$  to  $0.7 \pm 1.1$ .

In another study, 79 patients had an average preoperative, fully medicated IOP of  $24.8 \pm 6.1$  mm Hg.<sup>6</sup> Two years after receiving the MicroShunt, the average IOP had decreased by 47% from baseline to  $13.0 \pm 4.6$  mm Hg, and more than 70% of eyes had an IOP of less than 14 mm Hg. There was a 79% reduction in glaucoma medications to 0.6 medications per patient, and 74% of subjects were free of topical drug therapy postoperatively.

Santen expects the MicroShunt, pending FDA approval, to become available in the United States in 2019 or 2020. The device has the CE Mark in Europe. ■



**Figure 4.** The MicroShunt is positioned at 11 o'clock.

1. Pinchuk L, Riss I, Battle JF, et al. The development of a micro-shunt made from poly(styrene-block-isobutylene-block-styrene) to treat glaucoma. *J Biomed Mater Res B Appl Biomater.* 2017;105(1):211-221.
2. Acosta AC, Espana EM, Yamamoto H, et al. A newly designed glaucoma drainage implant made of poly(styrene-bisobutylene-b-styrene) biocompatibility and function in normal rabbit eyes. *Arch Ophthalmol.* 2006;124:1742-1749.
3. Schlenker M, Gulamhusein H, Somers A, et al. Efficacy and safety of stand-alone ab interno gelatin microstent implantation with MMC versus stand-alone trabeculectomy with MMC: multicentre retrospective cohort design. Poster presented at: The 27th Annual AGS Meeting; March 2-5, 2017; Coronado, CA.
4. Gulamhusein H, Schlenker M, Somers A, et al. Stand-alone ab interno gelatin stent with MMC versus stand-alone trabeculectomy with MMC: postoperative patient experience and healthcare utilization. Poster presented at: The 27th Annual AGS Meeting; March 2-5, 2017; Coronado, CA.
5. Battle JF, Fantes F, Riss I, et al. Three-year follow-up of a novel aqueous humor microshunt. *J Glaucoma.* 2016;25(2):e58-65.
6. McGrath D. New minimally-invasive shunt. *Eurotimes.* <http://www.eurotimes.org/new-shunt>. Published November 1, 2016. Accessed March 9, 2017.

**Howard Barnebey, MD**

- medical director and CEO, Specialty Eyecare Centres, Seattle
- (206) 621-8407; hbarnebey@specialtyeyecarecentre.com
- financial interest: none acknowledged; clinical investigator for the InnFocus MicroShunt FDA phase 1 and 2 studies

**Michael Berlin, MD, MS**

- director, Glaucoma Institute of Beverly Hills, Los Angeles
- professor of clinical ophthalmology, Jules Stein Eye Institute, University of California, Los Angeles
- berlin@ucla.edu
- financial interest: currently none; issued and pending US patents that could apply to FDA-approved ELT

**Ulrich Giers, MD**

- Augen-Praxis-Klinik OWL, Detmold, Germany
- financial interest: none acknowledged

**Michael D. Greenwood, MD**

- glaucoma, cornea, cataract, and refractive surgery, Vance Thompson Vision, Fargo, North Dakota
- (701) 566-5390; michael.greenwood@vancethompsonvision.com; Twitter @migreenw
- financial disclosure: lecturer for Alcon

**Leon W. Herndon, MD**

- professor of ophthalmology, Duke University of Eye Center, Durham, North Carolina
- (919) 684-6622; leon.herndon@duke.edu
- financial disclosure: consultant to Alcon, Glaukos, and Sight Sciences

**Mahmoud A. Khaimi, MD**

- clinical associate professor of ophthalmology, Dean McGee Eye Institute, University of Oklahoma College of Medicine, Oklahoma City, Oklahoma
- (405) 271-1093; mahmoud-khaimi@dmei.org
- financial disclosure: consultant to and clinical investigator for ABiC, Ellex

**Erik L. Mertens, MD, FEBOphth**

- physician CEO, Medipolis, Antwerp, Belgium
- chief medical editor, *CRST Europe*
- +32 3 8282949; emertens@medipolis.be; Twitter @Doktermertens
- financial interest: none acknowledged

**Sameh Mosaed, MD**

- professor of ophthalmology and director of glaucoma, The Gavin Herbert Eye Institute, University of California, Irvine
- (949) 824-4122; smosaed@uci.edu
- financial disclosure: consultant to Alcon

**Michael Riggs**

- Glaucoma Institute of Beverly Hills, Los Angeles
- financial interest: none acknowledged

**Vigan Roka, MD**

- Augen-Praxis-Klinik OWL, Detmold, Germany
- financial interest: none acknowledged

**Steven R. Sarkisian Jr, MD**

- glaucoma fellowship director, Dean McGee Eye Institute, and clinical professor, University of Oklahoma College of Medicine, Oklahoma City
- (405) 271-1093; steven-sarkisian@dmei.org
- financial disclosure: consultant to Alcon, Glaukos, New World Medical, and Sight Sciences; holds equity in Sight Sciences; lecturer for Alcon; recipient of research grants from Alcon, Glaukos, and Sight Sciences

**Oluwatosin U. Smith, MD**

- partner physician, Glaucoma Associates of Texas, Dallas
- (214) 360-0000; tsmith@glaucomaassociates.com
- financial disclosure: consultant to Allergan; medical monitor for Glaukos

**Marc Töteberg-Harms, MD, FEBO**

- glaucoma specialist and attending physician, at the UniversityHospital Zurich, Department of Ophthalmology, Zurich, Switzerland
- clinical instructor and lecturer, University of Zurich, Switzerland
- +41 44 255 4993; marc.toeteberg@usz.ch
- financial disclosure: consultant/adviser to Allergan; lecture fees/ travel reimbursement from Alcon, Allergan, and Iridex

**Steven D. Vold, MD**

- founder and CEO, Vold Vision, Fayetteville, Arkansas
- svold@voldvision.com; Twitter @VoldVision
- financial disclosure: consultant to Alcon, Allergan, Ellex, Glaukos, InnFocus, iStar, Ivantis, and NeoMedix