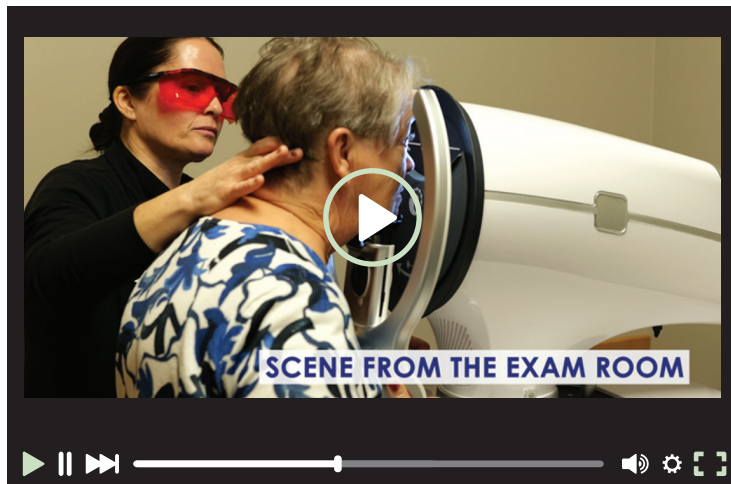


THE BUZZ ON EYETUBE

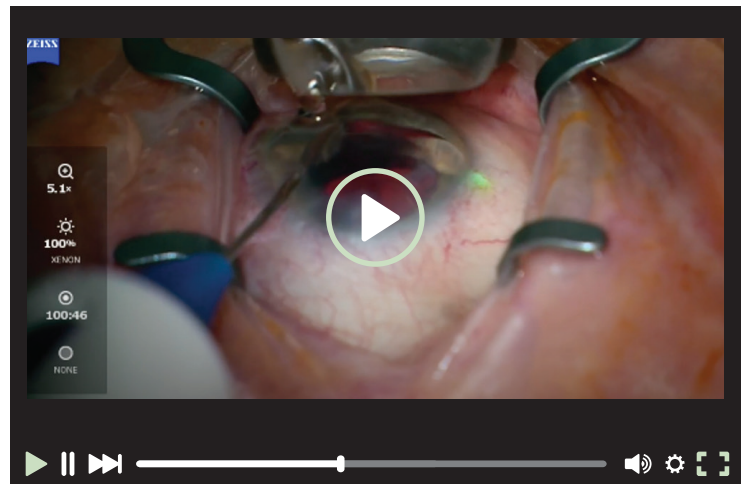
MANAGEMENT OF MILD GLAUCOMA WITH SLT

John P. Berdahl, MD; Tanner J. Ferguson, MD;
and Mitch Ibach, OD, FAAO



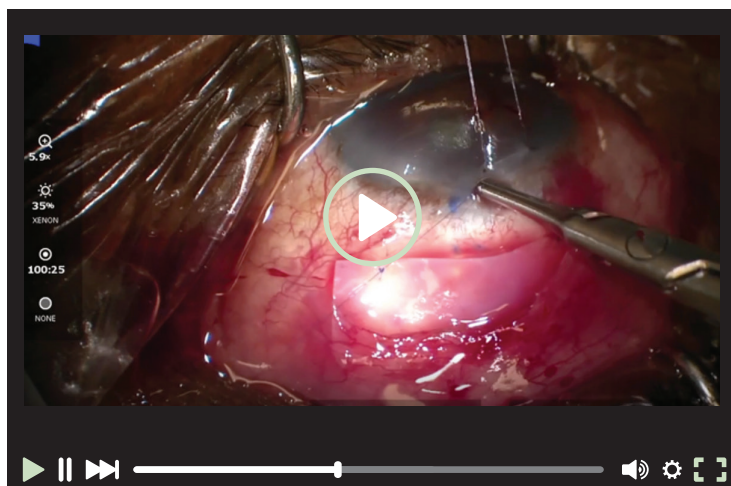MANAGING FOCAL RESISTANCE DURING CANALOPLASTY USING GREEN ILLUMIN TIP FEEDBACK

Mahmoud A. Khaimi, MD



PLACENTAL TISSUE TO SCAFFOLD THE CONJUNCTIVA

I. Paul Singh, MD



THE IMPORTANCE (AND UNIMPORTANCE) OF ECL IN IG

Iqbal Ike K. Ahmed, MD, FRCS;
Arsham Sheybani, MD; and Manjool Shah, MD

