

# Neovascular Glaucoma

Current concepts and management.

BY JAMES C. TSAI, MD, AND M. BRUCE SHIELDS, MD

**N**eovascular glaucoma (NVG) is a devastating ocular disease, often seen as an end-stage complication of retinal ischemia. Its pathogenesis is associated with neovascularization of the iris (NVI) and of the anterior chamber angle (NVA), with resultant proliferation of fibrovascular tissue in the anterior chamber. The fibrovascular membrane eventually obstructs the trabecular meshwork and contracts to produce progressive angle closure with broad peripheral anterior synechiae. The IOP may become significantly elevated and difficult to control, resulting in advanced glaucomatous optic neuropathy and irreversible visual loss.<sup>1</sup>

The most common conditions associated with NVG are proliferative diabetic retinopathy (PDR), central retinal vein occlusion (CRVO), and ocular ischemic syndrome.<sup>1,2</sup> The list of associated ocular diseases is extensive, however, and the majority (up to 97%) are associated with an underlying process of retinal ischemia and hypoxia.<sup>1</sup> This article focuses on the current understanding of NVG, its diagnosis, and its treatment as well as future therapies.

## MOLECULAR CONCEPTS

Retinal ischemia is one of the most significant etiologic factors in the formation of NVI and NVA. The resulting hypoxia causes the release of factors that both promote and inhibit the growth of new vessels.<sup>3</sup> Moreover, vascular endothelial cells play a crucial role in the entire process of angiogenesis. In response to tissue hypoxia, these endothelial cells secrete diffusible, pro-angiogenic factors such as vascular endothelial growth factor (VEGF), basic fibroblast growth factor, tumor necrosis factor- $\alpha$ , insulin-like growth factors, interleukin-6, and platelet-derived growth factor.<sup>4</sup> This process stimulates a cascade leading to the activation, proliferation, and migration of endothelial cells with the formation of new, leaky, fragile blood vessels.

Comprising four homodimeric polypeptides, VEGF

is the most extensively studied of the pro-angiogenic factors in the pathogenesis of NVG.<sup>5,6</sup> Müller cells are thought to represent a significant source of VEGF under the conditions of retinal hypoxia. Elevated levels of VEGF have been identified in the aqueous humor of patients with NVG.<sup>7</sup> Experimental studies in

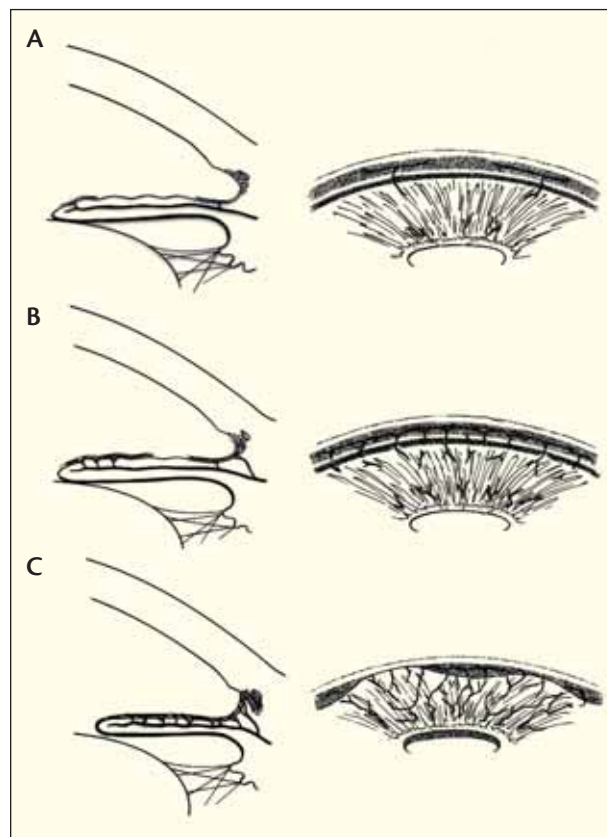


Figure 1. The clinicopathologic stages of neovascular glaucoma are preglaucoma (A), open-angle glaucoma (B), and angle-closure glaucoma (C). (Adapted and reprinted with permission from Allingham RR, Damji K, Freedman S, et al. *Shields' Textbook of Glaucoma*. 5th ed. Lippincott Williams & Wilkins: Philadelphia; 2005: 331.)

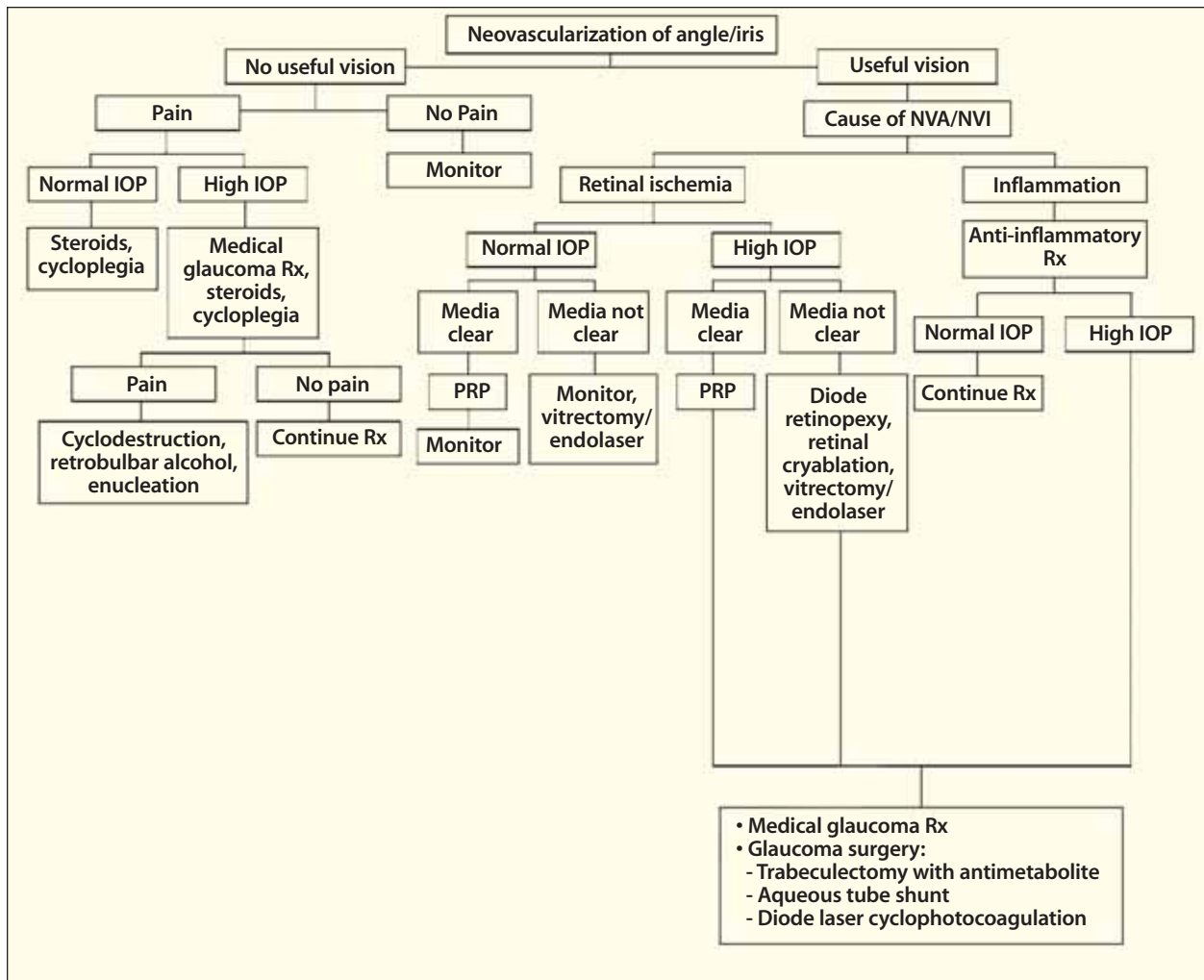


Figure 2. This treatment algorithm for NVG uses the following abbreviations: NVA/NVI, neovascularization of the angle/iris; PRP, panretinal photocoagulation; and Rx, therapy. (Adapted and reprinted with permission from Tsai JC, Forbes M. *Medical Management of Glaucoma*. 2nd ed. Professional Communications: Caddo, OK; 2004: 224-225.)

nonhuman primates have also shown that intravitreal injections of human recombinant VEGF are sufficient to produce noninflammatory NVI, ectropion uveae, and NVG.<sup>8</sup>

Therapy targeted for VEGF is complex, owing to the diversity of endothelial cells, which includes variation in tissue expression of the gene encoding VEGF and the complexity of the VEGF family isoforms and receptors. Furthermore, VEGF therapy alone would likely not be sufficient to fully counteract the angiogenesis process due to the contribution of dozens of other factors in the angiogenesis cascade.<sup>9</sup> These other pro-angiogenic factors include insulin-like growth factors I and II, insulin-like growth factor binding proteins 2 and 3, basic fibroblast growth factor, tumor necrosis

factor-alpha, interleukin-6, and platelet-derived growth factor.

The formation of new vessels in the eye is affected to a large extent by the homeostatic balance between VEGF and other pro-angiogenic factors and the anti-angiogenic factor, pigment-epithelium-derived factor (PEDF).<sup>9,10</sup> PEDF is a naturally occurring and extremely potent inhibitor of angiogenesis that not only targets new vessel growth but also has powerful neuroprotective activities. Studies have shown increased levels of VEGF and decreased levels of PEDF in the vitreous humor of patients with PDR. Observations of reduced PEDF levels in the vitreous of patients with active diabetic retinopathy, compared with inactive retinopathy, further support the theory of a VEGF-PEDF homeostatic equilibrium.<sup>11,12</sup>

## CLINICAL DIAGNOSIS

In patients with associated ocular conditions who are at high risk of developing NVG, clinicians should perform a comprehensive ocular evaluation with particular attention to the pupillary margin of the iris. In patients with CRVO, studies have shown that a relative afferent pupillary defect indicates an increased risk of developing rubeosis iridis.<sup>13</sup>

An undilated slit-lamp examination and gonioscopy are essential to the detection of NVI and NVA, respectively. Although NVI usually precedes NVA, new vessels may occasionally be found in the angle without evidence of iris neovascularization at the slit lamp.<sup>14</sup> The Central Vein Occlusion Study (CVOS) revealed that approximately 10% of eyes with nonischemic CRVO and 6% of eyes with ischemic CRVO developed NVA without signs of iris neovascularization.<sup>15</sup> The importance of careful gonioscopy cannot be overstated in these patients.

Other diagnostic techniques for predicting the risk of developing rubeosis iridis in patients with CRVO include fluorescein angiography and electroretinography. Although there is limited prognostic value in using retinal angiography, iris angiography may reveal early, subtle NVI. In a study of 200 randomly selected fluorescein angiograms of the iris, rubeosis iridis was detected in 97.2% with a false-positive rate of 1%.<sup>16</sup> Moreover, in approximately one-third of the eyes, the iris angiography test allowed the detection of rubeosis prior to its becoming clinically evident on slit-lamp biomicroscopy.

## CLINICAL MANAGEMENT

Despite advances in the medical and surgical management of glaucoma, the visual prognosis for patients with NVG remains poor. Visual outcomes will only be improved with the early detection of NVI/NVA and the prompt initiation of therapy that specifically targets the underlying disease process. The clinicopathologic course of NVG can be conceptualized as proceeding from an initial preglaucoma stage (ie, existing rubeosis iridis) through an intermediate stage of open-angle glaucoma to the advanced angle-closure stage (Figure 1). In the intermediate stage, gonioscopy shows an open anterior chamber angle, but histologic studies indicate that a fibrovascular membrane obstructs the trabecular meshwork, thereby decreasing aqueous outflow and increasing IOP. Once the advanced angle-closure stage develops, the IOP becomes markedly elevated, and the glaucoma becomes extremely difficult to control.

Clinical recommendations for the diagnosis and treatment of NVG may be classified into level A (most important to the clinical outcome) and level B (moderately important to the clinical outcome).<sup>1</sup> Level A diag-

nostic recommendations include a high index of suspicion and complete ocular examination such as undilated slit-lamp biomicroscopy, gonioscopy, and dilated fundusoscopic examination. Level A therapeutic recommendations include treating the underlying disease process with adequate panretinal photocoagulation (PRP), if retinal ischemia is present, and the initial medical control of the IOP and inflammation. Level B recommendations include glaucoma surgery to lower the IOP when medical therapy and PRP are unsuccessful.

## THE TREATMENT OF NEOVASCULARIZATION

In the majority of patients with NVG secondary to PDR, wherein retinal ischemia is the underlying etiology, the ablation of the peripheral retina is first-line therapy to counter the angiogenic cascade. In most instances, PRP with the argon laser is the treatment of choice.<sup>17,18</sup> The importance of adequate PRP treatment must be emphasized. One study reported that 1,200 to 1,600 laser spots produced a regression of rubeosis in 70.4% of diabetic patients, whereas 400 to 650 spots produced regression in only 37.5%.<sup>18</sup>

Although the efficacy of prophylactic PRP in preventing NVG is well documented in patients with diabetic retinopathy, a 10-year prospective study of eyes with CRVO undergoing PRP revealed no significant difference in the incidence of subsequent NVG compared to eyes without PRP.<sup>19</sup> In the CVOS, prophylactic PRP in patients with ischemic CRVO but without manifest rubeosis iridis did not completely prevent the development of NVI/NVA. The prompt regression of the anterior segment neovascularization was more likely when PRP was performed after early signs of rubeosis iridis became manifest.<sup>20</sup> The CVOS investigators also recommended performing PRP promptly when 2 clock hours of NVI and/or any NVA is observed. Thus, for patients with CRVO, the preferred practice is to follow them frequently with undilated slit-lamp examination and gonioscopy and to institute PRP upon the earliest signs of anterior segment neovascularization.

PRP should be administered prophylactically when vitrectomy and/or lensectomy is planned in patients with PDR. One study showed that patients with PDR who underwent prophylactic PRP were less likely to develop rubeosis iridis after cataract extraction than those not receiving PRP.<sup>21</sup> Furthermore, PRP may reverse IOP elevation in the open-angle stage and in some cases of early angle-closure NVG.<sup>22</sup> There is also a higher success rate for glaucoma filtering procedures when PRP is performed initially, because it eliminates or reduces the active anterior segment neovascularization.<sup>23</sup>

When adequate PRP (eg, 1,200 to 1,600 laser spots) is not possible, physicians should consider other retinal ablation modalities, including panretinal cryotherapy and peripheral transscleral retinal diode laser photocoagulation.<sup>1,24</sup> The latter procedure, also known as diode laser retinopexy, has been shown to cause a regression of rubeosis<sup>25</sup> and can be combined with contact diode laser cyclophotocoagulation for IOP control in the treatment of refractory NVG.<sup>26</sup>

An additional surgical option for peripheral retinal ablation is pars plana vitrectomy with laser endophotocoagulation, which can be combined with the direct laser coagulation of the ciliary processes for prompt IOP control.<sup>27,28</sup> Concurrent with vitrectomy, silicone oil tamponade may be employed to prevent or reverse rubeosis iridis by creating a barrier between the anterior and posterior segments, thereby reducing the pro-angiogenic factors and/or the hypoxia in the anterior segment.<sup>27</sup> If significant angle closure and/or active NVA is present, the surgeon may place a glaucoma tube shunt implant via a pars plana entry site at the time of vitrectomy.<sup>28</sup>

## THE TREATMENT OF ELEVATED IOP

### Drugs

The medical management of NVG begins upon the detection of elevated IOP, and it is most successful when the disease is still in its open-angle stage. The preferred agents are those that reduce aqueous humor production such as the topical beta-blockers, topical and oral carbonic anhydrase inhibitors, and the alpha-2 agonists (which also increase uveoscleral outflow with chronic use).<sup>1,29</sup> Topical corticosteroids are often useful, because many patients with NVG of any underlying etiology will have inflammation and ocular discomfort. Cycloplegic agents (eg, atropine) may also be useful for relieving pain.

Miotics are generally contraindicated, because the agents are usually ineffective, increase inflammation, worsen angle closure from synechiae, and decrease uveoscleral outflow. Prostaglandin analogs also may have limited efficacy in NVG due to mechanical obstruction to uveoscleral outflow and potentially increased inflammation.<sup>1</sup>

### Surgery

Cyclodestruction to reduce aqueous humor production may be accomplished with photocoagulation or cryotherapy. The Nd:YAG and diode lasers, using slit-lamp or fiberoptic delivery systems, have been used for controlling IOP in intractable cases of NVG.<sup>30-32</sup> The direct visualization and treatment of the ciliary processes

with an endoscopic diode laser have also been studied.<sup>33</sup> A standardized cyclophotocoagulation protocol in NVG has not been established. Although the IOP can often be controlled, visual results are poor, with the rate of long-term visual loss (ie, two lines or worse) in patients who have NVG approaching almost 50%.<sup>30</sup>

Incisional filtering surgery in patients with active NVG is rarely successful due to the high incidence of intraoperative bleeding and postoperative progression of the fibrovascular membrane. The prior application of PRP may improve success rates by reducing or eliminating the extent of NVI/NVA.<sup>23</sup> The adjunctive use of anti-metabolites such as 5-fluorouracil has been reported to provide success rates of 67% through the first 2 years postoperatively, although success rates fell to 41% and 28% by the fourth and fifth years, respectively.<sup>34</sup> The intraoperative application of mitomycin C or a tissue plasminogen activator, which decreases the postoperative fibrin response, may also increase the likelihood of surgical success.<sup>35,36</sup>

Aqueous tube shunt implants have shown promise in the treatment of refractory NVG, including cases in which conventional filtering surgery failed.<sup>37-39</sup> The long-term visual outcomes with aqueous drainage implants are still less than ideal, however. In 60 eyes with NVG that received Molteno Implants (Molteno Ophthalmic Limited, Dunedin, New Zealand), IOP control (< 21 mm Hg) was achieved in only 10.3% at 5 years.<sup>37</sup> In addition, 48% of eyes lost light perception, and phthisis occurred in 18%. Placing Baerveldt glaucoma implants (Advanced Medical Optics, Inc., Santa Ana, CA) in 36 patients with NVG successfully controlled IOP for 12 months in 79% and for 18 months in 56%, although 31% lost light perception.<sup>38</sup> The Ahmed Glaucoma Valve (New World Medical, Inc., Rancho Cucamonga, CA) may also be useful in the surgical management of refractory NVG.<sup>39</sup> In addition, improved success rates have been reported in patients with refractory NVG when the drainage tube is implanted through the pars plana and combined with pars plana vitrectomy.<sup>28,40</sup>

Figure 2 provides a management algorithm for the treatment of patients with NVI and/or NVA that is based on an extensive review of the literature.<sup>1</sup> For eyes with useful vision, the algorithm focuses on identifying and effectively treating the underlying cause of the neovascularization. For patients in whom adequate PRP treatment cannot be administered, the surgeon should consider diode laser retinopexy, panretinal cryotherapy, or vitrectomy with endolaser. The treatment of NVG may include medical therapy, trabeculectomy with an antiproliferative agent, aqueous tube shunt surgery, or diode laser cyclophotocoagulation.



## FUTURE THERAPEUTIC OPTIONS

Several treatments for NVG in eyes with intractable glaucoma are under investigation. One option is to perform surgical retinectomy (to reroute the aqueous drainage through the choroidal circulation) at the time of pars plana vitrectomy.<sup>41,42</sup> Although the method successfully controlled the IOP in a majority of patients, long-term ocular complications—including retinal detachment, proliferative vitreoretinopathy, and phthisis—were common.

Researchers have also suggested using photodynamic therapy with verteporfin to occlude new iris vessels without damaging adjacent tissue or normal iris vessels, but no results on the progression of rubeosis or NVG have yet been reported.<sup>43</sup> Additionally, the intravitreal injection of crystalline triamcinolone has been studied as a potential treatment to cause a regression of iris neovascularization.<sup>44</sup>

Future therapeutic approaches will be based increasingly on the successful modulation of the angiogenesis cascade. Inhibiting VEGF with neutralizing antibodies prevented iris neovascularization in a nonhuman primate model of retinal vein occlusion.<sup>45</sup> Novel anti-VEGF compounds, which include bevacizumab (ie, Avastin [Genentech, Inc., South San Francisco, CA]; off-label use for ocular disease), small interfering RNA (siRNA) directed against VEGF or VEGF receptor 1, and VEGF trap are being considered.<sup>46-48</sup> In particular, intravitreal bevacizumab has shown promise in the treatment of active retinal and iris neovascularization, with a significant regression of rubeosis iridis and a concurrent reduction in IOP.<sup>46</sup>

In a primate model of rubeosis iridis, systemic treatment with alpha-interferon, a polypeptide that inhibits the proliferation and migration of endothelial cells and new vessel growth, resulted in the regression of the rubeosis.<sup>49</sup> Troxerutin improves microvascular flow by inhibiting platelet and erythrocyte aggregation, increasing erythrocyte deformability, and reducing blood viscosity. In a prospective, randomized, double-masked study of 53 patients with retinal vein occlusion, treatment with the compound significantly improved visual acuity and retinal circulation times and reduced progressive ischemia.<sup>50</sup>

Endogenous angiogenesis inhibitors, particularly those that act broadly at the earliest stages of the angiogenic cascade, could prove to be excellent pharmacologic tools for combating neovascularization. To date, an extensive number of antiangiogenic factors have been characterized.<sup>9</sup> As previously discussed, PEDF (a potent endogenous angiogenesis inhibitor) shows promise in the treatment of rubeosis iridis. The mole-

cule has a remarkable specificity for causing the deterioration of new vessels, with no known deleterious effect on mature vessels.<sup>51</sup> Experimental studies have shown that PEDF can be administered therapeutically as a soluble protein or by viral-mediated gene transfer.<sup>9</sup> In transgenic mice with expression of VEGF in photoreceptors (rho/VEGF mice) and in wild-type mice with laser-induced choroidal neovascularization, the increased in vivo expression of PEDF caused a regression of ocular neovascularization.<sup>52</sup> Furthermore, in a mouse model of ischemia-induced retinal neovascularization, elevated concentrations of PEDF inhibited VEGF-induced retinal vascular endothelial cell growth and migration and retinal neovascularization.<sup>53</sup>

In addition to its pro-apoptotic effect in proliferating vascular endothelial cells, PEDF has apparent neuroprotective effects. Adenoviral vector-mediated intraocular expression of PEDF in rats significantly increased ganglion, inner nuclear, and outer nuclear cell survival after ischemia-reperfusion injury of the retina.<sup>54</sup> Recent studies suggest that PEDF induces pro-survival genes through cyclic adenosine monophosphate-responsive element binding protein and nuclear factor kappa B activation.<sup>55</sup> In this regard, PEDF may have the additional advantage of helping to preserve the integrity of retinal neurons that are damaged from both the underlying retinal ischemia and the resultant elevated IOP in NVG.

## CONCLUSION

NVG is a devastating ocular disease often associated with a poor visual prognosis. No current medical or surgical treatment has a high success rate. The most effective treatment involves retinal ablation, which reduces the level of retinal hypoxia and retards the subsequent angiogenesis cascade. This method effectively lowers IOP only when performed at an early stage of the disease process, however, and it has technical limitations. The best hope for preventing the blindness associated with NVG is continued research into the angiogenesis pathway, a better understanding of which may lead to the development of novel pharmacologic agents (eg, bevacizumab or PEDF) to prevent and/or reverse the neovascularization process in patients. □

*James C. Tsai, MD, is Associate Professor of Ophthalmology and Director of the Glaucoma Division at the Edward S. Harkness Eye Institute, Department of Ophthalmology, Columbia University College of Physicians and Surgeons, New York, New York. He has received research funding and/or served as a consultant/speaker for Alcon Laboratories, Inc.; Allergan, Inc.; Merck & Co., Inc.; and*



Pfizer Inc. Dr. Tsai may be reached at (212) 305-9535; jct2002@columbia.edu.

M. Bruce Shields, MD, is Marvin L. Sears Professor and Chairman, Department of Ophthalmology and Visual Science, Yale University School of Medicine, New Haven, Connecticut. He acknowledged no financial interest in the products or companies mentioned herein. Dr. Shields may be reached at (203) 785-6345; bruce.shields@yale.edu.



1. Sivak-Callcott JA, O'Day DM, Gass JDM, Tsai JC. Evidence-based recommendations for the diagnosis and treatment of neovascular glaucoma. *Ophthalmology*. 2001;108:1767-1778.
2. Brown GC, Magargal LE, Schachat A, Shah H. Neovascular glaucoma. Etiologic considerations. *Ophthalmology*. 1984;91:315-320.
3. Casey R, Li WW. Factors controlling ocular angiogenesis (review). *Am J Ophthalmol*. 1997;124:521-529.
4. Tsai JC, Shields MB. Neovascular glaucoma. In: Tombran-Tink J, Barnstable CJ, eds. *Ophthalmology: Ocular Angiogenesis: Diseases, Mechanisms, and Therapeutics*. Humana Press Inc: Totowa, NJ. In press.
5. Aiello LP, Avery RL, Arrigg PG, et al. Vascular endothelial growth factor in ocular fluid of patients with diabetic retinopathy and other retinal disorders. *N Engl J Med*. 1994;331:1480-1487.
6. Robinson CJ, Stringer SE. The splice variants of vascular endothelial growth factors (VEGF) and their receptors. *J Cell Sci*. 2001;114:853-865.
7. Tripathi RC, Li J, Tripathi BJ, et al. Increased levels of vascular endothelial growth factor in aqueous humor of patients with neovascular glaucoma. *Ophthalmology*. 1998;105:232-237.
8. Tolentino MJ, Miller JW, Gragoudas ES, et al. Vascular endothelial growth factor is sufficient to produce iris neovascularization and neovascular glaucoma in a nonhuman primate. *Arch Ophthalmol*. 1996;114:964-970.
9. Tombran-Tink J, Barnstable CJ. Therapeutic prospects for PEDF: more than a promising angiogenesis inhibitor. *Trends Mol Med*. 2003;9:244-250.
10. Tombran-Tink J, Barnstable CJ. PEDF: a multifaceted neurotrophic factor. *Nat Rev Neurosci*. 2003;4:1-10.
11. Ogata N, Tombran-Tink J, Nishikawa M, et al. Pigment epithelium-derived factor in the vitreous is low in diabetic retinopathy and high in rhegmatogenous retinal detachment. *Am J Ophthalmol*. 2001;132:378-382.
12. Ogata N, Nishikawa M, Nishimura T, et al. Unbalanced vitreous levels of pigment-epithelium-derived factor and vascular endothelial growth factor in diabetic retinopathy. *Am J Ophthalmol*. 2002;134:348-353.
13. Servais GE, Thompson HS, Hayreh SS. Relative afferent pupillary defect in central retinal vein occlusion. *Ophthalmology*. 1986;93:301-303.
14. Blinder KJ, Friedman SM, Mames RN. Diabetic iris neovascularization. *Am J Ophthalmol*. 1995;120:393-395.
15. Central Vein Occlusion Study Group. Baseline and early natural history report. The Central Vein Occlusion Study. *Arch Ophthalmol*. 1993;11:1087-1095.
16. Sanborn GE, Symes DJ, Magargal LE. Fundus-iris fluorescein angiography: evaluation of its use in the diagnosis of rubeosis iridis. *Ann Ophthalmol*. 1986;18:52-58. Erratum in: *Ann Ophthalmol*. 1986;18:155.
17. Tasman W, Magargal LE, Augsburger JJ. Effects of argon laser photocoagulation on rubeosis iridis and angle neovascularization. *Ophthalmology*. 1980;87:400-402.
18. Striga M, Ivanisevic M. Comparison between efficacy of full- and mild-scatter (panretinal) photocoagulation on the course of diabetic rubeosis iridis. *Ophthalmologica*. 1993;207:144-147.
19. Hayreh SS, Klugman MR, Podhajsky P, et al. Argon laser panretinal photocoagulation in ischemic central retinal vein occlusion. A 10-year prospective study. *Graefes Arch Clin Exp Ophthalmol*. 1990;228:281-296.
20. A randomized clinical trial of early panretinal photocoagulation for ischemic central vein occlusion. The Central Vein Occlusion Study Group N report. *Ophthalmology*. 1995;102:1434-1444.
21. Aiello LM, Wang M, Liang G. Neovascular glaucoma and vitreous hemorrhage after cataract surgery in patients with diabetes mellitus. *Ophthalmology*. 1983;90:814-820.
22. Jacobson DR, Murphy RP, Rosenthal AR. The treatment of angle neovascularization with panretinal photocoagulation. *Ophthalmology*. 1979;86:1270.
23. Allen RC, Bellows AR, Hutchinson BT, Murphy SD. Filtration surgery in the treatment of neovascular glaucoma. *Ophthalmology*. 1982;89:1181-1187.
24. Flaxel CJ, Larkin GB, Broadway DB, et al. Peripheral transscleral retinal diode laser for rubeosis iridis. *Retina*. 1997;17:421-429.
25. McHugh JD, Marshall J, Flytche TJ, et al. Initial clinical experience using a diode laser in the treatment of retinal vascular disease. *Eye*. 1989;3:516-527.
26. Tsai JC, Bloom PA, Franks WA, Khaw PT. Combined transscleral diode laser cyclophotocoagulation and transscleral retinal photocoagulation for refractory neovascular glaucoma. *Retina*. 1996;16:164-166.
27. Bartz-Schmidt KU, Thumann G, Psychias A, et al. Pars plana vitrectomy, endolaser coagulation of the retina and the ciliary body combined with silicone oil endotamponade in the treatment of uncontrolled neovascular glaucoma. *Graefes Arch Clin Exp Ophthalmol*. 1999;237:969-975.
28. Scott IU, Alexandrakis G, Flynn HW Jr, et al. Combined pars plana vitrectomy and glaucoma drainage implant placement for refractory glaucoma. *Am J Ophthalmol*. 2000;129:334-341.
29. Allingham RR, Damji K, Freedman S, et al. *Shields' Textbook of Glaucoma*. 5th ed. Lippincott Williams & Wilkins: Philadelphia; 2005.
30. Shields MB, Shields SE. Noncontact transscleral Nd:YAG cyclophotocoagulation: a long-term follow-up of 500 patients. *Trans Am Ophthalmol Soc*. 1994;92:271-283; discussion: 283-287.
31. Bloom PA, Tsai JC, Sharma K, et al. "Cyclodiode." Transscleral diode laser cyclophotocoagulation in the treatment of advanced refractory glaucoma. *Ophthalmology*. 1997;104:1508-1519; discussion: 1519-1520.
32. Oguri A, Takahashi E, Tomita G, et al. Transscleral cyclophotocoagulation with the diode laser for neovascular glaucoma. *Ophthalmic Surg Lasers*. 1998;29:722-727.
33. Uram M. Ophthalmic laser microendoscope ciliary process ablation in the management of neovascular glaucoma. *Ophthalmology*. 1992;99:1823-1828.
34. Tsai JC, Feuer WJ, Parrish RK II, Grajewski AL. 5-fluorouracil filtering surgery and neovascular glaucoma. Long-term follow-up of the original pilot study. *Ophthalmology*. 1995;102:887-892; discussion: 892.
35. Katz GJ, Higginbotham EJ, Lichter PR, et al. Mitomycin C versus 5-fluorouracil in high-risk glaucoma filtering surgery. Extended follow-up. *Ophthalmology*. 1995;102:1263-1269.
36. Lahey JM, Fong DS, Kearney J. Intravitreal tissue plasminogen activator for acute central retinal vein occlusion. *Ophthalmic Surg Lasers*. 1999;30:427-434.
37. Mermoud A, Salmon JF, Alexander P, et al. Molteno tube implantation for neovascular glaucoma. Long-term results and factors influencing the outcome. *Ophthalmology*. 1993;100:897-902.
38. Sidoti PA, Dunphy TR, Baerveldt G, et al. Experience with the Baerveldt glaucoma implant in treating neovascular glaucoma. *Ophthalmology*. 1995;102:1107-1118.
39. Tsai JC, Johnson CC, Dietrich MS. The Ahmed shunt versus the Baerveldt shunt for refractory glaucoma: a single-surgeon comparison of outcome. *Ophthalmology*. 2003;110:1814-1821.
40. Luttrull JK, Avery RL. Pars plana implant and vitrectomy for treatment of neovascular glaucoma. *Retina*. 1995;15:379-387.
41. Kirshof B. Retinectomy lowers intraocular pressure in otherwise intractable glaucoma: preliminary results. *Ophthalmic Surg*. 1994;25:262-267.
42. Jousen AM, Walter P, Jones-Cuypers CP, et al. Retinectomy for treatment of intractable glaucoma: long term results. *Br J Ophthalmol*. 2003;87:1094-1102.
43. Muller VA, Ruokonen P, Schellenbeck M, et al. Treatment of rubeosis iridis with photodynamic therapy with verteporfin—a new therapeutic and prophylactic option for patients with the risk of neovascular glaucoma? *Ophthalmic Res*. 2003;35:1:60-64.
44. Jonas JB, Hayler JK, Sofer A, Panda-Jonas S. Regression of neovascular iris vessels by intravitreal injection of crystalline cortisone. *J Glaucoma*. 2001;10:284-287.
45. Adamis AP, Shima DT, Tolentino MJ, et al. Inhibition of vascular endothelial growth factor prevents retinal ischemia-associated iris neovascularization in a nonhuman primate. *Arch Ophthalmol*. 1996;114:66.
46. Avery RL. Regression of retinal and iris neovascularization after intravitreal bevacizumab (Avastin) treatment. *Retina*. 2006;26:352-354.
47. Campochiaro PA. Potential applications for RNAi to probe pathogenesis and develop new treatments for ocular disorders. *Gene Ther*. 2006;13:559-562.
48. Lau SC, Rosa DD, Jayson G. Technology evaluation: VEGF Trap (cancer), Regeneron/sanofi-aventis. *Curr Opin Mol Ther*. 2005;7:493-501.
49. Miller JW, Stinson WG, Folkman J. Regression of experimental iris neovascularization with systemic alpha-interferon. *Ophthalmology*. 1993;100:9.
50. Glacet-Bernard A, Coscas G, Chabanel A, et al. A randomized, double-masked study on the treatment of retinal vein occlusion with trolerutin. *Am J Ophthalmol*. 1994;118:421-429.
51. Dawson DW, Volpert OV, Gillis P, et al. Pigment epithelium-derived factor: a potent inhibitor of angiogenesis. *Science*. 1999;285:245-248.
52. Mori K, Gehlbach P, Ando A, et al. Regression of ocular neovascularization in response to increased expression of pigment epithelium-derived factor. *Invest Ophthalmol Vis Sci*. 2002;43:2428-2434.
53. Duh EJ, Yang HS, Suzuma I, et al. Pigment epithelium-derived factor suppresses ischemia-induced retinal neovascularization and VEGF-induced migration and growth. *Invest Ophthalmol Vis Sci*. 2002;43:821-829.
54. Takita H, Yoneya S, Gehlbach PL, et al. Retinal neuroprotection against ischemic injury mediated by intraocular gene transfer of pigment epithelium-derived factor. *Invest Ophthalmol Vis Sci*. 2003;44:4497-4504.
55. Yabe T, Kanemitsu K, Sanagi T, et al. Pigment epithelium-derived factor induces pro-survival genes through cyclic AMP-responsive element binding protein and nuclear factor kappa B activation in rat cultured cerebellar granule cells: implication for its neuroprotective effect. *Neuroscience*. 2005;133:691-700.