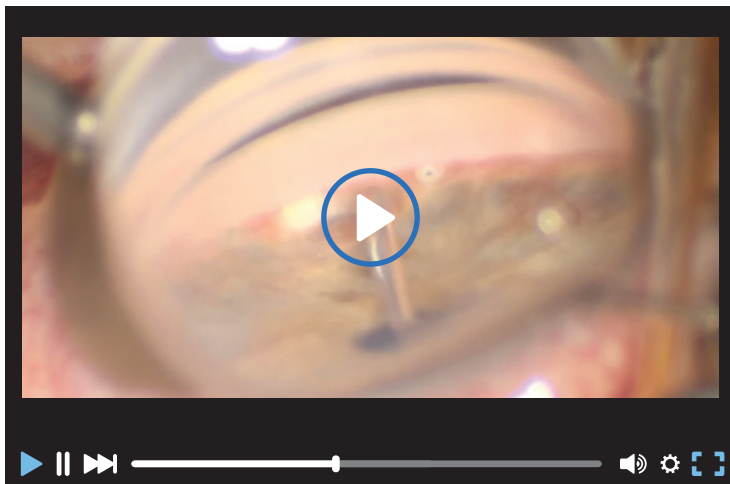


THE BUZZ ON EYETUBE

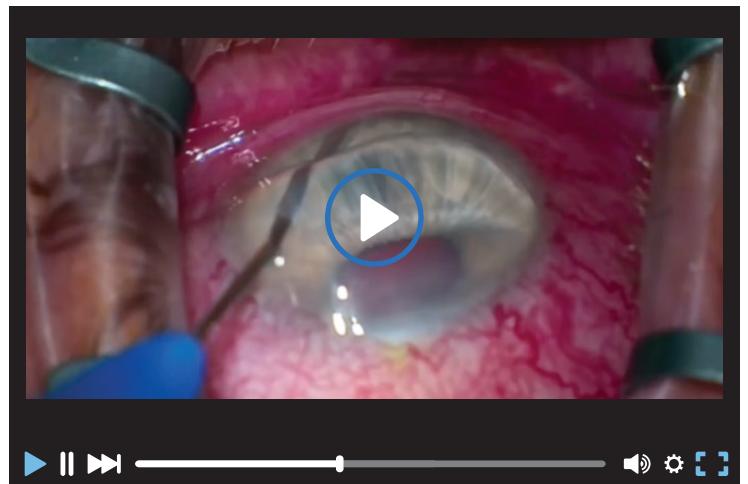**ALLOFLO AFTER TRABECULAR
MICROBYPASS STENTS**

Lorraine M. Provencher, MD



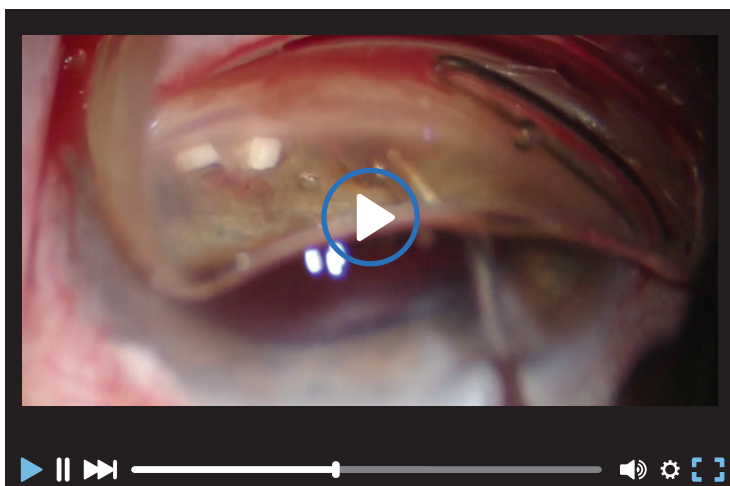
**CANALOPLASTY WITH ITRACK ADVANCE
IN AN EYE WITH TWO PRIOR ISTENT IMPLANTS:
GREEN ILUMIN NAVIGATION**

Mahmoud Khaimi, MD



ALLOFLO 2-1-1 (4X SPACERS)

Billy Pan, MD



**TRAUMATIC ANGLE-RECESSION GLAUCOMA
(TRIPLE PROCEDURE)**

Enver Mirza, MD

