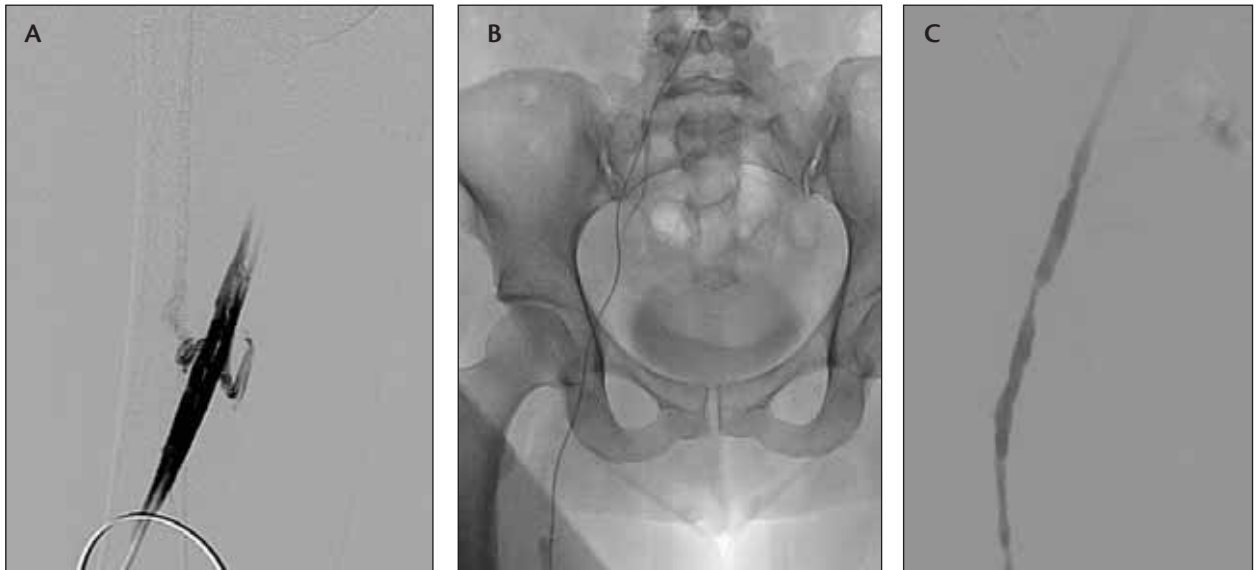


# Case Studies

BY THOMAS A. HENNEBRY, MB BCH BAO, FACC, FSCAI

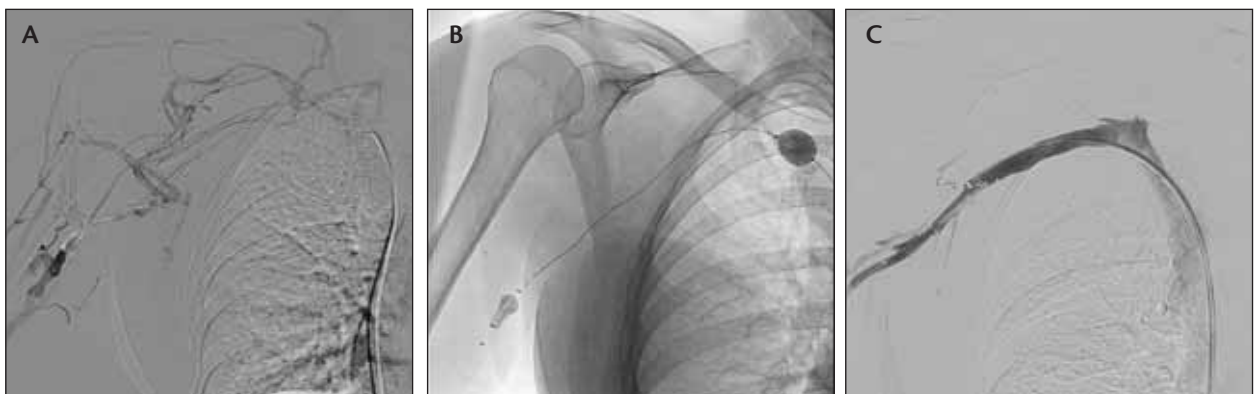OU Health Sciences Center (Oklahoma City, OK), July 2010

## Case 1: Lower Extremity Deep Vein Thrombosis



A 41-year-old woman presented with a 3-week history of a painful swollen left leg despite anticoagulation. A sheath was inserted in her left popliteal vein. Left femoral and iliac vein entirely filled with thrombus (A). The Trellis-8 system (Covidien, Mansfield, MA) was used to deliver 18 mg of tissue plasminogen activator (B). Excellent resolution of thrombus and normal flow restored (C). Pain and swelling resolved within 6 hours, and the patient returned to work.

## Case 2: Upper Extremity Deep Vein Thrombosis



A 53-year-old woman presented with a 3-week history of a painful swollen right arm. She was found to have occluded distal basilic, axillary, and subclavian veins (A). The Trellis-8 system was activated for 14 minutes using 12 mg of tissue plasminogen activator (B). Follow-up shows complete resolution of thrombus with complete sustained resolution of symptoms (C).