

# The Zenith Graft With an Inverted Contralateral Limb

Using a custom-made stent graft in challenging anatomy.

BY BIBOMBE P. MWIPATAYI, MMED (SURG), FCS (SA), FRACS; ROSHAN NAIR, MBBS;  
SHANNON THOMAS, BSc, MBBS; AND VIKRAM VIJAYAN, MRCS, FRCS

Since its inception in 1993, the Zenith abdominal aortic stent graft (Cook Medical, Brisbane, Australia) presented a more complex but very controlled deployment mechanism. It has undergone several modifications since its first implantation and now possesses an uncovered, barbed suprarenal stent to allow for transrenal fixation of the device, which has been loaded into a low-profile, flexible, hydrophilic sheath to facilitate device delivery. The Zenith abdominal aortic stent graft thus has the ability to treat a wide range of

anatomical variations with precision.<sup>1</sup> However, if the distance between the lowest renal artery and the aortic bifurcation is < 82 mm, a standard Cook device will fail to deploy correctly, and theoretically, the contralateral gate will become trapped in the ipsilateral common iliac artery (CIA). A custom-made device is therefore required to deal with this challenging anatomical variant. This article describes three cases using the Cook Zenith stent graft with a customized inverted contralateral limb and discusses the concept and indication for use of this device.

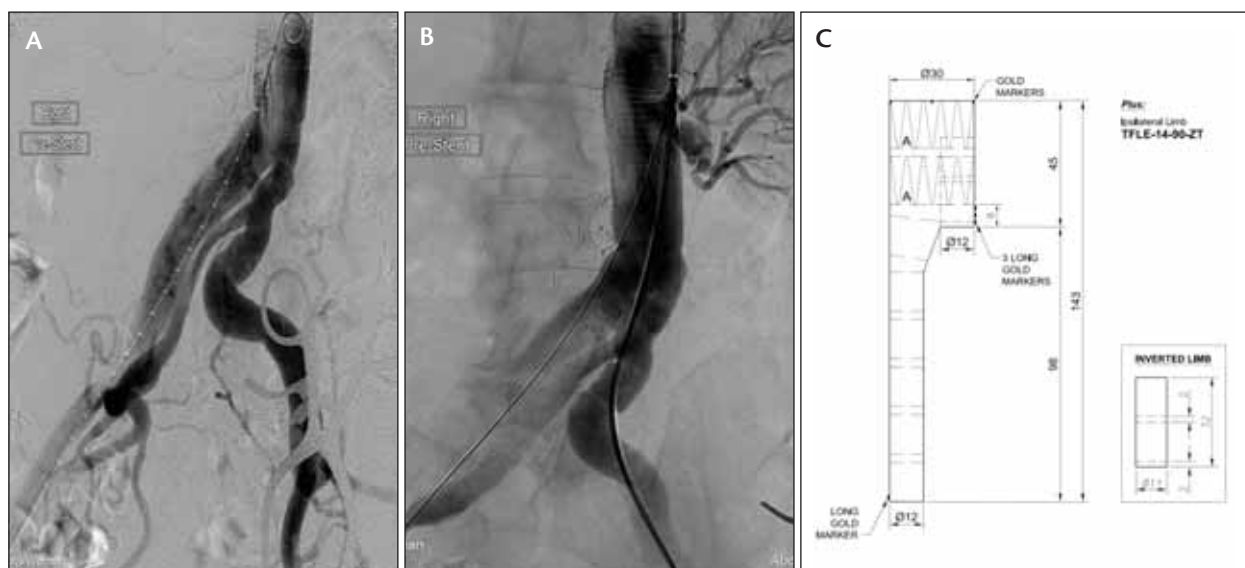


Figure 1. An angiogram showing a dissection of the right CIA with perfusion of the right IIA via one lumen, aneurysmal dilation of the other channel (A), and a single left renal artery (B). Due to the limited length of abdominal aorta proximal to the dissection origin, an inverted contralateral limb was planned to seal above the left common iliac bifurcation (C).

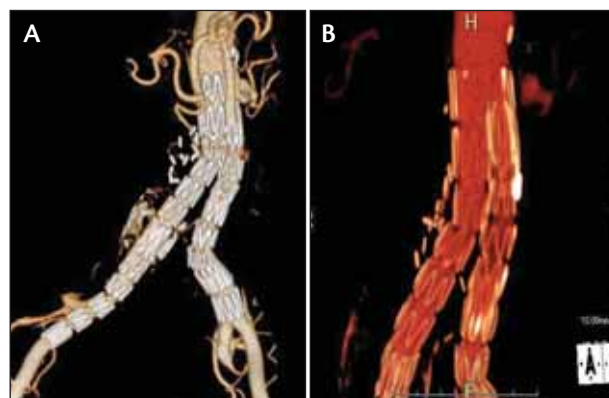
**CASE 1**

A 56-year-old woman with Marfan syndrome was admitted for elective repair of a right common iliac artery aneurysm. Four years previously, she had undergone an open repair of a type B thoracoabdominal aneurysm dissection. Perioperatively, it had been noted that the right CIA was ectatic but not aneurysmal. A follow-up computed tomographic angiogram (CTA) revealed a dissected and ectatic right CIA. This appeared to be chronic and was managed conservatively in the short term.

Nine months later, the right CIA was found to be aneurysmal and required intervention (Figure 1A). A CTA demonstrated only a single left renal artery with an infrarenal aortic diameter of 26 to 27 mm over a length of 60 mm (Figure 1B). The right CIA false lumen extended from the aorta into the external iliac artery (EIA) origin with entry and exit fenestrations seen at these respective points. The right CIA aneurysm measured 35 mm in maximum diameter. The left CIA had a midsegment angulation and measured 16 to 17 mm in maximum diameter. Via bilateral groin exposure, the right CIA aneurysm was repaired using a Zenith stent graft with a custom-made inverted limb. The main body was introduced through the right common femoral artery (CFA), into the wider lumen of the CIA, and the ipsilateral limb extended into the right EIA. Open ligation of the right internal iliac artery (IIA) was performed due to the complexity of the anatomy and the difficulty in identifying the true lumen from the false lumen. A customized contralateral limb was introduced through the left CFA, and this sealed proximally in the inverted limb, within the main body of the graft and distally above the left common iliac bifurcation (Figure 1C). A postprocedural angiogram revealed no endoleak, and the patient was discharged home after 3 days (Figure 2).

**CASE 2**

A 76-year-old man was electively admitted for endoluminal stent graft repair of a 51-mm infrarenal abdominal aortic aneurysm (AAA) associated with mural thrombus. He had undergone an open repair for a ruptured AAA 20 years before, for which he had been reviewed annually. A CTA demonstrated a small saccular aneurysmal dilation of the aorta above the celiac axis with a maximum diameter of 36 mm (Figure 3A). The visceral aorta was relatively uniform, measuring 27 to 32 mm in diameter with a prominent lumbar artery of 3 to 4 mm in caliber rising above the level of the superior mesenteric artery (SMA) and single right and left renal arteries (Figure 3B). The AAA extended from the left renal artery to the proximal anastomosis of the previous



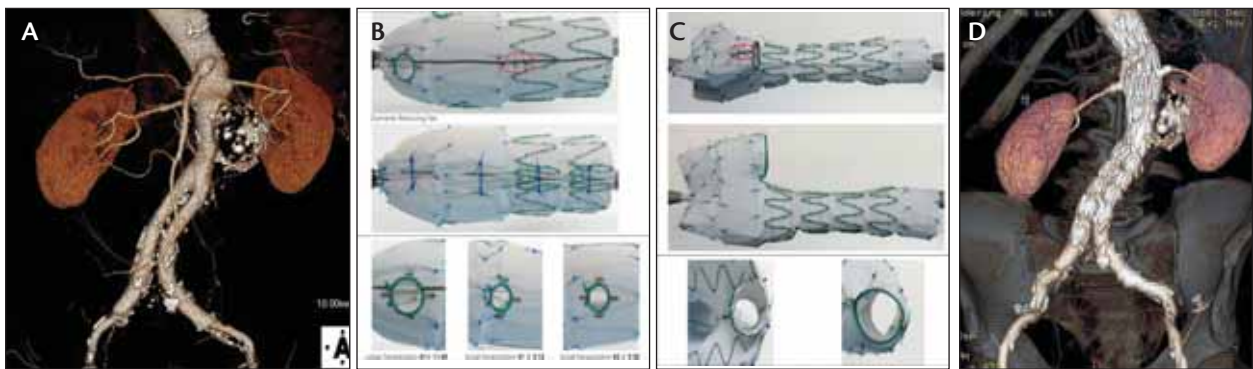
**Figure 2.** Three-dimensional reconstructed images of a post-operative CTA demonstrating patency of both iliac arteries, complete exclusion of the right CIA aneurysm and ligation of the right IIA (A). The contralateral limb was inserted very precisely into the inverted limb with complete sealing of the iliac limb within the main body of the stent graft in this TeraRecon reconstruction (TeraRecon, Foster City, CA) (B).

open repair bifurcated graft, which extended to the common iliac bifurcation bilaterally.

The patient underwent an endoluminal graft repair with a custom-made Zenith device, which had a large fenestration for the SMA and two small fenestrations for the renal arteries. Visceral artery stenting was performed using appropriately sized, covered balloon-expandable stents. Due to the previous open repair graft in situ, the distance between the aortic bifurcation and the renal arteries was limited. As a result, the distal component was planned with an inverted contralateral limb and was introduced via the right-hand side (Figure 3C). The ipsilateral segment landed within the right common iliac open repair graft limb, and the contralateral limb landed within the left. A self-expanding bare-metal stent was inserted to treat a dissection at the origin of the left EIA. He was discharged home 4 days after surgery (Figure 3D).

**CASE 3**

A 77-year-old man with a background of an open repair of an infrarenal AAA with a Dacron tube graft 12 years previously was investigated for incapacitating claudication. A CTA showed a large right CIA aneurysm measuring 50 mm. The left CIA was also very short and tortuous, measuring 22 mm (Figure 4A). The patient initially underwent a right IIA ligation and transposition of the left IIA to the proximal left EIA. This was followed by a definitive repair of the iliac aneurysms with an inverted custom-made Zenith stent graft (Figure 4B). The main body was introduced through the left CFA where the



**Figure 3.** Three-dimensional reconstruction of a preoperative CTA, showing a single right and left renal arteries and the saccular infrarenal aortic aneurysm (A). A custom-made fenestrated graft with a large SMA fenestration and two small fenestrations for both renal arteries (B). Due to limited length, an inverted contralateral limb was designed to allow deployment of the distal bifurcated body component of the graft (C). The postoperative CTA demonstrates that all visceral arteries are patent with complete exclusion of the AAA (D).

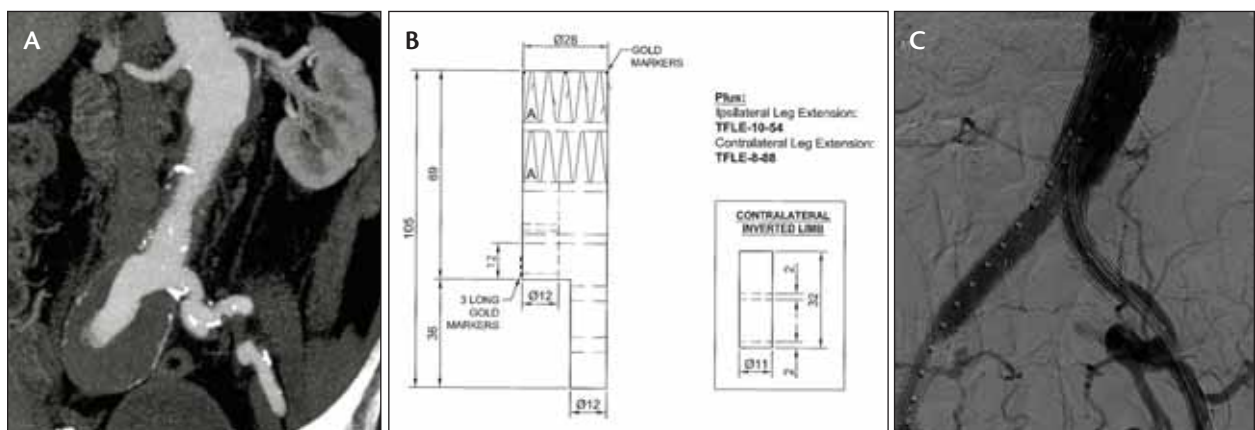
ipsilateral limb now had more sealing area due to the transposed left IIA and sealed just proximal to the neoiliac bifurcation. The proximal sealing zone was planned to be within the Dacron repair graft, distal to the infrarenal ectatic aorta. Fixation bars aided precise proximal deployment. A customized contralateral limb was introduced through the right CFA, and this sealed distally in the proximal EIA. A postprocedural angiogram revealed no endoleak (Figure 4C). The patient was discharged home for routine follow-up after 3 days.

## DISCUSSION

Endovascular aneurysm repair (EVAR) is a landmark contribution in the management of AAAs providing acceptable outcomes with a significant decrease in perioperative morbidity and mortality rates compared to open surgical repair. In recent years, the use of EVAR in

the management of infrarenal AAAs has increased to approximately 45% to 80%.<sup>2,3</sup>

The safety and efficacy of the Zenith endovascular stent graft was based on the United States multicenter trial (United States Zenith Multicenter Trial [ZMT]) through 5 years of follow-up.<sup>4</sup> The respective 5-year survival estimates of patients who underwent a standard Zenith EVAR versus open AAA repair was 83% and 61%, aneurysm-related death was 2% and 4%, and freedom from rupture was 100% and 99.6%, respectively. Cumulative risk of conversion, limb occlusion, graft migration, or component separation was  $\leq 3\%$  at 5 years for the Zenith device. These data thus support long-term durability of the Zenith endovascular stent graft. However, adverse anatomy such as that reported in the previously mentioned cases can preclude the use of a standard device.



**Figure 4.** A CTA showing aneurysmal dilation of the right CIA and an ectatic infrarenal aortic segment (A). A custom-made stent graft with an inverted contralateral limb was planned with the proximal edge of the stent graft designed to land within the surgical graft (B). A postprocedural angiogram indicating exclusion of the right CIA aneurysm and a patent left IIA (C).

The concept of customizing endovascular grafts with an inverted contralateral limb was born from a need to repair and reline a failed short-bodied endovascular device without the need to convert to an aorto-uni-iliac graft. However, the application of this modified device may be extended to include patients with previous thoracoabdominal aneurysm repair, common iliac artery aneurysms associated with a short infrarenal aortic length, or any short infrarenal aortic anatomy that precludes the use of a normal off-the-shelf standard device.<sup>5</sup>

As well as maintaining patency of both iliac arteries by avoiding the use of a uni-iliac system, the inverted limb device offers several other advantages. First, it offers an alternative if the infrarenal aorta is short (renal artery to aortic bifurcation distance less than 82 mm) or if a low accessory renal artery needs to be spared. Second, it maintains columnar strength over a greater length than a conventional bifurcated device, potentially providing greater stability. Third, it provides parallel sealing potential against either the native aorta or graft repair over a longer length than a conventional bifurcated device and in doing so offers more security against either endoleak or migration. Finally, the internal leg of the inverted limb can be between 22 and 30 mm, which allows for an overlap of more than 3 cm. Because of short body, the contralateral limb is longer than the standard Zenith Cook graft contralateral limb, and therefore there is more overlap for the leg extension. In theory, the inverted limb can extend almost all the way proximally to the top of the graft.

The devices feature either a modular design with the proximal component containing the fenestrations (or branches) or a stand-alone bifurcated device with an inverted limb. The custom bifurcated component can be designed with or without fixation spikes or barbs planned to seal within the infrarenal aorta, according to the underlying aneurysmal dilation etiology and the physical status of the aorta.

The internal leg of the inverted limb can either have one stent of 22 mm in length or two stents of 14 mm each, with a 2-mm gap in between, giving an overall length of 30 mm. The gate opening remains 12 mm in outer diameter as per the standard Zenith stent graft, but the inner diameter is 11 mm. There are three long radiopaque gold markers on the outside of the graft at the distal edge of the inverted limb. Recent inverted limb grafts now have a single long gold marker at the proximal edge of the internal limb, allowing for improved fluoroscopic visualization of the inverted limb. Deployment of the contralateral limb proximal to that marker may result in occlusion of the ipsilateral limb ostium.

The price of a custom-made device (CMD) is between A\$5,500 (approximately \$5,545 USD) and A\$5,800 (approximately \$5,845 USD) for the main body and an average of A\$3,300 (approximately \$3,325 USD) for a CMD contralateral limb. This price is comparable to an off-the-shelf device. The average delivery time frame of any CMD is 6 to 8 weeks.

## CONCLUSION

We have demonstrated in three case reports that this new modification of the Cook Zenith stent graft allows for the successful treatment of more challenging anatomy. Our experience with the inverted limb indicates that it is feasible to design a stent graft using an inverted limb when the infrarenal aorta is short and unsuitable for a standard device. ■

*The authors thank Mr. William Fitzsimons and Dr. David Hartley for their input in this paper.*

*Bibombe P. Mwiipatayi, MMed (Surg), FCS (SA), FRACS, is an endovascular surgeon with the Department of Vascular Surgery at Royal Perth Hospital, Professor of Surgery at the School of Surgery, and Faculty of Medicine, Dentistry, and Health Sciences at the University of Western Australia in Perth, Australia. He has disclosed that he holds no financial interest in any product or manufacturer mentioned herein. Dr. Mwiipatayi may be reached at +61-8-9224 0228; bibombe@iinet.net.au.*

*Roshan Nair, MBBS, is a medical officer with the Department of Vascular Surgery at Royal Perth Hospital in Perth, Australia. He has disclosed that he holds no financial interest in any product or manufacturer mentioned herein.*

*Shannon Thomas, BSc, MBBS, is a vascular fellow with the Department of Vascular Surgery at Royal Perth Hospital in Perth, Australia. He has disclosed that he holds no financial interest in any product or manufacturer mentioned herein.*

*Vikram Vijayan, MRCS, FRCS, is a senior vascular fellow with the Department of Vascular Surgery at Royal Perth Hospital in Perth, Australia. He has disclosed that he holds no financial interest in any product or manufacturer mentioned herein.*

1. Greenberg RK, Chuter TA, Sternbergh WC 3rd, et al. Zenith AAA endovascular graft: intermediate-term results of the US multicenter trial. *J Vasc Surg.* 2004;39:1209-1218.
2. Armon MP, Yusuf SW, Latief K, et al. Anatomical suitability of abdominal aortic aneurysms for endovascular repair. *Br J Surg.* 1997;84:178-180.
3. Treiman GS, Lawrence PF, Edwards WH Jr, et al. An assessment of the current applicability of the EVT endovascular graft for treatment of patients with an infrarenal abdominal aortic aneurysm. *J Vasc Surg.* 1999;30:68-75.
4. Greenberg RK, Chuter TA, Cambria RP, et al. Zenith abdominal aortic aneurysm endovascular graft. *J Vasc Surg.* 2008;48:1-9.
5. O'Brien N, D'Elia P, Sobocinski J, et al. Inverted limbs in fenestrated and branched endografts. *J Endovasc Ther.* 2010;17:624-630.