

# Techniques for Crossing Iliac and Aortoiliac CTOs

Using access strategies and reentry devices for successful intervention.

BY DIERK SCHEINERT, MD, AND ANDREJ SCHMIDT, MD

Approximately one-third of obstructive lesions in peripheral arterial occlusive disease affect the aortoiliac segment. Stenotic lesions in the common or external iliac arteries are an established indication for percutaneous procedures, but occlusions of the iliac arteries, even in the most recent TransAtlantic Inter-Society Consensus recommendations, are still mainly considered an indication for surgical reconstruction.<sup>1</sup> Although highly effective in terms of graft patency, these surgical procedures are associated with substantial procedure-related risks for the patient. In a meta-analysis of data published after 1975, the aggregate operative mortality rate was 3.3%, and the aggregate systemic morbidity rate was 8.3%.<sup>2</sup>

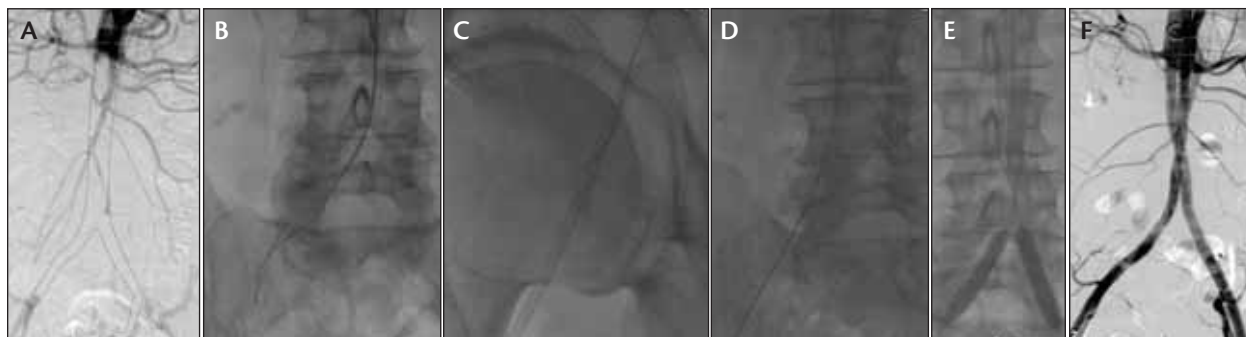
One of the main challenges when treating completely occluded iliac arteries is achieving safe initial passage of the occlusion. From our experience, it is of great importance to choose the appropriate interventional access strategy to maximize the interventional success rate. Possible approaches to treating iliac occlusion include retrograde, crossover, and brachial access. Although it is frequently used, the ipsilateral retrograde approach has the disadvantage of using the more difficult arterial puncture site, which is distal to the occluded segment. In many cases, it is difficult or impossible to navigate the guidewire intraluminally through the occlusion, which may result in extensive dissection of the vessel wall. Particularly in the region of the aortic bifurcation, it can be extremely difficult to reenter from the subintimal space into the true lumen, and in fact, this situation has been described as one of the most common reasons for failure of an interventional recanalization

attempt.<sup>3</sup> To avoid the previously described situation, in our practice, we generally prefer to approach the occlusion antegrade using either the crossover or the transbrachial approach.

## EXTERNAL ILIAC ARTERY OCCLUSIONS

Particularly for occlusions of the external iliac artery, the crossover approach can be considered the standard access strategy. After contralateral retrograde femoral puncture, a crossover maneuver is performed with a soft hydrophilic guidewire and an appropriate diagnostic catheter (Cobra, Judkins right, or similar). Eventually, the guidewire and the catheter are placed into the external iliac artery. After exchanging for a stiff guidewire (Hi-Torque Supra Core [Abbott Vascular, Santa Clara, CA], Amplatz Super Stiff [Boston Scientific Corporation, Natick, MA], or similar), a 6-F crossover sheath (40–45 cm in length) is introduced and placed with the tip just proximal to the external iliac artery occlusion. Contralateral angulation of the fluoroscopic system is recommended to optimize visualization of the proximal occlusion stump. Crossing of the occlusion can be attempted with a 0.018-inch steerable hydrophilic-coated wire (eg, V-18 Control Wire, Boston Scientific Corporation) or, in more rigid occlusions, with a straight or angulated stiff hydrophilic 0.035-inch Glidewire (Terumo Interventional Systems, Somerset, NJ).

During passage, it is advisable to support the catheter with a diagnostic catheter to improve its pushability. Careful attention should be paid to reenter the patent vessel directly at the point of reconstitution to avoid propagation of a dissection into the common femoral artery. In



**Figure 1.** Total occlusion of the abdominal aorta from the renal to the hypogastric arteries bilateral (A). Transbrachial subintimal passage of a 0.035-inch hydrophilic, stiff-angled Glidewire supported by a 5-F multipurpose catheter (125 cm, Cordis Corporation, Bridgewater, NJ) (B). The guidewire entered a 7-F, 10-cm sheath in the right groin to externalize the wire and to perform the further steps in a retrograde way (C). Subintimal passage and direction of the guidewire to the left side (D). Implantation of long covered stents (Viabahn, 9 X 150 mm [Gore & Associates, Flagstaff, AZ], both sides) and additional implantation of balloon-expandable stents (Scuba, 9 X 80 mm, Medtronic-Invatec, Frauenfeld, Switzerland) bilaterally (E). Final result (F).

case of a subintimal crossing, the use of a bent-tip catheter can be helpful to reenter the true lumen. Alternatively, the use of a reentry system (Pioneer catheter [Medtronic, Inc., Minneapolis, MN] or Outback LTD reentry catheter [Cordis Corporation]) should be considered.

After successful passage, the entire recanalized segment should be stabilized with stent implantation. In the region of the external iliac artery, which is typically curved and close to the hip joint, we generally prefer self-expanding nitinol stents. Because the external iliac artery is a relatively fragile region with a certain potential for perforation, careful attention should be paid during the postdilatation process not to oversize balloons but rather gradually increase the balloon size with moderate dilatation pressure. Covered stents, either self-expanding (Viabahn [Gore & Associates] or Fluency [Bard Peripheral Vascular, Inc., Tempe, AZ]) or balloon-expandable (Advanta V12, [Atrium Medical Corporation, Hudson, NH]) should always be available as backup devices to interventionally manage a potential vessel perforation.

### COMMON ILIAC ARTERY OCCLUSIONS

For occlusions of the common iliac artery or full-length obstructions of the iliac axis (common and external iliac artery), the crossover recanalization technique is a valuable option. After retrograde puncture and sheath placement, a 5-F curved diagnostic catheter (hook or shepherd's hook) is positioned at the aortic bifurcation with the tip engaging the stump of the occlusion. A stiff, 0.035-inch hydrophilic Glidewire (angled tip) is used to pass the occlusion, and the tip is finally placed into the common femoral artery. To allow optimal stent place-

ment at the aortic bifurcation, it is usually mandatory that the crossover wire is externalized through an additional sheath placed in the common femoral artery distal to the occlusion. This approach allows completion of the procedure with retrograde balloon angioplasty and stent placement. Although this technique guarantees correct alignment of the wire in the area of the aortic bifurcation and generally has a very acceptable success rate of almost 90%,<sup>4</sup> its disadvantages include the limited support from the curved diagnostic catheter and the fact that there is little control or support to facilitate distal reentry exactly at the reconstitution point distal to the occlusion.

A very useful alternative for common iliac artery recanalization is the transbrachial approach. To avoid crossing of the aortic arch with the attendant risk of cerebral embolization, and to have more direct access to the descending aorta, the left brachial approach should be used whenever possible. After percutaneous puncture of the brachial artery and navigation of a wire into the descending aorta, a 90-cm-long, 6-F sheath is placed with the tip directly engaging the stump of the common iliac artery occlusion. According to our experience, this is a very stable and straight approach that allows every kind of catheter manipulation to the iliac arteries (including the use of reentry systems if needed) and provides a lot of support and pushability. Because all devices that are typically needed for an iliac recanalization procedure, including balloon-expandable and self-expanding stents, are available as 6-F-compatible products, transbrachial procedures can be accomplished entirely through the brachial sheaths without the need for additional access sites. To avoid puncture

site-related complications in our practice, the sheath is removed immediately after the procedure, and the puncture site is managed by manual compression.

## OCCCLUSIONS OF THE AORTIC BIFURCATION AND THE INFRARENAL AORTA

Occlusions involving the infrarenal aorta and the aortoiliac bifurcation are technically demanding and typically involve the need for bilateral access to facilitate the reconstruction of the aortic bifurcation using the kissing stent technique (Figure 1).<sup>5,6</sup> Again, the transbrachial approach is our preferred technique to facilitate the initial crossing of the occluded segment because it guarantees the correct alignment of the guidewire in the proximal part of the occlusion (Figure 1B). After crossing one side of the occlusion, the guidewire is externalized through an additional sheath in the common femoral artery followed by transbrachial recanalization into the other iliac artery (Figure 1C and 1D).

There are different strategies and considerations for stabilization of the recanalized segment with stents. For the aortoiliac bifurcation, the implantation of kissing balloon-expandable stents over a bilateral vascular access can be

considered the standard technique. The advantage of balloon-expandable stents is mainly their high radial resistive force, which is typically required to optimally reconstruct the bifurcation. For occlusions also involving the distal part of the aorta, one of the main challenges is the fact that they contain various amounts of fresh or chronic thrombus. Therefore, in this region, the use of covered balloon-expandable stents (Advanta V12), which have the capability to avoid thrombus dislodgement and embolization, can be recommended. In case of extensively long occlusions, the implantation of long self-expanding covered stents (Viabahn) and additional implantation of balloon-expandable stents to improve the radial force could be an alternative (Figure 1E and 1F). The decision of whether kissing stents in the bifurcation should be combined with larger aortic stents is case-specific and largely depends on the degree of involvement of the infrarenal aortic segment.

## REENTRY SYSTEMS FOR RECANALIZATION OF AORTOILIAC OCCCLUSIONS

Subintimal recanalization is a frequent scenario when dealing with chronic occlusions in the aortoiliac segment, and accurate reentry into the true lumen is an

### Indications for Use

The Medtronic Vascular Complete SE Vascular Stent System is indicated for improving luminal diameter in patients with iliac stenosis in previously unstented lesions with vessel reference diameters between 4.5 mm and 9.5 mm and lesion lengths up to 90 mm. The stent is intended as a permanent implant.

### Contraindications

There are no known contraindications.

### Warnings/Precautions

- The Complete SE Vascular Stent System is provided sterile for one procedure only. Do not resterilize. Use prior to the "Use By" date noted on the package.
- Use of the Complete SE Vascular Stent System requires advanced iliac angioplasty technical skills. The following instructions provide technical guidance but do not obviate the need for adequate training prior to use of the device.
- Do not use if the temperature indicator found on the inner pouch is changed from a gray square to a black square as this indicates the unconstrained stent diameter and stent release may be compromised.
- Persons with known hypersensitivities to nitinol and/or its components (e.g., nickel, titanium) may suffer an allergic reaction to the Complete SE Vascular Stent.
- Maintain the delivery system parallel to the patient and as straight as possible during the procedure to prevent delivery system catheter kinking.
- Do not deploy the stent if it is not optimal or appropriate for the vessel. The stent cannot be repositioned once deployed.
- Inappropriate patient selection may contribute to poor device performance.
- Care should be taken when stenting near a bifurcation, aneurysm or bypass graft.
- Prior to stent deployment, utilize fluoroscopy to verify the stent has not been damaged or dislodged during positioning.
- If unable to initiate stent release, remove the entire system from the patient and advance a new, previously unopened stent delivery system.
- Once deployment is initiated, the stent cannot be retracted by the sheath. In the event of partial delivery of the stent, remove the entire delivery system from the patient. This may result in damage to the vessel wall requiring surgical intervention.
- Prior to completion of the procedure, utilize fluoroscopy to ensure proper positioning of the deployed stent. If the target lesion is not completely stented, use additional Complete SE Vascular Stents as necessary to adequately treat the lesion.
- The Complete SE Vascular Stent System is intended for use by physicians familiar with iliac stenting techniques and the risks associated with stenting.
- Thrombogenicity evaluations were conducted using a heparinized model. If your patient cannot be adequately anti-coagulated, it is unknown whether thrombus formation may occur with this product.

- The use of overlapping stents with the Complete SE Vascular Stent System has not been formally evaluated in a clinical trial.
- Caution must be taken when crossing the stented area with ancillary equipment to avoid dislodgement of the stent.

### Potential Adverse Events

The following complications may be associated with the use of iliac stenting devices or iliac angioplasty: abrupt stent closure; allergic reaction (contrast medium, drug, stent or filter material); amputation/limb loss; aneurysm or pseudoaneurysm in vessel or at vascular access site; angina/ coronary ischemia; arrhythmia (including premature beats, bradycardia, atrial and/or ventricular tachycardia, atrial and/or ventricular fibrillation [VF]); angiotensin or bradycardia requiring placement of a temporary pacemaker; arteriovenous fistula; bleeding complications from anti-thrombotic or antiplatelet medication requiring transfusion or surgical intervention; death; detachment and/or implantation of a component of the system; emboli; distal (air, tissue, plaque, thrombotic material, stent); fever; hematoma at vascular access site, with or without surgical repair; hemorrhage (renal, with or without transfusion); hypotension/hypertension; infection, local or systemic including bacteremia or septicemia; ischemia requiring intervention (bypass or amputation of toe, foot, or leg); myocardial infarction/pain (leg/foot); pain at catheter insertion site; pulmonary embolism/renal failure/insufficiency secondary to contrast medium; stent malposition/migration; stent strut fracture; stroke; vascular thrombosis/occlusion at puncture site, treatment site, or remote site; vessel dissection, perforation or rupture; vessel spasm or necrosis; worsened claudication/rest pain.

Please reference appropriate product literature for use for a more detailed list of indications, warnings, precautions and potential adverse events.

**CAUTION:** Federal (USA) law restricts this device to sale by or on the order of a physician.

For further information, please call Medtronic at 888.283.7868 and/or consult Medtronic's website at [www.medtronic.com](http://www.medtronic.com).

For distribution in the USA only. © 2010 Medtronic, Inc. All rights reserved. Printed in USA.

[www.medtronic.com](http://www.medtronic.com)  
[www.invasiv.com](http://www.invasiv.com)

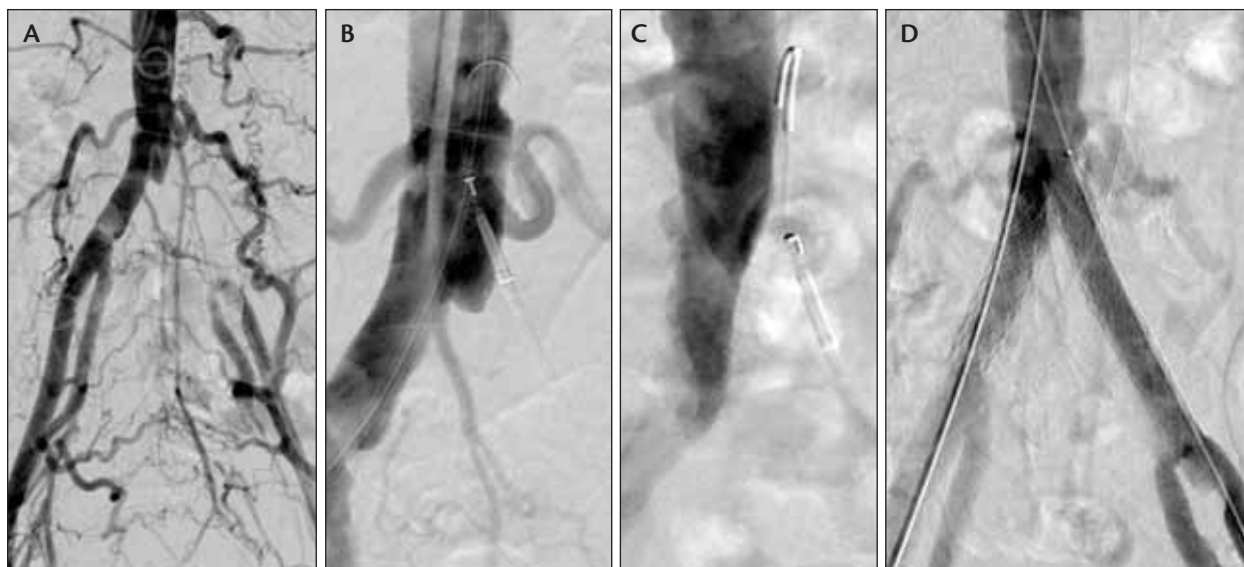Medtronic Cardiovascular  
55/b Unical Place  
Santa Rosa, CA 95403  
USA  
Tel: 707.525.0111

Product Services  
Tel: 888.283.7868  
Fax: 800.811.1101

CardioVascular LifeLine  
Customer Support  
Tel: 877.576.7868  
Tel: 707.525.7868



**Medtronic**



**Figure 2.** Occlusion of the left common iliac artery (A). An Outback catheter was inserted retrograde into the occlusion to enable reentry into the aortic bifurcation. The marker at the distal tip has to be brought into alignment to the artery forming a “T” where reentry of the guidewire is intended (B). The C-arm is then brought into a 90° position to the previous angiogram. In this position, the marker at the tip of the Outback catheter should form an “L” to direct the angled needle to the aortic bifurcation (C). Result after implantation of balloon-expandable stents in kissing technique into the aortic bifurcation (D).

important requirement but also a major challenge. Various techniques and approaches have been described, which all have advantages or disadvantages to achieve this goal. To facilitate reentry of the guidewire into the true lumen, specific reentry devices have been introduced, and the initial experience primarily obtained in the femoral arteries supports their clinical value (Figure 2).<sup>7,8</sup> Experience with these technologies in the iliac arteries is still somewhat limited, but they can certainly be very helpful tools in specific conditions.<sup>9</sup> One of the challenges when using these devices in a retrograde fashion to achieve reentry in the area of the aortic bifurcation is the difficult orientation given the complex three-dimensional anatomy. For this application, the Pioneer system may be preferable because it provides an intravascular ultrasound–based orientation that facilitates positioning of the device.

## CONCLUSION

Recanalization of chronic occlusions in the aortoiliac segment is feasible and safe. Careful planning of the procedure is important because the interventional approach needs to be tailored to the specific anatomy of the occlusion. Combinations of different access strategies as well as the implementation of reentry devices into the interventional armamentarium are ways to maximize the interventional success rate even in very challenging anatomies. ■

*Dierk Scheinert, MD, is with the Center of Vascular Medicine, Angiology & Vascular Surgery, Park Hospital Leipzig, Germany. He has disclosed that he holds no financial interest in any product or manufacturer mentioned herein. Dr. Scheinert may be reached at [dierk.scheinert@gmx.de](mailto:dierk.scheinert@gmx.de).*

*Andrej Schmidt, MD, is with the Center of Vascular Medicine, Angiology & Vascular Surgery, Park Hospital in Leipzig, Germany. He has disclosed that he holds no financial interest in any product or manufacturer mentioned herein.*

1. Norgren L, Hiatt WR, Dormandy JA, et al. Inter-Society Consensus for the Management of Peripheral Arterial Disease (TASC II). *J Vasc Surg.* 2007;45 (Suppl S):S5-67.
2. Vries SO de, Hunink MG. Results of aortic bifurcation grafts for aortoiliac occlusive disease: a meta-analysis. *J Vasc Surg.* 1997;26:558-569.
3. Vorwerk D, Günther RW, Schürmann K, et al. Primary stent placement for chronic iliac artery occlusions: follow-up results in 103 patients. *Radiology.* 1995;194:745-749.
4. Scheinert D, Schroeder M, Ludwig J, et al. Stent-supported recanalization of chronic iliac artery occlusions. *Am J Med.* 2001;110:708-715.
5. Scheinert D, Schroeder M, Balzer JO, et al. Stent-supported reconstruction of the aortoiliac bifurcation with the kissing balloon technique. *Circulation.* 1999;100 (Suppl II):295-300.
6. Haulon S, Mounier-Vehier C, Gaxotte V, et al. Percutaneous reconstruction of the aortoiliac bifurcation with the “kissing stents” technique: long-term follow-up in 106 patients. *J Endovasc Ther.* 2002;9:363-368.
7. Bausback Y, Botsios S, Flux J, et al. Outback catheter for femoropopliteal occlusions: immediate and long-term results. *J Endovasc Ther.* 2011;18:13-21.
8. Beschoner U, Sixt S, Schwarzwälder U, et al. Recanalization of chronic occlusions of the superficial femoral artery using the Outback re-entry catheter: a single centre experience. *Catheter Cardiovasc Interv.* 2009;74:934-938.
9. Varcoe RL, Nammuni I, Lennox AF, Walsh WR. Endovascular reconstruction of the occluded aortoiliac segment using “double-barrel” self-expanding stents and selective use of the Outback LTD catheter. *J Endovasc Ther.* 2011;18:25-31.