

Evaluating the Legflow Device in the LEG-DEB Registry

A new generation of DCBs could achieve superiority in treating BTK arteries.

BY EUGENIO STABILE, MD, PhD

Drug-coated balloons (DCBs) are considered the treatment of choice for atherosclerotic lesions in the femoropopliteal segment, while the role of DCBs for below-the-knee (BTK) interventions remains to be elucidated. Percutaneous transluminal angioplasty (PTA) is associated with a high acute success rate and low costs, and it remains the recommended gold standard therapy in patients with BTK disease. However, an important limitation is the high rate of recurrent restenosis, estimated at approximately 30% for short stenosis and > 80% after recanalization of occlusive lesions.

Drug-eluting stents (DESs) are a valid solution for focal short lesions and are superior to PTA in terms of primary patency. As lesions in the BTK segment are predominantly long and multifocal, attention has moved to DCBs.

Unfortunately, initial enthusiasm for the role of DCBs in the treatment of BTK disease has been hampered by the negative results of two randomized trials. The IN.PACT DEEP trial assessed the efficacy and safety of the In.Pact Amphirion DCB (Medtronic) in patients with critical limb ischemia (CLI).¹ The most crucial safety endpoint, major amputation-free survival at 12 months, was in favor of the PTA group. These data were considered alarming and led to an interruption of the trial.

Similarly, in the BIOLUX-P II trial, despite the adoption of a more modern DCB technology, there was no statistically significant difference in clinical and performance outcomes between the two treatment groups.²

The use of first-generation DCBs has demonstrated promising results in the prevention of post-PTA restenosis in the femoropopliteal artery in patients with claudication. These results may be difficult to duplicate in patients with CLI, which may be complicated by the

presence of more pronounced systemic inflammation, less efficient risk factor control (eg, diabetes), and the limited possibility for supervised exercise after the procedure.

It is not surprising that devices that proved to be efficient in superficial femoral artery lesions in patients with claudication did not accomplish similar results in much more complex clinical situations (eg, BTK vessels of patients with CLI). First-generation DCBs have several technical limitations, such as inconsistent drug coating concentrations, significant overall drug loss, use of large paclitaxel (PTX) particles, and high initial balloon-artery drug transfer rates resulting in high initial drug-in-tissue concentrations. To overcome these limitations, a new-generation DCB that is covered with a homogenous and stable surface coating using extremely small, nonvisible PTX particles has been developed with the majority of the dose protected within the balloon folds. These DCBs adopt drug excipients that are hydrophobic (to minimize drug loss during transit target site), lipophilic (to accelerate drug release and transfer into the vessel wall), and elastic (to provide coating integrity).

The LEG-DEB registry is a multicenter, European multinational, prospective registry³ designed to evaluate the safety and efficacy of the use of a new-generation DCB (Legflow; Cardionovum) for the treatment of infraginguinal arterial disease in real-world patients (including both patients with claudication and CLI).³

The Legflow is a new-generation DCB that uses SAFEPAX coating technology, a mixture based on an ammonium salt compound that is hydrophobic during catheter tracking to the lesion site and lipophilic when the balloon is inflated. Only through balloon inflation does the excipient matrix open and release the PTX. The PTX molecules are in a nanostructured order, allowing the homogenous drug release of 0.1- μ m drug particles

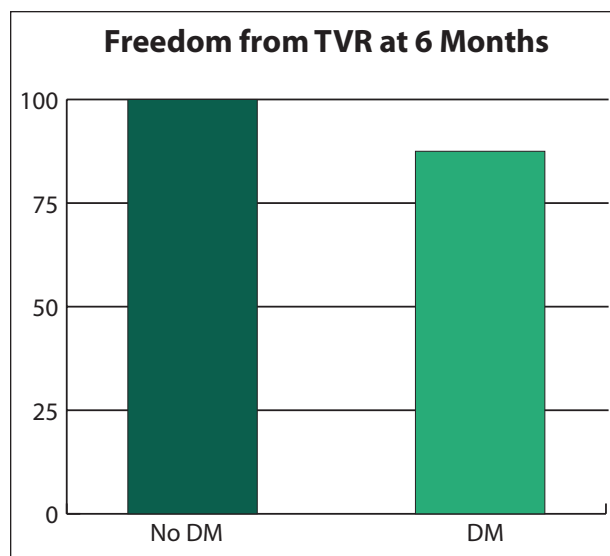


Figure 1. A representative bar graph illustrating freedom from target vessel revascularization (TVR) in patients undergoing PTA of the BTK arteries using a new-generation DCB (Legflow, Cardionovum). Good vessel patency at 6 months can be achieved even in the presence of diabetes mellitus (DM).

(compared to early generation DCBs that release PTX particles of 2–3 μ m) that are easily absorbed intramurally and do not expose the patient to the potential risk of microembolization.

In the initial report from the LEG-DEB registry, the 123 consecutive patients undergoing femoropopliteal PTA at 6 months demonstrated a similar efficacy rate independently of patient clinical status (two-thirds of the patients were treated for claudication and one-third for CLI).

The LEG-DEB registry is also collecting data on the treatment of the BTK vessel. Currently, more than 36 patients have been included in the registry and have 6 months of available follow-up.⁴

Despite a mean lesion length of 115 ± 41 mm, the primary efficacy endpoint at 6 months (freedom from target vessel revascularization) was achieved in all patients without diabetes and in 87.5% of patients with diabetes (Figure 1). The primary safety endpoint (freedom from any amputation) was achieved in 95% of patients without diabetes and in 75% of patients with diabetes. Of note, among the five amputations that occurred, in four cases, amputations were minor and were planned before revascularization and performed during in-hospital stay.

These data, although preliminary, could support the idea that new-generation DCBs could be used to help achieve a long-term safety and efficacy superiority of DCBs over PTA in BTK interventions. ■

1. Zeller T, Baumgartner I, Scheinert D, et al; IN.PACT DEEP Trial Investigators. Drug-eluting balloon versus standard balloon angioplasty for infrapopliteal arterial revascularization in critical limb ischemia: 12-month results from the IN.PACT DEEP randomized trial. *J Am Coll Cardiol*. 2014;64:1568–1576.

2. Zeller T, Beschoner U, Pilger E, et al. Paclitaxel-coated balloon in infrapopliteal arteries: 12-month results from the BIOLUX P-II randomized trial (BIOTRONIK'S-first in man study of the Passeo-18 LUX drug releasing PTA balloon catheter vs. the uncoated Passeo-18 PTA balloon catheter in subjects requiring revascularization of infrapopliteal arteries). *JACC Cardiovasc Interv*. 2015;8:1614–1622.

3. Stabile E, Magliulo F, Zhelev D, et al. Interim analysis at 6 months from the LEG-flow drug eluting balloon for the treatment of femoropopliteal occlusions (LEG-DEB) registry. *Int J Cardiol*. 2016;223:654–655.

4. Stabile E. New generation DCB for the treatment of femoral and below the knee lesions. Presented at: Charing Cross 2017; April 25–27, 2017; London, United Kingdom.

Eugenio Stabile, MD, PhD

Division of Cardiology

Department of Advanced Biomedical Sciences

“Federico II” University

Naples, Italy

+39 081 7462239; eugenio.stabile@gmail.com

Disclosures: Speaker honoraria from Cardionovum.