

# Drug-Coated Balloon Update: Are All DCBs the Same?

A summary of presentations on the use of DCBs and treatment of complex lesions from the inaugural iVS.

**WITH FABRIZIO FANELLI, MD, EBIR; PROF. ULF TEICHGRÄBER, MD;  
AND KOEN DELOOSE, MD**

The interactive Vascular Summit (iVS), held in February 2020 and sponsored by iVascular, aimed to provide an update on the latest trials, technologies, and devices for peripheral artery disease treatment through a series of clinical cases and debates. The iVS's scientific committee comprises Dr. Koen Deloose (Belgium), Dr. Fabrizio Fanelli (Italy), Prof. Yann Gouëffic (France), Dr. Ralf Langhoff (Germany), and Prof. Vicente Rimbau (Spain), who carefully structured the content to achieve dynamic and educational sessions for the 130 worldwide attendees.

One of the main topics was discussion on the use of drug-coated balloons (DCBs) and how to treat complex lesions. The question posed was: Are all DCBs the same? To answer this question, the following sessions took place.

## KEY POINTS

- With evidence that shows DCBs to be highly effective, the decision becomes which DCB is the best to use.
- New paclitaxel DCB meta-analyses and trials show that there is no increased risk of all-cause mortality.
- The EffPac trial demonstrated that Luminor DCB is safe and effective with no increased risk of mortality.
- In the TINTIN trial, the use of combined therapies with Luminor DCB and iVolution self-expanding stent offered better results in long lesions.

## THE BENEFIT OF USING DCBs OUTWEIGHS THE RISK

### PRO PERSPECTIVE

By Fabrizio Fanelli, MD, EBIR



Based on evidence that DCBs are highly effective to treat complex lesions, the decision becomes which DCB is the best to use. There are currently about 15 DCBs available in Europe, all of which are coated with paclitaxel—a lipophilic drug that works with very low concentrations. Differences between DCBs are with the dose of paclitaxel (which range from 2 to 3.5  $\mu\text{g}/\text{mm}^2$ ), drug formulation, excipient, surface energy, and coating method.

Following the publication of the Katsanos et al meta-analysis,<sup>1</sup> the use of paclitaxel DCBs has been reduced, mainly in the United States due to the regulatory statements (Figure 1). However, with new safety data available in early 2020, DCB use has started to increase.<sup>2</sup>

Based on the available data, DCBs have always been considered safe devices. A recent meta-analysis by Dinh et al demonstrated that there is no increased risk of all-cause mortality in a predominantly chronic limb-threatening ischemia patient population treated with paclitaxel-coated versus uncoated devices.<sup>3</sup> The authors of this meta-analysis recommended continued use of DCBs in this high-risk patient population.

Other meta-analyses have evaluated DCBs in terms of safety, drug mortality, and drug dose.<sup>4</sup> They have assessed the amount of drug administered to the patient and reported that there were no statistically significant differences between the use of DCBs with a low or high dose of paclitaxel or the use of several balloons in long iliac lesions.

## CON PERSPECTIVE

By Prof. Ulf Teichgräber, MD



As Dr. Fanelli explained, with most DCBs using paclitaxel as the drug-coated option, the question turns to which is the best? Available DCBs differ in dose and excipients. The meta-analysis by Klumb et al

includes 14 randomized controlled trials (RCTs), including studies from eight countries, 2,504 patients, and nine DCB types.<sup>5</sup>

Late lumen loss at 6 months was compared for nine different products. All DCBs showed better efficacy than plain old balloon angioplasty (POBA), but there were differences among the various DCBs. Regarding primary patency, both DCBs and POBA had the same performance during the first 12 months. Unfortunately, there are few RCTs that report data between 12 and 24 months because most trials do not have statistical significance during follow-up.

All-cause mortality at 12 months was no different between DCBs and POBA. At 24 months, there appeared to be a trend toward increased risk using DCBs versus POBA of 1.53 risk ratio. In the Klumb et al meta-analysis, when comparing data, the mortality risk reported in all clinical trials is similar except in the EffPac trial.<sup>4</sup>

1. Katsanos K, Spiliopoulos S, Kitrou P, et al. Risk of death following application of paclitaxel-coated balloons and stents in the femoropopliteal artery of the leg: a systematic review and meta-analysis of randomized controlled trials. *J Am Heart Assoc.* 2018;7:e01125. doi: 10.1161/JAHA.118.011245
2. Gray W. The present and the future of drug-coated devices: what to expect in the next 5 years. Presented at: Leipzig Interventional Course (LINC) 2020; January 28–31, 2020. Leipzig, Germany.
3. Dinh K, Gomes ML, Thomas SD, et al. Mortality after paclitaxel-coated device use in patients with chronic limb-threatening ischemia: a systematic review and meta-analysis of randomized controlled trials. *J Endovasc Ther.* 2020;27:175–185. doi: 10.1177/1526602820904783
4. Schneider PA, Laird JR, Doros G, et al. Mortality not correlated with paclitaxel exposure: an independent patient-level meta-analysis of a drug-coated balloon. *J Am Coll Cardiol.* 2019;73:2550–2563. doi: 10.1016/j.jacc.2019.01.013
5. Klumb C, Lehmann T, Aschenbach R, et al. Benefit and risk from paclitaxel-coated balloon angioplasty for the treatment of femoropopliteal artery disease: a systematic review and meta-analysis of randomised controlled trials. *EClinicalMedicine.* 2019;16:42–50. doi: 10.1016/j.eclinm.2019.09.004

## Fabrizio Fanelli, MD, EBIR

Director, Department of Vascular and Interventional Radiology  
“Careggi” University Hospital  
Florence, Italy  
fabrizio.fanelli@unifi.it

Disclosures: Consultant to iVascular.

## Prof. Ulf Teichgräber, MD

Director, Department of Radiology  
University Hospital Jena  
Jena, Germany  
radiologie@med.uni-jena.de

Disclosures: Principal Investigator for EffPac; consultant to iVascular.

## EFFPAC TRIAL 24-MONTH OUTCOMES

By Prof. Ulf Teichgräber, MD

The EffPac trial is a prospective, multi-center, RCT to assess the effectiveness of a paclitaxel-coated Luminor DCB versus POBA in the superficial femoral and popliteal arteries to prevent vessel restenosis.<sup>1</sup> The results observed in this trial have not been achieved in similar trials. Analyzing all the efficacy endpoints, the Luminor DCB (iVascular) demonstrated astonishing outcomes at 24 months. The primary patency achieved, as determined by duplex ultrasound, in the Luminor group was 90.2% and 62.7% in the POBA group ( $P = 0.0004$ ). These positive results can be attributed to the TransferTech nanotechnology that allows a better drug transfer than other coating technologies (Figure 1).<sup>2-9</sup>

Luminor is a safe and effective balloon (Figure 2). With Luminor, the

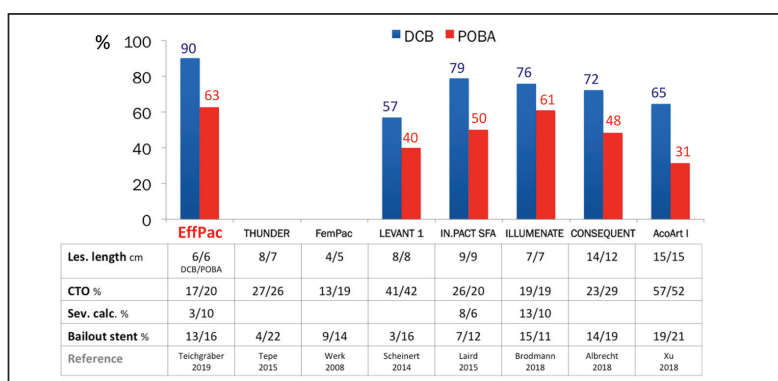


Figure 1. Primary patency at 24 months achieved in different DCB RCTs.<sup>2-9</sup>

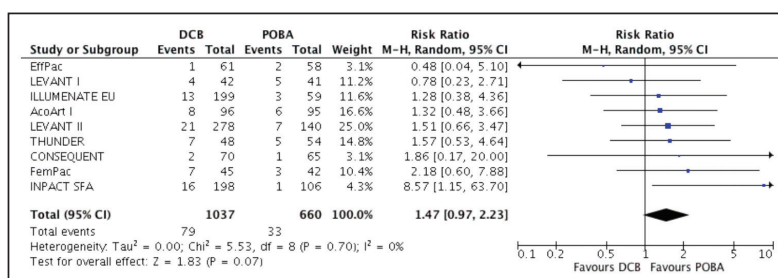


Figure 2. Risk ratio of all-cause death of different DCB RCTs.

drug amount released into the bloodstream is minimal; the drug volume released may be the main effect for increased mortality.

- Teichgräber U, Aschenbach R, Scheinert D, et al. The effectiveness of the paclitaxel-coated Luminor® balloon catheter versus an uncoated balloon catheter in superficial femoral and popliteal arteries in preventing vessel restenosis or reocclusion: study protocol for a randomized controlled trial. *Trials*. 2016;17:1-11. doi: 10.1186/s13063-016-1657-x
- Teichgräber U, Lehmann T, Aschenbach R, et al. Drug-coated balloon angioplasty of femoropopliteal lesions maintained superior efficacy over conventional balloon: 2-year results of the randomized EffPac trial. *Radiology*. 2020;295:478-487. doi: 10.1148/radiol.2020191619
- Tepe G, Schnorr B, Albrecht T, et al. Angioplasty of femoral-popliteal arteries with drug-coated balloons: 5-year follow-up of the THUNDER trial. *JACC Cardiovasc Interv*. 2015;8:102-108. doi: 10.1016/j.jcin.2014.07.023
- Werk M, Langner S, Reinkensmeier B, et al. Inhibition of restenosis in femoropopliteal arteries: paclitaxel-coated versus uncoated balloon: femoral paclitaxel randomized pilot trial. *Circulation*. 2008;118:1358-1365. doi: 10.1161/CIRCULATIONAHA.107.735985

CIRCULATIONAHA.107.735985

- Scheinert D, Duda S, Zeller T, et al. The LEVANT I (Lutonix paclitaxel-coated balloon for the prevention of femoropopliteal restenosis) trial for femoropopliteal revascularization: first-in-human randomized trial of low-dose drug-coated balloon versus uncoated balloon angioplasty. *JACC Cardiovasc Interv*. 2014;7:10-9. doi: 10.1016/j.jcin.2013.05.022
- Laird JR, Schneider PA, Tepe G, et al. Durability of treatment effect using a drug-coated balloon for femoropopliteal lesions: 24-month results of IN.PACT SFA. *J Am Coll Cardiol*. 2015;66:2329-2338. doi: 10.1016/j.jacc.2015.09.063
- Brodmann M, Werner M, Meyer D-R, et al. Sustainable antirestenosis effect with a low-dose drug-coated balloon: the ILLUMINATE European randomized clinical trial 2-year results. *JACC Cardiovasc Interv*. 2018;11:2357-2364. doi: 10.1016/j.jcin.2018.08.034
- Albrecht T, Waliszewski M, Roca C, et al. Two-year clinical outcomes of the CONSEQUENT trial: can femoropopliteal lesions be treated with sustainable clinical results that are economically sound? *Cardiovasc Intervent Radiol*. 2018;41:1008-1014. doi: 10.1007/s00270-018-1940-1
- Xu Y, Jia X, Zhang J, et al. Drug-coated balloon angioplasty compared with uncoated balloons in the treatment of 200 Chinese patients with severe femoropopliteal lesions: 24-month results of AcoArt I. *JACC Cardiovasc Interv*. 2018;11:2347-2353. doi: 10.1016/j.jcin.2018.07.041

## COMPLEX AND LONG LESION MANAGEMENT

By Koen Deloose, MD

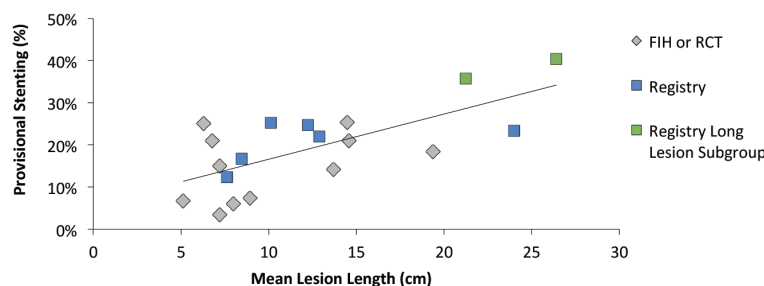


The reality of daily practice is that we are treating more complex lesions—those that are  $\geq 20$  cm, have total occlusions, or are heavily calcified. These vessels have limited vessel/lumen expansion, risk of overstretching nondiseased parts, and a barrier for any drug absorption. The problem is that there is a lack of objective criteria for quantitative calcium measurement. There are different scoring systems to quantify the calcium in the vessels. When there is a bilateral,  $> 180^\circ$  circumference, it is considered as a severely calcified lesion.

Longer mean lesion length correlates with higher provisional stenting rates. At 1 year, with percutaneous transluminal angioplasty and bare-metal stents (BMSs), there is definitely a correlation. This is not an issue with drug-eluting technologies, but necessary and efficient scaffolding must be considered (Figure 3).<sup>1-17</sup>

The use of combined therapies, with a DCB and then a BMS, offers better results in long lesions. This was observed in the TINTIN trial, which investigated the safety and efficacy of treatment with Luminor DCB and the iVolution self-expanding stent (iVascular) in patients with TASC C and D femoropopliteal lesions. At baseline, mean lesion length was 242.65 mm (SD, 73.72 mm).

At 1-year follow-up, combination therapy with Luminor and iVolution achieved a primary patency of



3. Scheinert D. First time data release: Real PTX RCT: 3 year data from a randomized comparison of DCB vs. DES in femoropopliteal lesions. Presented at LINC; January 30-February 2, 2018; Leipzig, Germany.
4. Liistro F, Angioli P, Porto I, et al. Drug-eluting balloon versus drug-eluting stent for complex femoropopliteal arterial lesions: the DRASTICO study. *J Am Coll Cardiol*. 2019;74:205-215. doi: 10.1016/j.jacc.2019.04.057
5. Tepe G. BIOLUX P-III: Passeo-18 Lux all-comers registry: 12-month results for the all-comers cohort. Presented at LINC; January 30-February 2, 2018; Leipzig, Germany.
6. Lichtenberg M, von Bilderling P, Ranft J, et al. Treatment of femoropopliteal atherosclerotic lesions using the ranger paclitaxel-coated balloon catheter: 12-month results from an all-comers registry. *J Cardiovasc Surg (Torino)*. 2018;59:45-50. doi: 10.23736/S0021-9509.17.10261-2
7. Micari A, Cioppa A, Vadalà G, et al. Clinical evaluation of a paclitaxel-eluting balloon for treatment of femoropopliteal arterial disease: 12-month results from a multicenter Italian registry. *JACC Cardiovasc Interv*. 2012;5:331-338. doi: 10.1016/j.jcin.2011.11.010
8. Schmidt A, Piorkowski M, Görner H, et al. Drug-coated balloons for complex femoropopliteal lesions: 2-year results of a real-world registry. *JACC Cardiovasc Interv*. 2016;9:715-724. doi: 10.1016/j.jcin.2015.12.267
9. Thieme M, Von Bilderling P, Paetzel C, et al. The 24-month results of the Lutonix Global SFA registry: worldwide experience with Lutonix drug-coated balloon. *JACC Cardiovasc Interv*. 2017;10:1682-1690. doi: 10.1016/j.jcin.2017.04.041
10. Ansel G. In.Pact Global Registry. Presented at TCT 2015; October 11-15, 2015; San Francisco, California.
11. Schroeder H, Meyer DR, Lux B, et al. Two-year results of a low-dose drug-coated balloon for revascularization of the femoropopliteal artery: outcomes from the ILLUMINATE first-in-human study. *Catheter Cardiovasc Interv*. 2015;86:278-286. doi: 10.1002/ccd.25900
12. Schroeder H, Weber M, Meyer DR, et al. Low-dose paclitaxel-coated versus uncoated percutaneous transluminal balloon angioplasty for femoropopliteal peripheral artery disease: one-year results of the ILLUMINATE European randomized clinical trial (randomized trial of a novel paclitaxel-coated percutaneous angioplasty balloon). *Circulation*. 2017;135:2227-2236. doi: 10.1161/CIRCULATIONAHA.116.026493
13. Bausback Y, Willfort-Ehringer A, Sievert H, et al. Six-month results from the initial randomized study of the ranger paclitaxel-coated balloon in the femoropopliteal segment. *J Endovasc Ther*. 2017;24:459-467. doi: 10.1177/1526602817710770
14. Tepe G, Laird J, Schneider P, et al. Drug-coated balloon versus standard percutaneous transluminal angioplasty for the treatment of superficial femoral and popliteal peripheral artery disease: 12-month results from the IN.PACT SFA randomized trial. *Circulation*. 2015;131:495-502. doi: 10.1161/CIRCULATIONAHA.114.011004
15. Krishnan P, Faries P, Niazi K, et al. Stellarex drug-coated balloon for treatment of femoropopliteal disease: twelve-month outcomes from the randomized ILLUMINATE pivotal and pharmacokinetic studies. *Circulation*. 2017;136:1102-1113. doi: 10.1161/CIRCULATIONAHA.117.028893
16. Rosenfield K, Jaff MR, White CJ, et al. Trial of a paclitaxel-coated balloon for femoropopliteal artery disease. *N Engl J Med*. 2015;373:145-153. doi: 10.1056/NEJMoa1406235
17. Tepe G, Gögebakan Ö, Redlich U, et al. Angiographic and clinical outcomes after treatment of femoro-popliteal lesions with a novel paclitaxel-matrix-coated balloon catheter. *Cardiovasc Intervent Radiol*. 2017;40:1535-1544. doi: 10.1007/s00270-017-1713-2
18. Müller-Hülsbeck S, Keirse Koen, Zeller T, et al. Twelve-month results from the MAJESTIC trial of the Eluvia paclitaxel-eluting stent for treatment of obstructive femoropopliteal disease. *Endovasc Ther*. 2016;23:701-707. doi: 10.1177/1526602816650206
19. Dake MD, Ansel GM, Jaff MR, et al. Paclitaxel-eluting stents show superiority to balloon angioplasty and bare metal stents in femoropopliteal disease: twelve-month Zilver PTX randomized study results. *Circ Cardiovasc Interv*. 2011;4:495-504. doi: 10.1161/CIRCINTERVENTIONS.111.962324
20. Yokoi H, Ohki T, Kichikawa K, et al. Zilver PTX post-market surveillance study of paclitaxel-eluting stents for treating femoropopliteal artery disease in Japan: 12-month results. *JACC Cardiovasc Interv*. 2016;9:271-277. doi: 10.1016/j.jcin.2015.09.035
21. Gray WA, Keirse K, Soga Y, et al. A polymer-coated, paclitaxel-eluting stent (Eluvia) versus a polymer-free, paclitaxel-coated stent (Zilver PTX) for endovascular femoropopliteal intervention (IMPERIAL): a randomised, non-inferiority trial. *Lancet*. 2018;392:1541-1551. doi: 10.1016/S0140-6736(18)32262-1
22. Deloose K. BIOLUX 4EVER: combining Passeo-18 Lux DCB and Pulsar-18 BMS: 12-month results of full cohort. Presented at LINC; January 30-February 2, 2018; Leipzig, Germany.
23. Mwipatayi P. Self-expanding nitinol stents combined with DCB: 12-month follow-up of the DEBAS study. Presented at LINC; January 27-31, 2015; Leipzig, Germany.
24. Deloose K. TINTIN study: Final 12-month data with the combination of Luminor DCB+ SX stent in TASC C and D lesions. Presented at LINC; January 28-30, 2020; Leipzig, Germany.

**Koen Deloose, MD**

Head of Department of Vascular Surgery

AZ Sint Blasius

Dendermonde, Belgium

koen.deloose@telenet.be

*Disclosures: Consultant to iVascular.*