

The Impact of Swirling Flow in Treating Atherosclerosis in the Superficial Femoral Artery

Producing better results in primary stenting and the ideal complement to drug-coated balloons.

BY PETER A. GAINES, MD

Atherosclerosis most frequently affects the superficial femoral artery (SFA), but attempts at recanalization can often be hindered by the high rate of reocclusion. Fortunately, difficulty often leads to inspiration, and the past 5 years will be remembered for innovation in the battle against restenosis after peripheral intervention.

Failure of patency is important not only because it leads to recurrence of symptoms, but also because any further intervention incurs both risk to the patient and financial cost to the health care provider. Much of the research leading to our current understanding of endovascular failure comes from the coronary literature. Lumen loss after angioplasty in coronary arteries typically occurs within the first 12 months and is due to immediate recoil, late negative remodeling (fibrosis of the adventitia), and restenosis. Restenosis is a complex process that is most likely driven by the inflammatory response that follows balloon barotrauma and stent implantation. That inflammatory response results in vascular smooth muscle cell proliferation and migration, extracellular matrix formation, and the development of neointimal hyperplasia.¹

That model of lumen loss, both early and late, lends itself to intervention at several levels. Early recoil and late negative remodeling should benefit from internal support. Stents within the coronary arteries reduced patency failure from up to 50% after angioplasty alone to 20% to 30% after bare-metal stent placement.¹ Similarly within the SFA, contemporary stents have been shown to improve short- to midterm patency.^{2,3}

The most dramatic change, however, has been in our ability to reduce restenosis by either changing the flow characteristics or directly delivering drugs to the vessel wall.

SWIRLING FLOW

It is generally recognized that flow within an artery is laminar. In addition, because of the nonplanar curvature of arteries, flow is also swirling. This results in an increase in the velocity of blood against the vessel wall and a rise in the wall shear stress. It is now recognized that this increased shear stress results in a reduced risk of both atherosclerosis and restenosis.^{4,5}

The BioMimics stent (Veryan Medical Ltd.) has true three-dimensional (3D) helical curvature within the shape memory of the nickel-titanium alloy (nitinol) from which it is formed (Figure 1). The stent imparts nonplanar curvature to the artery that produces swirling flow (Figure 2). Whether this could reduce the risk of restenosis was first tested in a porcine model, where a straight stent was placed in one carotid artery and a helical stent in the other of the same animal. The study demonstrated that the swirling flow generated by the helical stent significantly reduced the development of restenosis and that the degree of curvature matched the reduction in restenosis.⁶

The BioMimics 3D stent was subsequently tested in the first randomized controlled trial to directly compare two nitinol stents in the SFA. The MIMICS trial was a multicenter, core lab-controlled, prospective,




Figure 1. The BioMimics 3D stent.




Figure 2. Computational fluid dynamics demonstrating swirling flow within the BioMimics 3D stent.

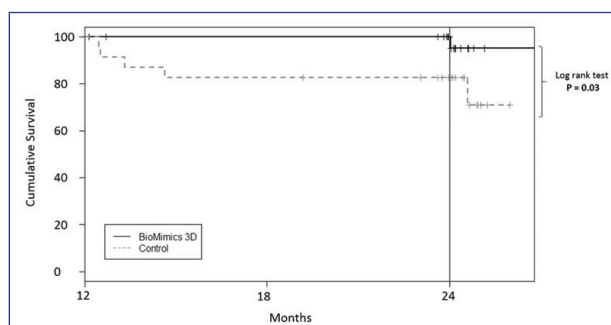


Figure 3. A landmark analysis of the data from the MIMICS trial demonstrating no CD-TLR in the BioMimics 3D arm, but ongoing CD-TLR in the control (straight nitinol stent) arm. This difference is significant, $P = .0263$.

randomized trial in which the BioMimics 3D stent was compared with a conventional straight stent control (LifeStent, Bard Peripheral Vascular, Inc.) in 76 patients with symptomatic occlusive disease of the SFA and proximal popliteal arteries.⁷ Conventional radiographs and angiography confirmed that the BioMimics 3D stent imparts nonplanar curvature to the diseased artery. Compared with a straight stent control, the BioMimics 3D stent had significantly better primary patency at 2 years. There was no change in clinically driven target lesion revascularization (CD-TLR) in the BioMimics 3D arm between 12 and 24 months, whereas there was a threefold increase in CD-TLR in the straight stent control arm over the same period—a significant difference between the two stents (Figure 3).

DRUG-COATED BALLOONS

Current drug-coated balloons (DCBs) use paclitaxel, a powerful antiproliferative drug, to address the biological mechanisms leading to restenosis. The drug is combined with an excipient to provide uniform dosage and rapid transfer of the drug. Variations in the excipient, formulation, and dosage of the paclitaxel result in the different behavior of the individual DCBs.

The pivotal trials showed improved performance over simple angioplasty, but this was in a well-defined set of lesions and the importance of that, in terms of generalizability of DCBs' value, deserves some attention.⁸⁻¹² Severe calcification and an inability to completely predilate the lesion were exclusions in these studies and effectively removed those lesions from any analysis. Furthermore, because only 12% to 26% of lesions were total occlusions, this noncalcified simple disease was unlikely to recoil after angioplasty, resulting in a bailout stent rate of only 2.5% to 7%. When the same DCBs are used in more routine clinical practice and documented within the global registries, the lesion patency and CD-TLR rates remain good. This is because these more clinically generalizable cohorts are measuring the outcome of DCB plus stent. This everyday disease is more complex than those recruited to the pivotal trials, resulting in an average stent rate of 28% to 35.5%. The stent rate is clearly related to both lesion length and the chronic total occlusion rate. In the IN.PACT Global study for instance, when the lesion length exceeds 25 cm, the stent rate is 53%, and the stent rate for total occlusions is 47%.

The Kaplan-Meier patency curves from the pivotal trials demonstrate that the improvement in patency and reduction in CD-TLR versus angioplasty alone occur between 6 and 12 months, but after this time, the attrition rate is the same. This continued attrition is also seen in the global registries.

THE POTENTIAL BENEFIT OF COMBINING SWIRLING FLOW WITH DCB

There are clear limitations to the use of DCBs in the SFA: a DCB-only approach is not appropriate to clinical practice outside pivotal trials. Although the bailout stent rate was low in the pivotal trials, the global registries demonstrate that a much higher use of stents is required to maintain high patency and low CD-TLR rates.

Loss of patency is a combination of recoil, late negative remodeling, and restenosis. DCBs alone clearly do not provide the scaffolding that a stent can to overcome recoil and remodeling. Indeed, DCBs were intentionally tested in an environment that would avoid likely recoil; lesions were short, and both calcified lesions and lesions that demonstrated recoil after the initial predilatation were excluded in the pivotal trials.

The antiproliferative effects are necessarily time limited, yet contemporary data show that loss of patency due to restenosis in the SFA occurs out to 3 to 4 years.¹³ Something other than the drug is required to affect these late events.

It would therefore appear that in common clinical practice, a stent is required in a significant proportion of DCB-treated lesions. If a stent is used to support a DCB, it would appear sensible to use a device with good outcomes that would not only provide the scaffolding that DCB-only therapy lacks, but also could extend the period of low CD-TLR past the initial 12 months when DCBs are effective. The BioMimics 3D stent has been demonstrated in a randomized controlled trial to have a better patency and a reduced CD-TLR rate when compared with a straight nitinol stent. Furthermore, as there was no CD-TLR between 12 and 24 months in the BioMimics 3D arm of the randomized controlled trial, this suggests that the use of a proven DCB and BioMimics 3D stent might be the ideal combination.

CONCLUSION

Both swirling flow and the use of antiproliferative drugs are effective at maintaining patency by inhibiting neointimal hyperplasia through complementary mechanisms. In the management of routine disease with variably complex morphology, the use of a DCB with the BioMimics 3D stent would appear to extend the prospect for durable clinical outcomes with benefit for both patient and health system costs. ■

PAM 134, Issue 02. BioMimics 3D is manufactured by Veryan Medical Ltd. BioMimics 3D is CE Marked. In the United States and Japan, BioMimics 3D is an investigational device limited by Federal (or United States) law to investigational use.

1. Jukema JW, Verschuren JJ, Ahmed TA, Quax PH. Restenosis after PCI. Part 1: pathophysiology and risk factors. *Nat Rev Cardiol.* 2011;9:53-62.
2. Laird JR, Katzen BT, Scheinert D, et al. Nitinol stent implantation vs. balloon angioplasty for lesions in the superficial femoral and proximal popliteal arteries of patients with claudication: three-year follow-up from the RESILIENT randomized trial. *J Endovasc Ther.* 2012;19:1-9.
3. Schillinger M, Sabeti S, Loewe C, et al. Balloon angioplasty versus implantation of nitinol stents in the superficial femoral artery. *N Engl J Med.* 2006;354:1879-1888.
4. Caro CG. Discovery of the role of wall shear in atherosclerosis. *Arterioscler Thromb Vasc Biol.* 2009;29:158-161.
5. Carlier SG, van Damme LC, Blommerde CP, et al. Augmentation of wall shear stress inhibits neointimal hyperplasia after stent implantation: inhibition through reduction of inflammation? *Circulation.* 2003;107:2741-2746.
6. Shinke T, Robinson K, Burke MG, et al. Novel helical stent design elicits swirling blood flow pattern and inhibits neointima formation in porcine carotid arteries. *Circulation.* 2008;118:S1054.
7. Zeller T, Gaines PA, Ansel GM, Caro CG. Helical centerline stent improves patency: two-year results from the randomized mimics trial. *Circ Cardiovasc Interv.* 2016;9:e002930.
8. Tepe G, Laird J, Schneider P, et al. Drug-coated balloon versus standard percutaneous transluminal angioplasty for the treatment of superficial femoral and/or popliteal peripheral artery disease: 12-month results from the IN.PACT SFA randomized trial. *Circulation.* 2014;131:495-502.
9. Laird JR, Schneider PA, Tepe G, et al. Durability of treatment effect using a drug-coated balloon for femoropopliteal lesions: 24-month results of IN.PACT SFA. *J Am Coll Cardiol.* 2015;66:2329-2338.
10. Scheinert D, Schulte KL, Zeller T, et al. Paclitaxel-releasing balloon in femoropopliteal lesions using a BTHC excipient: twelve-month results from the BIOLUX P-I randomized trial. *J Endovasc Ther.* 2015;22:14-21.
11. Schroeder H, Meyer DR, Lux B, et al. Two-year results of a low-dose drug-coated balloon for revascularization of the femoropopliteal artery: outcomes from the ILLUMINATE first-in-human study. *Catheter Cardiovasc Interv.* 2015;86:278-286.
12. Rosenfield K, Jaff MR, White CJ, et al. Trial of a paclitaxel-coated balloon for femoropopliteal artery disease. *N Engl J Med.* 2015;373:145-153.
13. Iida O, Uematsu M, Soga Y, et al. Timing of the restenosis following nitinol stenting in the superficial femoral artery and the factors associated with early and late restenoses. *Catheter Cardiovasc Interv.* 2011;78:611-617.

Peter A. Gaines, MD

Professor

Sheffield Hallam University

Sheffield, United Kingdom

Disclosures: Consultant to Veryan Medical Ltd.