

# S.M.A.R.T.® Flex Vascular Stent System: Two-Year Experience in Treating Femoropopliteal Lesions

BY ENRICO MARIA MARONE, MD

Endovascular treatment for peripheral artery disease (PAD) caused by lesions of the superficial femoral artery (SFA) and the first segment of the popliteal artery (P1) has reached outcomes comparable with surgical reconstruction.<sup>1</sup> In selected patients, good outcomes are possible because of the use of percutaneous transluminal angioplasty (PTA) in combination with stenting, which has higher efficacy than simple balloon angioplasty,<sup>2</sup> as well as the capability of new-generation stents to withstand all types of mechanical stress, which is particularly high in the femoropopliteal region. In fact, the SFA and the P1 segment are exposed to different forces transmitted by the movements of the leg and hip. The simple act of walking causes shortening of 13.9% and twisting of 3.5°/cm in the distal SFA and P1,<sup>3</sup> which can favor stent displacement, kinking, fracture, and restenosis. For these reasons, balloon-expandable stents performed poorly in the femoropopliteal region as compared with other regions,<sup>4</sup> due to high in-stent restenosis and fracture rates.

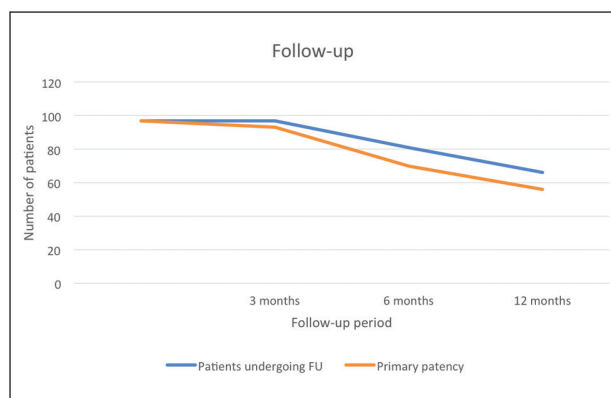
Only with the launch of nitinol self-expanding stents in 2009 could endovascular treatment of the SFA and popliteal artery achieve satisfying results, with an acceptable 1-year patency rate.<sup>5</sup> Self-expanding stents, along with drug-eluting stents and stent grafts, are now recommended in the treatment of SFA and P1 lesions, especially if they are long and calcified and if there is a high risk of restenosis. Retrospective clinical trials conducted over the last few years have shown the superior effectiveness of these devices in treating SFA and P1 lesions in patients with Trans-Atlantic Inter-Society Consensus (TASC II) C and D lesions compared with PTA or balloon-expandable stents, and their use allowed endovascular treatment to be extended to a wider population unfit for

surgical revascularization and who would otherwise be untreated.<sup>6-8</sup>

The effectiveness and feasibility of endovascular treatment in the femoropopliteal region depends on the mechanical characteristics of the stents used, namely resistance to axial and radial compression, response to torsion, flexibility, and, most importantly, resistance to fracture.<sup>9</sup> Moreover, the mechanical interaction between the arterial wall and the stent structure should be as atraumatic as possible to prevent arterial wall dissections.

## FEATURES OF THE S.M.A.R.T.® FLEX VASCULAR STENT SYSTEM

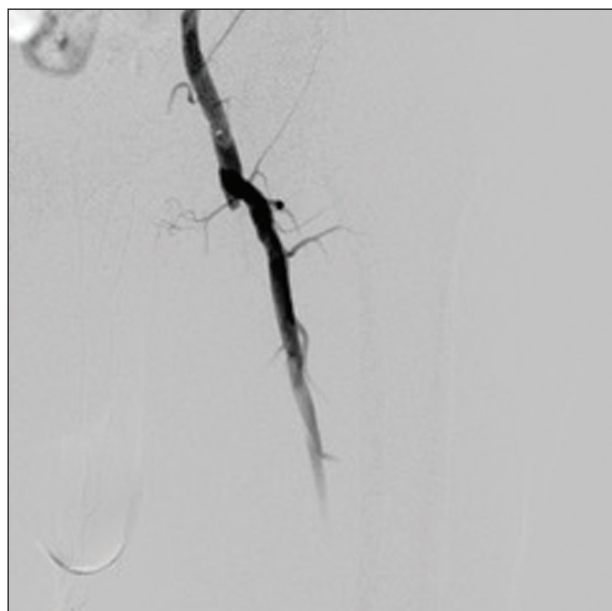
The S.M.A.R.T.® Flex Vascular Stent System (Cordis, a Cardinal Health company) is a nitinol self-expanding bare-metal stent with a unique structure that makes it particularly suited for the femoropopliteal region. It is made up of fully connected, laser-cut tubes of nitinol, providing a remarkable longitudinal stability and preventing displacement. Benchtop mechanical comparative tests have assessed its high resistance to radial compression (600 N/m) and torsion. Moreover, its structure provides the optimal balance between flexibility, which is necessary to accommodate bending and extension movements of the limb, and stiffness, which prevents stent fracture or collapse. The helical strut bands allow for an atraumatic interaction between the stent and vessel wall.<sup>9</sup> These advantages have allowed for a widespread utilization of this device, with a high technical success rate and low rate of complications caused by exposure to mechanical stress (in-stent restenosis, occlusion, displacement, buckling, fracture). Its clinical effectiveness has been described by other authors, although follow-up is relatively short (3 months).<sup>10,11</sup>



**Figure 1.** Results showed a primary patency rate of 95.9% after 3 months and 84.8% after 12 months.

### CLINICAL EXPERIENCE

We retrospectively evaluated the outcomes of the S.M.A.R.T.® Flex Vascular Stent System in our single center over 2 years. Between January 2016 and September 2017, we treated 97 lower limbs (91 in SFA and six in P1 popliteal artery) in 92 patients, with 110 S.M.A.R.T.® Flex Vascular Stent Systems. The treated lesions ranged from TASC II B to D. Technical success was achieved in all cases, with no early postoperative major complications. Postoperative angiograms revealed no kinking, displacement, or buckling. Minor complications (ie, hematoma, pseudoaneurysm) at the site of access occurred in three cases. Each patient underwent color Doppler follow-up at 3, 6, and 12 months after the procedure.



**Figure 2.** Preoperative angiogram showing occlusion of the SFA.

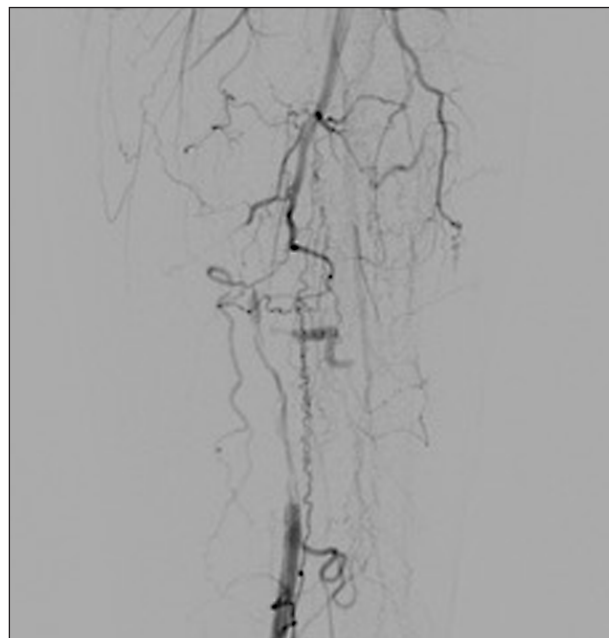
At 3 months, the patency rate was 95.9% (93 lower limbs). Occlusions were due to in-stent thrombosis and occurred in patients not responding to clopidogrel. No cases of stent fracture were observed. Target lesion revascularization after an average follow-up period of 12 months was 15.2% (10 patients out of the 66 patients currently undergoing 12-month follow-up; Figure 1).

In three cases, the stent was successfully utilized to treat bypass occlusion after Fogarty thrombectomy and/or thromboaspiration; in these cases, the stents were placed at the distal anastomosis of femoropopliteal bypass.

### CASE EXAMPLE

A 58-year-old man with hypertension and a history of smoking and alcohol abuse was admitted to the vascular surgery unit for 6 months of critical limb ischemia (CLI) of the left lower limb. Computed tomographic angiography showed a 25-cm-long occlusion of the left SFA from its origin to the adductor canal, with a patent popliteal artery and occlusion of the anterior tibial artery at the proximal third.

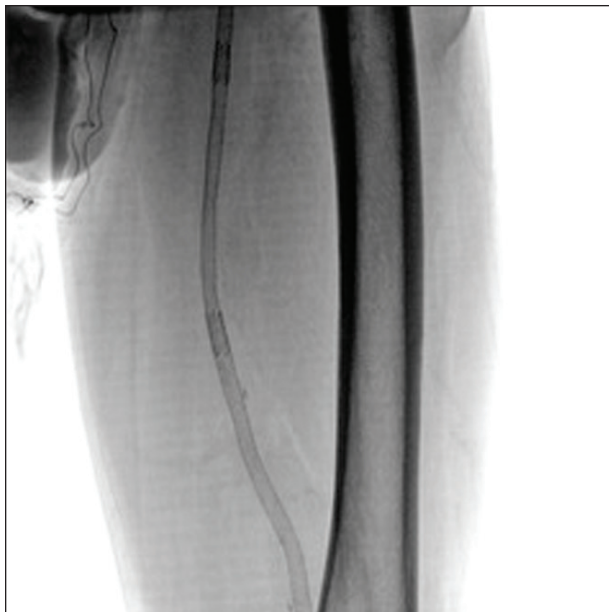
The patient was treated endovascularly via percutaneous retrograde right femoral artery access. A 6-F X 45-cm Flexor® Introducer Sheath (Cook Medical) was inserted and placed in the left common femoral artery. Control angiography confirmed the occlusion of the SFA with distal reperfusion at the level of the adductor canal (Figure 2). The SFA was reopened subintimally; after reentry into the lumen, the length of the SFA was treated with angioplasty (6- X 100-mm POWERFLEX™ Pro PTA Catheter,



**Figure 3.** Preoperative angiogram of the distal SFA.

## S.M.A.R.T.® FLEX VASCULAR STENT SYSTEM

Sponsored by Cordis, a Cardinal Health company



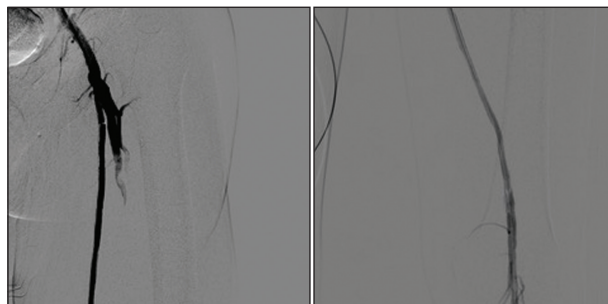
**Figure 4.** The S.M.A.R.T.® Flex Vascular Stent System deployed in the SFA.

Cordis, a Cardinal Health company). Angiography revealed postangioplasty recoil and multiple dissections hindering the blood flow. Thus, the SFA was stented from the origin to the supragenicular popliteal artery with two 6- X 100-mm and one 6- X 120-mm S.M.A.R.T.® Flex Vascular Stent Systems. The final angiographic control showed direct flow to the distal posterior tibial artery (Figures 3–5).

The postprocedural course was uncomplicated, and the patient was discharged on first postoperative day with resolution of CLI. Follow-up at 3 and 6 months showed patency of the femoropopliteal axis with no complications such as stent fracture, displacement, buckling, or in-stent restenosis.

## CONCLUSION

Our results using the S.M.A.R.T.® Flex Vascular Stent System show a 95.9% patency rate after 3 months and 84.8% after 12 months. This outcome is superior to the midterm outcome of SFA stenting described in the literature (66% primary patency at 12 months).<sup>5</sup> Our experience confirms the resistance and durability of the S.M.A.R.T.® Flex Vascular Stent System and its capability to withstand the forces of strain, compression, and torsion caused by limb movements. No case of stent fracture was observed through follow-up. This also makes the S.M.A.R.T.® Flex Vascular Stent System particularly fit for secondary revascularization in patients with occluded femoropopliteal bypass, as shown in our case example and as reported by Yanaguchi et al.<sup>12</sup> These characteristics



**Figure 5.** Postoperative angiogram showing revascularization of the SFA after stenting.

not only guarantee effective restoration of the blood flow through the femoropopliteal region with no early postoperative complications, but they also allow the results to be maintained over a relatively long follow-up period (1 year on average).

These outcomes should be confirmed by further studies with a larger number of patients, but they are extremely encouraging, and they represent a valuable solution to the major concern about endovascular treatment of the femoropopliteal axis, specifically the risk of compression and displacement of the stent due to hip and leg movements. ■

1. Antoniou GA, Chalmers N, Georgiadis GS, et al. A meta-analysis of endovascular versus surgical reconstruction of femoropopliteal arterial disease. *J Vasc Surg.* 2013;57:242–253.
2. Becquemin JP, Favre JP, Marzelle J, et al. Systematic versus selective stent placement after superficial femoral artery balloon angioplasty: a multicenter prospective randomized study. *J Vasc Surg.* 2003;37:487–494.
3. Ansari F, Lindsay KP, Steven SB, Morrison TM. Design considerations for studies of the biomechanical environment of the femoropopliteal arteries. *J Vasc Surg.* 2013;58:804–813.
4. Katsanos K, Spiliopoulos S, Karunanithy N, et al. Bayesian network meta-analysis of nitinol stents, covered stents, drug-eluting stents, and drug-coated balloons in the femoropopliteal artery. *J Vasc Surg.* 2014;59:1123–1133.
5. Schneider PA. Evolution and current use of technology for superficial femoral and popliteal artery interventions for claudication. *J Vasc Surg.* 2017;66:916–923.
6. Laird JR, Jain A, Zeller T, et al. Nitinol stent implantation in the superficial femoral artery and proximal popliteal artery: twelve-month results from the complete SE multicenter trial. *J Endovasc Ther.* 2014;21:202–212.
7. Bosiers M, DeLoose K, Callaert J, et al. Results of the Protégé EverFlex 200-mm-long nitinol stent (ev3) in TASC C and D femoropopliteal lesions. *J Vasc Surg.* 2011;54:1042–1050.
8. Dake MD, Ansel GM, Jaff MR, et al. Paclitaxel-eluting stents show superiority to balloon angioplasty and bare metal stents in femoropopliteal disease: twelve-month Zilver PTX randomized study results. *Circ Cardiovasc Interv.* 2011;4:495–504.
9. Maleckis K, Deegan P, Poulson W, et al. Comparison of femoropopliteal artery stents under axial and radial compression, axial tension, bending, and torsion deformations. *J Mech Behav Biomed Mater.* 2017;75:160–168.
10. Goverde P, Taeymans K, Lauwers K. The S.M.A.R.T. Flex vascular stent system solution. *Endovasc Today Europe.* 2014;2:24–27.
11. Piacentini F, Marone E, Castelli P, et al. The S.M.A.R.T. Flex vascular stent system: experience and outcomes in two Italian centers of excellence. *Endovasc Today Europe.* 2015;3:67–69.
12. Yanaguchi T, Kimura M, Shiraishi J, Sawada T. Endovascular treatment for infra-inguinal autologous saphenous vein graft occlusion using self-expanding nitinol stents. *EJVES Short Rep.* 2016;30:16–19.

## Enrico Maria Marone, MD

Associate Professor of Vascular Surgery  
University of Pavia  
Fondazione IRCCS Policlinico  
San Matteo, Pavia, Italy  
*Disclosures: None.*