

CASE REPORT

Efficient Removal of Lower Extremity Arterial Thrombus With the Pounce™ Thrombectomy System

By Joseph Griffin, MD, RVT, FACS

Patient Presentation

A 46-year-old woman with borderline hypertension and diabetes noticed her right leg suddenly became cold and numb and caused her to fall to the ground while walking. She immediately called an ambulance and was brought to the hospital.

Diagnostic Findings

Upon an initial consultation, the patient was deemed to have a bounding 4+ pulse of the right common femoral artery (CFA) with nonpalpable pulses of the right popliteal and pedal arteries along with a normal left-sided pulse examination. Her ankle-brachial index values were 0.34 on her right and 1.0 on her left, and the remaining clinical examination was otherwise normal. She was started on a heparin drip and brought into the cath lab.

Her left CFA was accessed using an ultrasound puncture technique. An angiogram was taken utilizing a 5 Fr sheath with 5 Fr Accu-Vu Omni™ Flush sizing catheter and a .035 stiff angled Glidewire™. Initial imaging showed an embolus at the distal CFA, occluding the profunda and superficial femoral artery (SFA). There was a large amount of embolic burden in the proximal and mid SFA with a secondary occlusive embolus at the location of the tibial trifurcation (Figure 1), with the distal SFA and popliteal artery remaining patent.

Treatment

The initial strategy was to use the 50 cm treatment zone EKOS™ Endovascular System and perform catheter-directed thrombolysis. The 5 Fr diagnostic sheath was exchanged for a 6 Fr, 45 cm length Pinnacle® Destination® Guiding Sheath. The distal tip of the EKOS™ catheter was placed in the mid posterior tibial artery and the proximal end within the CFA. Catheter-directed thrombolysis was then performed. The patient was admitted to the intensive care unit with a 1 mg/min tissue plasminogen activator (tPA) drip overnight. The patient was reexamined 24 hours later, and a repeat angiogram was obtained. There was minor improvement in the SFA and profunda artery. The popliteal artery also had minor

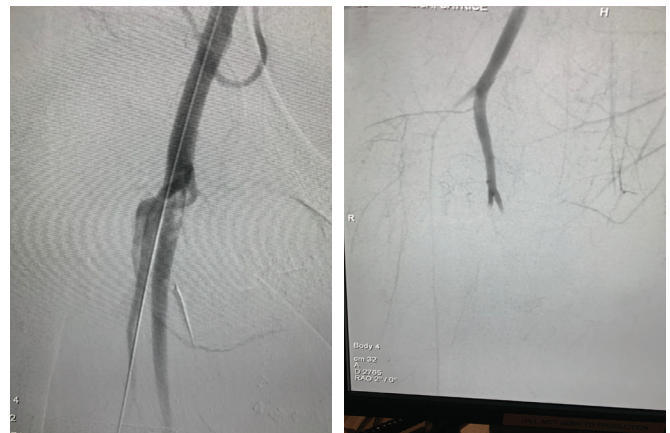

Figure 1. Baseline angiograms showing embolic burden in the SFA and secondary embolus in the tibial trifurcation.

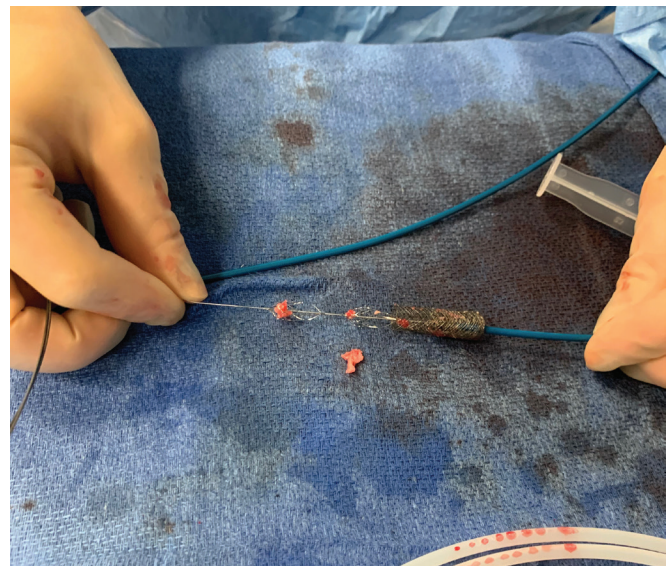


Figure 2. Embolus removed from the SFA. (Used with permission of the author.)

GRAB. GO. RESTORE FLOW.

How the Pounce™ Thrombectomy System Is Redefining Thrombus and Embolus Removal

Sponsored by  SURMODICS

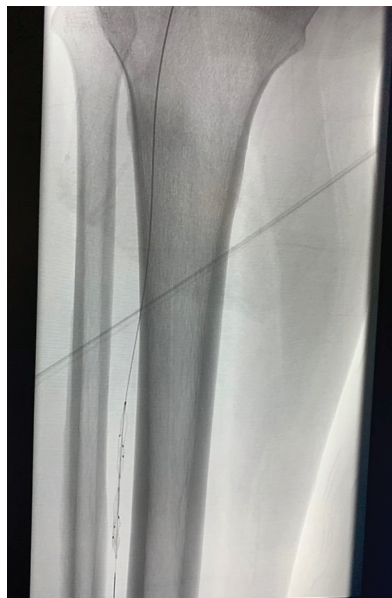

Figure 3. Pounce™ System baskets in distal posterior tibial artery.

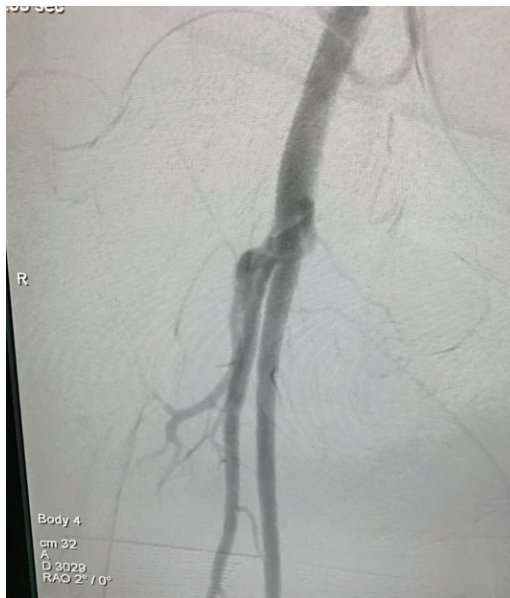

Figure 4. Patent SFA and profunda artery.

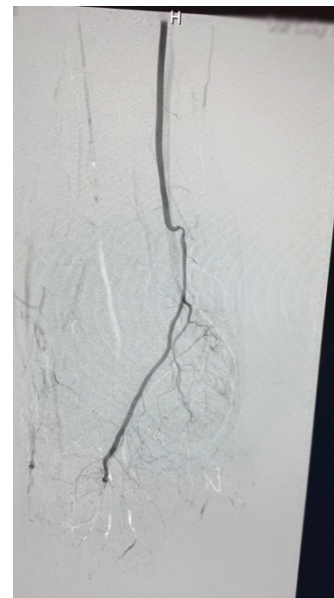


Figure 5. Patent peroneal and posterior tibial runoff into the foot.

improvement, while the three tibial vessels were still occluded at the trifurcation. Therefore, the patient was continued on tPA for another 24 hours at 1 mg/min across the various occluded vessel segments. At the 48-hour mark, repeat angiography showed no improvement.

A 6 Fr QuickClear™ Mechanical Thrombectomy System was passed into the profunda and was able to clear out the thrombus. The device was then passed three times through the SFA but was not able to remove the embolus. The physician was in-serviced on the Pounce™ Thrombectomy System for the first time.

The procedural sheath was upsized to a 7 Fr, 45 cm Pinnacle® Destination® Guiding Sheath. The basket wire was placed in the mid SFA via the delivery catheter, and the funnel catheter was placed in the distal CFA. The baskets were pulled back into the funnel, collecting the entire residual embolus in the SFA, and the device assembly was removed from the body through the procedural guide sheath (Figure 2). The peroneal artery was then wired, the basket wire was placed in the mid peroneal artery, and the funnel catheter was placed in the distal popliteal artery. After a single pull of the basket wire, the thrombus was successfully removed. Finally, the posterior tibial artery was cannulated, the basket wire was placed in the distal posterior tibial artery (Figure 3), and the funnel catheter was placed in the distal popliteal artery. After one pull, the thrombus in the posterior tibial artery was removed.

Post Procedure Outcome

A final angiogram was taken to show patency of the profunda, SFA (Figure 4), peroneal, and posterior tibial arteries with runoff into the foot (Figure 5).

After alternative technology and thrombolysis were unsuccessful, the simplicity of the Pounce™ Thrombectomy System allowed the physician to quickly learn the system and clear out three vessels on three separate passes. Because of the patient's morbid obesity, the physician wanted to avoid open embolectomy and subsequent surgical incisions breakdowns and infections. Without the Pounce™ Thrombectomy System, the patient would have been sent to the operating room, given that all other options had failed to remove the obstruction. The Pounce™ Thrombectomy System was able to efficiently and quickly remove the organized clot burden, helping to avoid additional tPA administration as well as providing a durable alternative to open embolectomy. ■



Joseph Griffin, MD, RVT, FACS
Board-Certified General/Vascular Surgeon
Vascular Specialty Center
Baton Rouge, Louisiana
Disclosures: Surmodics.

Caution: Federal (US) law restricts the Pounce™ Thrombectomy System to sale by or on the order of a physician. Please refer to Instructions for Use for indications, contraindications, warnings, and precautions.

SURMODICS, POUNCE, and SURMODICS and POUNCE logos are trademarks of Surmodics Inc. and/or its affiliates. Third-party trademarks are the property of their respective owners.