

New Aortic Dissection Classification and Practical Real-World Applications

A summary of updated reporting language from the Society for Vascular Surgery and Society of Thoracic Surgeons for type B aortic dissection.

By Joseph V. Lombardi, MD, and G. Chad Hughes, MD

The Society for Vascular Surgery (SVS) and Society of Thoracic Surgeons (STS) recently published a joint document on reporting standards for type B aortic dissection (TBAD).¹

The purpose of the updated reporting standards was to establish a standardized language for presentation, anatomy, and procedural and postoperative follow-up in manuscripts describing patients treated for TBAD. Both the SVS and STS were represented by seven members including co-chairs from each society. This article summarizes the updated reporting language established by the SVS/STS.

SVS/STS DISSECTION CLASSIFICATION SYSTEM

Chronicity and Anatomic Classification

The SVS/STS reporting standards document is categorized according to the various stages of a patient's management from presentation to long-term follow-up. The chronicity classification now ranges from hyperacute to chronic, where chronic dissection now includes patients with > 90 days spanning their initial presentation (it previously was 14-90 days) (Table 1). Among the many changes to convention and suggestions, the most pivotal contribution of this work is the introduction of the SVS/STS Dissection Classification System. This classification scheme now allows the aorta to be described in detail and with ease, while keeping in mind the current novel operative techniques, includ-

TABLE 1. SVS/STS CHRONICITY CLASSIFICATION FOR AORTIC DISSECTION

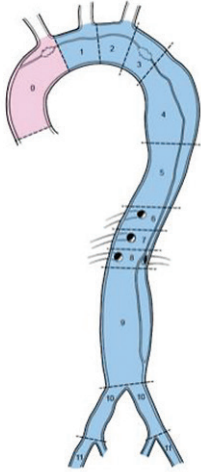
Chronicity Classification	Time From Symptom Onset
Hyperacute	< 24 h
Acute	1-14 d
Subacute	15-90 d
Chronic	> 90 d

Abbreviations: STS, Society for Thoracic Surgery; SVS, Society of Vascular Surgery. Reprinted from Journal of Vascular Surgery, 71/3, Lombardi JV, Hughes GC, Appoo JJ, et al, Society for Vascular Surgery (SVS) and Society of Thoracic Surgeons (STS) reporting standards for type B aortic dissections, 723-747, 2020, with permission from Elsevier.

ing endovascular management. The classification uses entry tear location to determine a type A versus type B dissection, and subscripts denote the proximal and distal extent of the dissection process, including areas of intramural hematoma (Figure 1).

Acuity Classification

The patient's presentation in terms of acuity has been categorized into uncomplicated (patient without high-risk criteria), high risk, and complicated (rupture and malperfusion) (Table 2). It was felt the use of the term uncomplicated in the past was variable and loose-



Type	Proximal Extent	Distal Extent
A_D	0	0
Entry tear: Zone 0	1	1
	2	2
	3	3
B_{PD}	4	4
Entry tear: ≥ Zone 1	5	5
	6	6
	7	7
	8	8
I_D	9	9
Unidentified entry tear involving Zone 0	10	10
	11	11
	12	12

Figure 1. Anatomic reporting of aortic dissection based on the SVS/STS reporting standards. Reprinted from Journal of Vascular Surgery, 71/3, Lombardi JV, Hughes GC, Appoo JJ, et al, Society for Vascular Surgery (SVS) and Society of Thoracic Surgeons (STS) reporting standards for type B aortic dissections, 723-747, 2020, with permission from Elsevier.

ly applied in high-risk situations where comparisons could not be accurately made from one manuscript to another. Hence, a third “high risk” category was added such that investigations on operative versus conservative management can be better communicated and compared to glean accurate clinical guidelines.

False Lumen Reporting

Patency of the false lumen was adjusted to reference the entire aorta in its description. A patent false lumen is defined as flow present throughout the entire aortic false lumen on arterial phase or delayed contrast imaging. Partial thrombosis is defined as clot within the aortic false lumen but with a residual patent flow channel on arterial phase or delayed contrast imaging. Complete thrombosis is defined as complete thrombosis of the aortic false lumen on arterial and delayed phase imaging.

Further descriptions of the false lumen are sources of persistent flow. What was commonly referred to as *endoleak*, a term used in the context of endovascular aneurysm repair, is now *entry flow*, which physiologically better describes the various sources of flow back into the false lumen. There are three types of entry flow described: type 1, type 2, and type R. Type 1 is subclassified into type 1a and type 1b, representing flow into the false lumen from proximal and distal seal zones, respectively. Invariably, type 1b entry flow represents a stent graft–induced entry tear. Type 2

TABLE 2. SVS/STS CATEGORIZATION OF PRESENTING SYMPTOMS AND SIGNS FOR AORTIC DISSECTION

Uncomplicated

- No rupture
- No malperfusion
- No high-risk features

High risk

- Refractory pain
- Refractory hypertension
- Bloody pleural effusion
- Aortic diameter > 40 mm
- Radiographic-only malperfusion
- Readmission
- Entry tear: Lesser curve location
- False lumen diameter > 22 mm

Complicated

- Rupture
- Malperfusion

Abbreviations: STS, Society for Thoracic Surgery; SVS, Society of Vascular Surgery. Reprinted from Journal of Vascular Surgery, 71/3, Lombardi JV, Hughes GC, Appoo JJ, et al, Society for Vascular Surgery (SVS) and Society of Thoracic Surgeons (STS) reporting standards for type B aortic dissections, 723-747, 2020, with permission from Elsevier.

entry flow is via the arch vessel branches (innominate, carotid, subclavian) or thoracic bronchial/intercostal arteries into the false lumen. Type R entry flow is from the intercostal arteries, visceral or renal arteries, lumbar arteries, iliac branches, or septal fenestrations (Figure 2).

Aortic Remodeling

Aortic remodeling was also a buzzword that needed refinement in definition. Changes in the aorta over time can be defined as positive or negative aortic remodeling and must describe the entire aorta, not just the area in which a stent graft has been placed. Positive aortic remodeling is defined as either (1) false lumen reduction in maximal diameter or volume and no growth in total aortic diameter or volume; (2) true lumen expansion in maximal diameter or volume and no growth in total aortic diameter or volume; or (3) total aortic maximal diameter reduction with variable changes in true and false lumen diameters. Negative aortic remodeling would represent the opposite behaviors or a failure to demonstrate any of these descriptions.

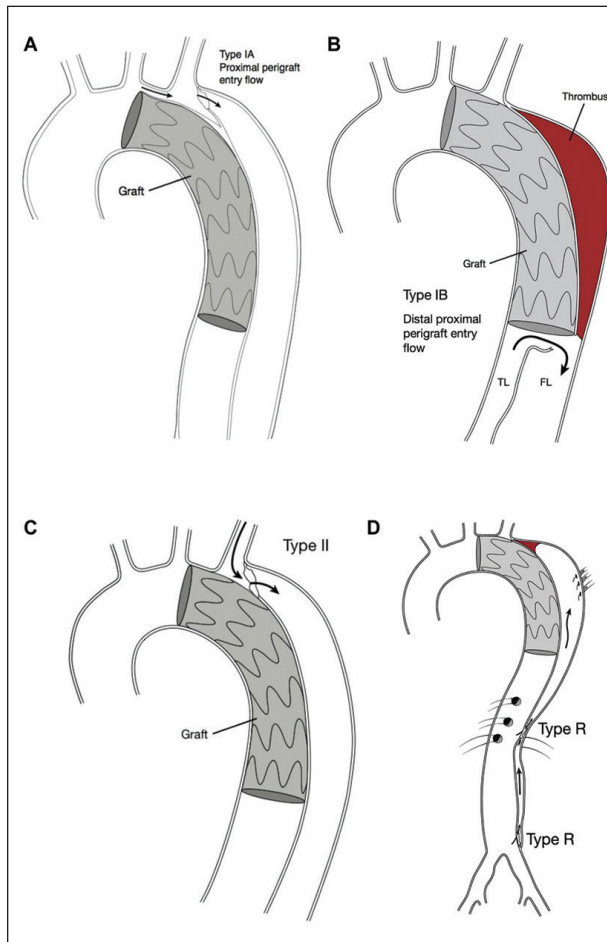


Figure 2. Various modes of entry flow into the false lumen. Reprinted from *Journal of Vascular Surgery*, 71/3, Lombardi JV, Hughes GC, Appoo JJ, et al, Society for Vascular Surgery (SVS) and Society of Thoracic Surgeons (STS) reporting standards for type B aortic dissections, 723-747, 2020, with permission from Elsevier.

SUMMARY

In addition to the aforementioned updates, the SVS/STS reporting standards document also covers end-organ ischemia (spinal, visceral, stroke), etiologies, outcome, and complication reporting with suggestions on imaging protocols. Before final approval, the document was vetted by both societies, its members during a public feedback period, and the FDA. Early adoption of these reporting standards will ensure a robust body of work for comparison from manuscript to manuscript. ■

1. Lombardi JV, Hughes GC, Appoo JJ, et al. Society for Vascular Surgery (SVS) and Society of Thoracic Surgeons (STS) reporting standards for type B aortic dissections. *J Vasc Surg.* 2020;71:723-747. doi: 10.1016/j.jvs.2019.11.013

Joseph V. Lombardi, MD

Head, Division of Vascular and Endovascular Surgery
Professor of Surgery
Cooper Medical School of Rowan University
Director, Cooper Aortic Center
Cooper University Health Care
Camden, New Jersey
lombardi-joseph@cooperhealth.edu
Disclosures: None.

G. Chad Hughes, MD

Director, Duke Center for Aortic Disease
Surgical Director, Duke Center for Structural Heart Disease
Associate Professor with tenure
Division of Thoracic and Cardiovascular Surgery
Duke University Medical Center
Durham, North Carolina
gchad.hughes@duke.edu
Disclosures: None.

Endovascular
—TODAY—

FOLLOW
ENDOASCULAR TODAY
ON TWITTER

 @EVTODAY