

The Rise of Transradial Access for Embolization

A look at the factors that make TRA an attractive option for use in embolization procedures and tips for successful outcomes.

BY KAMIL ARIF, MD; ANDREW J. GUNN, MD; AND KEITH J. PEREIRA, MD

Transradial access (TRA) was initially described in 1989 and has been increasingly employed in transcatheter coronary procedures worldwide over the past 30 years.^{1,2} Meta-analyses of large-scale, randomized, multicenter clinical trials published in the cardiology literature—including RIVAL, MATRIX, RIFLE-STEACS, and STEMI-RADIAL—demonstrate statistically significant reductions in all-cause mortality, access site complications, and bleeding complications with TRA as compared with transfemoral access (TFA).^{3,4} Per American Heart Association guidelines, TRA is now recommended as the default access approach for percutaneous coronary intervention in patients with acute coronary syndrome.³ More recently, interventional radiologists are increasingly using TRA for noncoronary endovascular procedures. For example, in a large, prospective cohort of > 1,500 cases, Posham et al concluded that TRA was safe and well tolerated across a range of peripheral vascular interventions with a technical success rate of 98.2% and overall complication rate of approximately 2.5%.⁵

WHY RADIAL?

Compared with the femoral artery, the radial artery is superficial, without surrounding critical structures susceptible to injury. Furthermore, because the hand has a dual blood supply, it is significantly less detrimental if inadvertent injury to the radial artery occurs. Because the radial artery is easily compressible, there is decreased incidence of access site complications, and hemostasis can be readily achieved without introducing a vascular closure device.² Patients can ambulate quicker and the resultant shorter patient recovery time can result in faster patient throughput in the hospital and discharge times.² This is especially relevant for procedures that have traditionally required overnight admission, such as uterine fibroid embolization (UFE) (Figure 1). TRA helps to convert many such procedures to outpatient procedures, resulting in overall decreased hospital length of stay and cost savings to the health care system.⁶

Apart from this, there are several specific situations in which TRA is particularly useful.

Coagulopathy

Due to a decreased risk of hemorrhagic complications, TRA is a great choice for patients with coagulopathy. For instance, a retrospective review by Titano et al examined 2,271 patients who underwent TRA with an international normalized ratio ≥ 1.5 . TRA was shown to be safe, with minor bleeding complications seen in only 5.7% of cases.⁷

Pelvic Trauma

TFA may be inhibited in pelvic trauma by pelvic binders, making TRA an attractive option. A small retrospective review of 13 patients by Williams et al suggests an improvement in potential door-to-closure time and decreased access point complications with TRA during pelvic trauma.⁸

Obesity and Hostile Groins

In patients with obesity, the common femoral artery may be difficult to locate, and postprocedural control of the arteriotomy can be challenging. The TROP registry demonstrated significantly reduced vascular complications with TRA in overweight and obese patients.⁹ Additionally, TRA should be considered for patients in whom atherosclerotic calcifications may preclude TFA cannulation of the femoral arteries. In comparison to the femoral arteries, the radial arteries tend to be less affected by calcific plaque burden. TRA can also be considered in cases of intimal injury and subsequent scarring from previous TFA.

Patient Comfort and Preference

Yamada et al conducted a randomized prospective trial comparing patient preference after TRA and TFA for intra-arterial therapy to treat liver cancer, demonstrating that 81% of patients preferred TRA.¹⁰ The patients in the study cited less pain, discomfort, and need for bed rest, as well as the ability to ambulate earlier as reasons for their preference.

TECHNICAL TIPS FOR SUCCESSFUL RADIAL ACCESS

Strict Patient Eligibility Criteria

Most interventional radiologists perform a Barbeau test (a modified Allen test with a pulse oximeter) to assess radioulnar collateral circulation to determine eligibility for TRA. However, recent data demonstrate no significant difference in ischemia incidence and overall outcomes between patients with normal and abnormal Barbeau test results.³ Relative contraindications for TRA include radial artery diameter < 2 mm, patients with a dialysis fistula, and those nearing dialysis who may depend on the radial artery for access.²

Room Setup

Left TRA is typically preferred because it minimizes crossing of the great vessels of the aortic arch, thus reducing the risk of stroke.¹¹ Further, left TRA has less intravascular length, which provides additional catheter length for subsequent interventions.

The three most common left arm positions during TRA are the left wrist tucked against the left side of the torso, the left arm positioned in abduction (75°–90°), and the left arm crossed over the body with the wrist close to the right groin.¹² Operator radiation exposure is reduced by nearly threefold when using the left arm in an abducted position with a shield placed between the operator and the radiation source.¹⁰

However, this position could interfere with the use of cone-beam CT (CBCT).¹³ Consequently, the left arm may need to be repositioned and/or hyperabducted prior to CBCT acquisition. The use of a swivel arm board facilitates arm repositioning and reduces the risk of catheter or wire dislodgement.¹³

Achieving Access

Approximately 30 minutes prior to TRA, topical nitroglycerin and lidocaine can be used to dilate the artery and improve patient comfort.¹⁴ TRA should be achieved using sonographic guidance with a single-wall puncture technique.² Hydrophilic radial sheaths are recommended, as they can reduce the incidence of radial artery spasm and pain.² Most interventional procedures can be performed

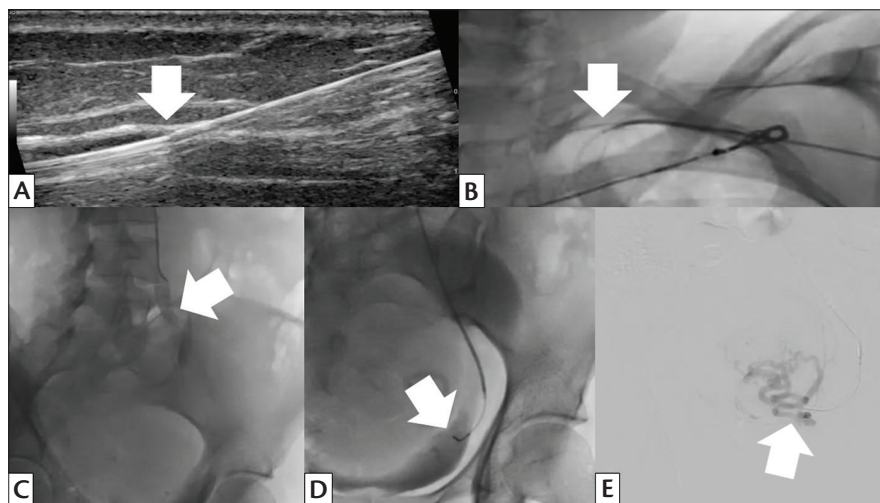


Figure 1. UFE using a radial approach. Ultrasound image during sonographically guided radial artery access showing the wire within the vessel (white arrow) (A). Fluoroscopic image showing a 5-F diagnostic catheter and a 0.035-inch wire crossing the aortic arch from left radial artery access (white arrow) (B). Fluoroscopic image of the pelvis showing the diagnostic catheter injecting contrast into the left common iliac artery (white arrow) (C). Fluoroscopic image of the pelvis showing the microcatheter tip in the horizontal portion of the uterine artery (white arrow) (D). Digital subtraction angiography of the left uterine artery confirming catheter positioning prior to embolization (white arrow) (E).

with 5- or 6-F sheaths, which are considered safe for TRA. After arterial access is achieved, a combination of medications (“radial cocktail”) is administered through the sheath to reduce arterial spasm and vascular tone. At our institutions, a combination of 3,000 units of heparin, 200 µg of nitroglycerin, and 2.5 mg of verapamil are diluted with approximately 10 mL of the patient’s blood and then slowly instilled over 1 minute back into the sheath. The patient’s blood helps buffer the solution and increase patient comfort. We recommend readministration if the procedure lasts longer than 1 hour.

Visceral, Pelvic, and Peripheral Interventions

A variety of catheters and wires can be used for visceral, pelvic, and lower extremity interventions.² For performing visceral interventions and embolizations, the 5-F X 110-cm Optitorque Sarah catheter (Terumo Interventional Systems) or the 5-F X 125-cm Ultimate 2 Performa catheter (Merit Medical Systems, Inc.) in conjunction with a 0.035-inch, 180-cm Glidewire (Terumo Interventional Systems) with a 1.5-mm J tip are typically used.¹⁵ These catheters are available in 110 and 125 cm, come in various shapes including cobra and renal, and are great choices for selecting the celiac axis and/or superior mesenteric artery.¹⁵ These combined with 150-cm-long microcatheters (2-, 2.4-, 2.8-F Progreat [Terumo Interventional Systems] or 2-, 2.4-, 2.9-F Pursue [Merit Medical Systems, Inc.] in various shapes) are usually necessary to achieve technical success.²

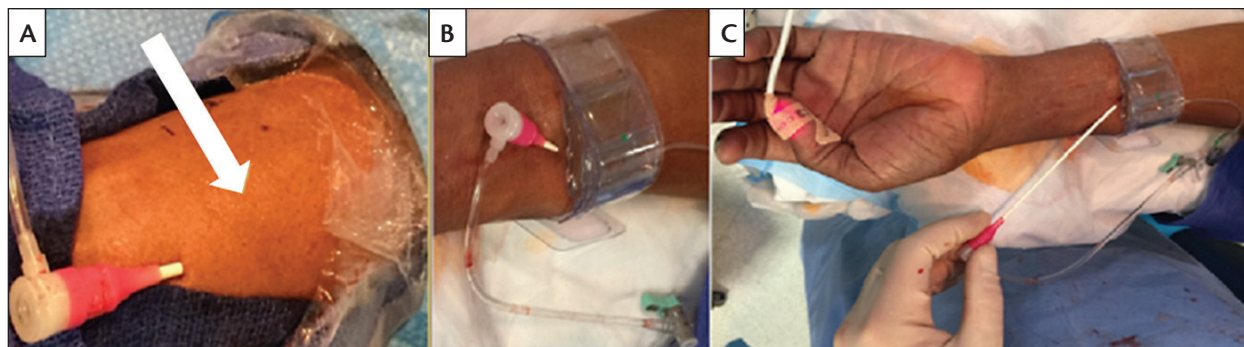


Figure 2. Use of the TR Band to achieve patent hemostasis. The radial sheath is in place (A). The white arrow delineates the access point into the artery. The green dot of the TR band is placed at the site of arterial puncture (B). The band is inflated to approximately 18 mL and then deflated until a small amount of bleeding is seen. At this point, approximately 2 mL of air is reinserted into the band. The sheath is then removed (C). At our institutions, the band is left inflated for approximately 45 minutes, after which time it is deflated about 3 mL every 5 minutes.

For pelvic interventions, such as UFE, TRA in combination with proper postprocedural pain protocols can be used to reduce rates of hospital admission. Conventional TFA requires extended bed rest and leg immobilization, which can lead to patient discomfort and pain exacerbation. Additionally, arterial hemostasis may be compromised during this time due to postprocedural retching or emesis. Basile et al found that TRA improved patient comfort and pain scores after UFE, and > 90% of patients who underwent TRA considered the ability to bend their legs to have an impact on pain relief.¹⁶ For pelvic interventions, 125-cm-long catheters along with 150-cm microcatheters are needed. Patient height can be a limitation to performing TRA for pelvic interventions, particularly prostate artery embolization.

TRA for interventions to treat peripheral artery disease has recently received attention due to the availability of longer devices. The 6-F, 119- and 149-cm R2P Destination Slender guiding sheaths (Terumo Interventional Systems), 150-cm catheters (eg, R2P Slenguide, Terumo Interventional Systems) and balloons, and the R2P Misago RX self-expanding peripheral stent (Terumo Interventional Systems) and Diamondback 360 atherectomy device (Cardiovascular Systems, Inc.), which are available in 200-cm platforms, enable interventions up to the mid to distal superficial femoral artery.¹⁷ Operators should be aware that bailout options in the form of covered stents are currently limited.

Achieving Hemostasis

Nonocclusive, or patent, hemostasis is superior to occlusive hemostasis in TRA.^{2,18} Commercially available wrist bands (TR Band [Terumo Interventional Systems] and RadStat [Merit Medical Systems, Inc.]) can be used to achieve patent hemostasis (Figure 2). After a short

period, the wrist band is slowly deflated according to the instructions for use, and the site is evaluated for bleeding. If bleeding occurs, the band is reinflated for approximately 20 minutes and the process is repeated. After the wristband is removed, patients should be observed for approximately 30 minutes.²

Know Your Complications and How to Manage Them

TRA has an estimated complication rate of approximately 2.5%, including hematoma, radial artery occlusion (RAO), spasm, pseudoaneurysm, perforation, and digital ischemia.⁵ Hematoma, which is usually minor, is the most common complication and is usually self-limited and managed conservatively with arm elevation and compression.¹⁹

RAO. This occurs in approximately 1% of cases,²⁰ is typically asymptomatic, and resolves in approximately 50% of cases at 30 days.¹⁹ As previously noted, the use of anticoagulation during access, proper sheath sizes, and patent hemostasis decrease the incidence of RAO. In symptomatic cases, patients may present with pain or evidence of ischemia in cases where there is inadequate collateral flow.¹⁹ Management strategies include conservative management, anticoagulation, and forced ulnar compression.¹⁸

Radial artery spasm. This can result in procedural failure and occurs in $\leq 20\%$ of cases.¹⁹ It is usually recognized by difficulty in accessing or passing the vessel and/or manipulating and withdrawing equipment. The incidence of radial artery spasm is decreased with the use of a radial cocktail, as previously described. Management strategies include additional or alternative antispasmodic medications, catheter downsizing, and increased sedation. If the spasm persists, alternative access should be considered.¹⁹

Radial artery pseudoaneurysm. This usually manifests as a pulsatile mass that can be confirmed with ultrasound. Initial management strategies include compression therapy, either manually or with a compressive device. If compression therapy fails, thrombin injection or vascular surgery consultation can be considered.¹⁹

Radial perforation. Perforation of the radial artery can be inadvertently caused by guidewire trauma, and careful attention should be paid when resistance to guidewire passage is encountered. In such cases, selective angiography may be beneficial to help delineate the vessel anatomy.¹⁹ Perforation is typically diagnosed with contrast extravasation on angiography. If wire access is maintained, the perforation site should be covered with a long sheath to tamponade the perforation and maintain access beyond the perforation site.¹⁹ If this fails, use of a covered stent can be considered, although only a few cases using this technique have been reported in the literature.²¹

Digital ischemia. This initially presents with rest pain and signs of hypoperfusion (lactic acidosis, cyanosis, loss of radial pulse, cool temperature) and can occur months after a procedure was performed.²² Management of digital ischemia is largely surgical, with urgent vascular surgery consultation recommended. Delay in treatment can result in permanent ischemic injury and/or amputation.²²

Stroke. Although there is a theoretical risk of stroke, this is extremely rare. In the cardiology literature, no difference was shown in the incidence of stroke with TRA versus TFA.²³

CONCLUSION

TRA is a safe and effective approach for peripheral vascular interventions. Compared with TFA, it carries fewer access site complications, decreases length of stay, and improves patient satisfaction. This is especially relevant in interventional oncology procedures, obese patients, trauma cases, and peripheral embolizations. For radial artery access to be successful, the interventional radiologist should be familiar with the technical steps as well as the associated complications. If used strategically, TRA can be a valuable tool in the interventional radiologist's armamentarium. ■

- Mitchell MD, Hong JA, Lee BY, et al. Systematic review and cost-benefit analysis of radial artery access for coronary angiography and intervention. *Circ Cardiovasc Qual Outcomes*. 2012;5:454-462.
- Titano JJ, Biederman DM, Zech J, et al. Safety and outcomes of transradial access in patients with international normalized ratio 1.5 or above. *J Vasc Interv Radiol*. 2018;29:383-388.
- Williams R, Murphy T, Kerwin G, et al. Initial experience with trans radial artery access for management of high-grade splenic trauma at a major metropolitan trauma center. *J Vasc Interv Radiol*. 2017;28(suppl):S131.
- Benamer H, Louvard Y, Sanmartin M, et al. A multicentre comparison of transradial and transfemoral approaches for coronary angiography and PTCA in obese patients: the TROP registry. *EuroIntervention*. 2007;3:327-332.
- Yamada R, Bracewell S, Bassaco B, et al. Transradial versus transfemoral arterial access in liver cancer embolization: randomized trial to assess patient satisfaction. *J Vasc Interv Radiol*. 2018;29:38-43.
- Rashid M, Lawson C, Potts J, et al. Incidence, determinants, and outcomes of left and right radial access use in patients undergoing percutaneous coronary intervention in the United Kingdom: a national perspective using the BCIS dataset. *JACC Cardiovasc Interv*. 2018;11:1021-1033.
- Ricardo Y, Guimaraes M. Optimal room setup for transradial access. *Endovasc Today*. 2018;11:41-42, 47.
- Pua U, Teo CC, U PT, Quek LHH. Cone-beam CT acquisition during transradial TACE made easy; use of the swivel arm board. *Br J Radiol*. 2018;91:20170248.
- Beyer AT, Ng R, Singh A, et al. Topical nitroglycerin and lidocaine to dilate the radial artery prior to transradial cardiac catheterization: a randomized, placebo-controlled, double-blind clinical trial. *Int J Cardiol*. 2013;168:2575-2578.
- Kis B, Mills M, Hoffe SE. Hepatic radioembolization from transradial access: initial experience and comparison to transfemoral access. *Diagn Interv Radiol*. 2016;22:444-449.
- Basile A, Rebonato A, Failla G, et al. Early post-procedural patients compliance and VAS after UAE through transradial versus transfemoral approach: preliminary results. *Radiol Med*. 2018;123:885-889.
- Posham R, Young LB, Lookstein RA, et al. Radial access for lower extremity peripheral arterial interventions: do we have the tools? *Semin Intervent Radiol*. 2018;35:427-434.
- Pancholy S, Coppola J, Patel T, Roke-Thomas M. Prevention of radial artery occlusion-patient hemostasis evaluation trial (PROPHET study): a randomized comparison of traditional versus patency documented hemostasis after transradial catheterization. *Catheter Cardiovasc Interv*. 2008;72:335-340.
- Steinberg DH. Managing complications of transradial catheterization. *Cardiac Interv Today*. 2015;9:58-62.
- Aboud J, Gargali S, Kalayeh N, et al. A single center experience with radial artery occlusion and spasm after a minor change in the protocol for administration of the radial artery cocktail. *Catheter Cardiovasc Interv*. 2013;81:S171.
- Sallam MM, Ali M, Al-Sekaiti R. Management of radial artery perforation complicating coronary intervention: a stepwise approach. *J Interv Cardiol*. 2011;24:401-406.
- de Bucourt M, Teichgraber U. Digital ischemia and consecutive amputation after emergency transradial cardiac catheter examination. *Cardiovasc Intervent Radiol*. 2012;35:1242-1244.
- Ratib K, Mamas MA, Routledge HC, et al. Influence of access site choice on incidence of neurologic complications after percutaneous coronary intervention. *Am Heart J*. 2013;165:317-324.

Kamil Arif, MD

Department of Radiology
University of Alabama at Birmingham
Birmingham, Alabama
kamilarif@uabmc.edu

Disclosures: None.

Andrew J. Gunn, MD

Assistant Program Director
Diagnostic Radiology Residency Program
Assistant Professor
Interventional Radiology Section
University of Alabama at Birmingham
Birmingham, Alabama

Disclosures: Speaker for Terumo Interventional and AngioDynamics; speaker for and consultant to BTG; research support from Penumbra.

Keith J. Pereira, MD

Assistant Professor
Department of Radiology
Division of Interventional Radiology
Saint Louis University School of Medicine
St. Louis, Missouri

Disclosures: None.

- Campeau L. Percutaneous radial artery approach for coronary angiography. *Cathet Cardiovasc Diagn*. 1989;16:3-7.
- Fischman AM, Swinburne NC, Patel RS. A technical guide describing the use of transradial access technique for endovascular interventions. *Tech Vasc Interv Radiol*. 2015;18:58-65.
- Mason PJ, Shah B, Tamis-Holland JE, et al. An update on radial artery access and best practices for transradial coronary angiography and intervention in acute coronary syndrome: a scientific statement from the American Heart Association. *Circ Cardiovasc Interv*. 2018;11:e000035.
- Singh S, Singh M, Grewal N, Khosla S. Transradial vs transfemoral percutaneous coronary intervention in ST-segment elevation myocardial infarction: a systemic review and meta-analysis. *Can J Cardiol*. 2016;32:777-790.
- Posham R, Biederman DM, Patel RS, et al. Transradial approach for noncoronary interventions: a single-center review of safety and feasibility in the first 1,500 cases. *J Vasc Interv Radiol*. 2016;27:159-166.