

Novel Mechanical Thrombectomy Tools for Venous Thromboembolism

Dr. Antonious Attallah and Dr. Herman Kado report on recent FlowTrievers and ClotTrievers PE and DVT cases, and extracted clot images are presented from recent procedures performed across the United States.

WITH ANTONIOUS ATTALLAH, MD, FACC, FSCAI, AND HERMAN KADO, MD, FACC, FSCAI, RPVI

Immediate Symptom Relief in Patient With Acute PE Treated With FlowTrievers



Antonious Attallah, MD, FACC, FSCAI

Interventional Cardiologist
Ascension St. John Hospital
Detroit, Michigan
tonycardiology@gmail.com
Disclosures: None.

A 43-year-old African American woman presented to the emergency room (ER) with severe shortness of breath, dyspnea, and hypoxia following a long drive to Michigan from Florida. Upon her return, she first noticed that her lower extremities were swollen, the right more severely than the left. She then progressively became short of breath, which culminated on the day of her ER admission. Upon evaluation in the ER, she had a marginal systolic blood pressure of 95 mm Hg and was hypoxic at 85% on room air, breathing 25 breaths per minute. A chest CT scan was ordered and revealed a large bilateral pulmonary embolism (PE) with a right ventricular (RV)/left ventricular (LV) ratio of 1.48 (Figure 1). Additionally, given her history of menorrhagia due to chronic fibroid tumors, she was severely anemic with a hemoglobin level of 5.5 g/dL.

After discussing treatment options with the patient, the ER staff, and her primary care physician, we decided

to proceed with mechanical thrombectomy using the FlowTrievers System (Inari Medical) to treat her PE.

PROCEDURAL OVERVIEW

The patient was taken to the cath lab for right heart catheterization, which revealed significant cardiac compromise with a severely decreased cardiac index of 1.5 L/min/m². Pulmonary angiography was performed and showed significant bilateral clot burden that was

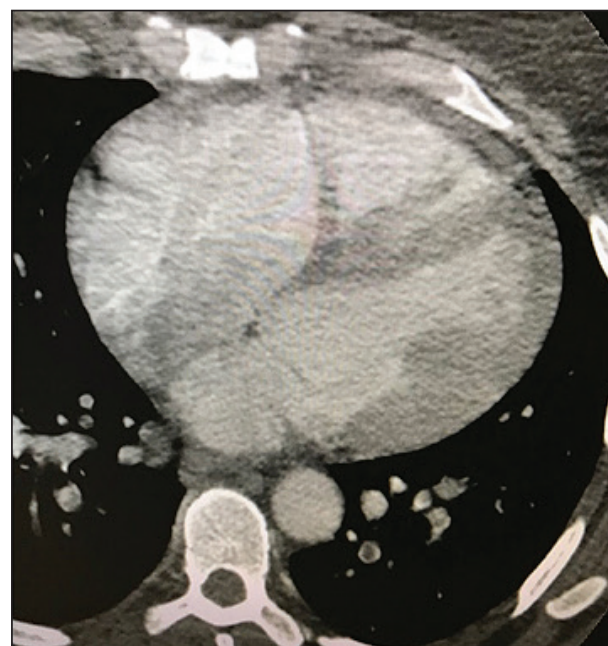

Figure 1. CT scan revealing an RV/LV ratio of 1.48.

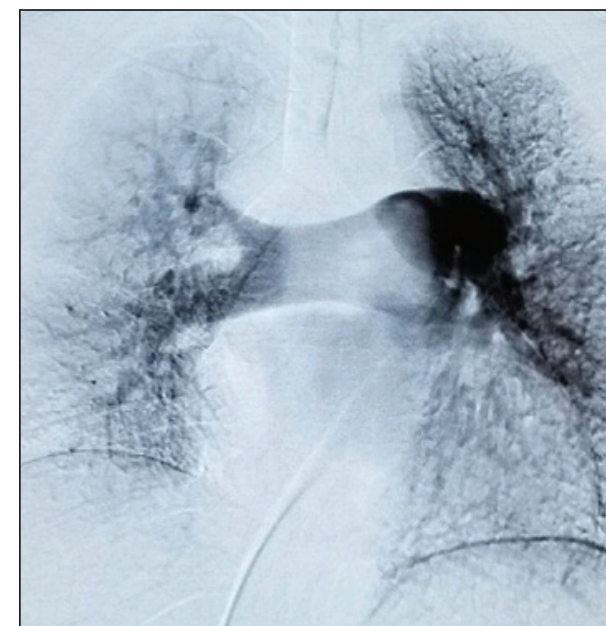

Figure 2. Clot burden on the PA angiogram.

worse on the right side with barely any perfusion beyond the right main pulmonary artery (PA) with mostly first order filling (Figure 2).

We then proceeded with FlowTrievers mechanical thrombectomy. The femoral access site was dilated to accommodate a 22-F DrySeal sheath (Gore & Associates). FlowTrievers was inserted over a 0.035-inch Amplatz Super Stiff guidewire (Boston Scientific Corporation) and advanced through the right PA to the target clot in the descending interlobar artery for clot extraction. Significant clot burden was retrieved (Figure 3), and the patient noted immediate symptom relief. Next, the FlowTrievers was repositioned to the truncus anterior in the right upper lobe. Immediately upon clot extraction, the patient again remarked on how much better she felt.

RESULTS

Repeat angiography was performed and showed marked improvement in flow to the entire right lung with removal of the main obstructing clot within the right main PA (Figure 4).

Venous ultrasound of the lower extremity did not reveal any evidence of iliofemoral deep vein thrombosis (DVT), so the patient was transitioned to direct oral anticoagulation and discharged 72 hours after her initial presentation in stable condition.

DISCUSSION

Although this case was early in our experience, we were able to successfully treat this high-risk patient simply and

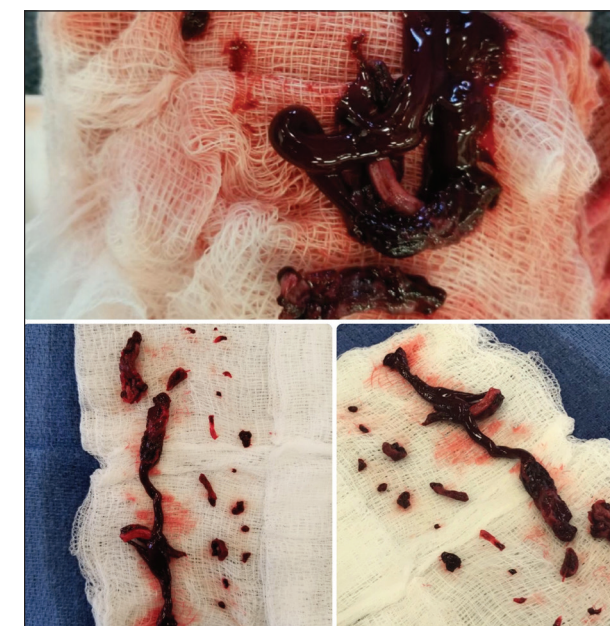


Figure 3. Significant clot volume extracted from the right PA branches.

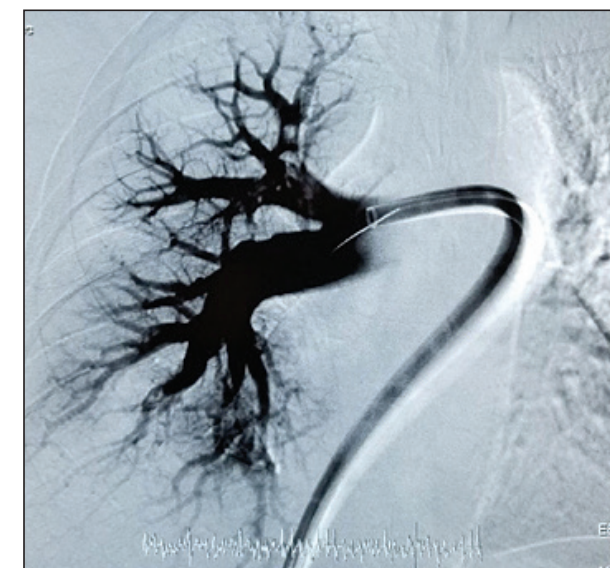

Figure 4. Pulmonary angiogram after FlowTrievers mechanical thrombectomy.

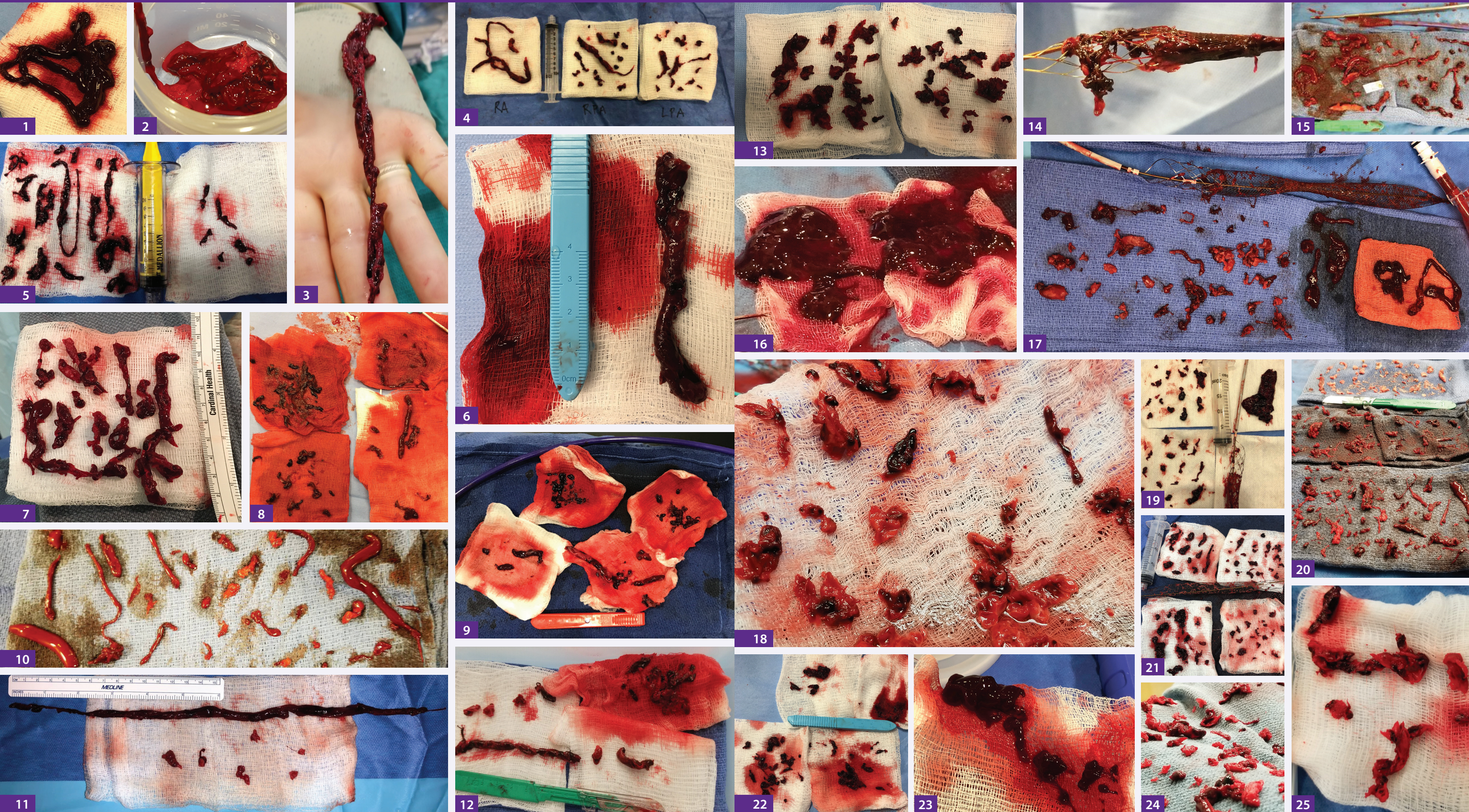
quickly. We removed a significant amount of thrombus and rapidly restored blood flow, resulting in an immediate improvement in symptoms in under 90 minutes for a patient who was not able to undergo thrombolytic therapy due to severe anemia. Since its launch, the FlowTrievers System has become an important tool in the treatment of hemodynamically significant submassive and massive PE, helping reduce the risks, time, and cost associated with PE treatment at our institution.

FlowTrieve

Clot extracted from the pulmonary arteries

ClotTrieve

Clot extracted from the lower extremity deep veins



1. Dr. Kevin Bradley, Sacred Heart Hospital, Pensacola, FL; 2. Dr. Daniel E. Long, The Christ Hospital, Cincinnati, OH; 3. Dr. Wissam Jaber, Emory University Hospital, Atlanta, GA; 4. Dr. Jay Mathews, Manatee Memorial Hospital, Bradenton, FL; 5, 11. Dr. Glen Hoots, Tampa General Hospital, Tampa, FL; 6, 13. Dr. Nathan Saucier, St. Luke's Hospital, Kansas City, MS; 7, 24. Dr. Michael Rosenberg, University of Minnesota, Minneapolis, MN; 8, 22. Dr. Kenneth Cho, St. Luke's Hospital, Kansas City, MS; 9, 12. Dr. Thomas M. Tu, Baptist Health Louisville, Louisville, KY; 10. Dr. Kevin Ryan, East Alabama Medical Center, Opelika, AL.

14. Dr. Richard Ofstein, Community Heart & Vascular, Indianapolis, IN; 15. Dr. Dev Mangal, Northeast Georgia Medical Center, Gainesville, GA; 16. Dr. Tod Engelhardt, East Jefferson General Hospital, Metairie, LA; 17. Dr. Muthusamy Velusamy, Florida Hospital Carolwood, FL; 18. Dr. John Lee, Mercy Hospital, Coon Rapids, MN; 19. Dr. Bob Beasley, Dr. Brandon Olivieri, Dr. Tim Yates, Mount Sinai Hospital, Miami, FL; 20. Dr. Sumona Smith, Northeast Georgia Medical Center, Gainesville, GA; 21. Dr. Suman Annambhotla, Northeast Georgia Medical Center, Gainesville, GA; 23. Dr. Fakhir Elmasri, Lakeland Vascular Institute, Lakeland, FL; 25. Dr. Robert Crawford, Emory Saint Joseph's Hospital, Sandy Springs, GA.

Efficient Removal of Large Thrombus Volume in Patient With DVT Treated With ClotTrieve



Herman Kado, MD, FACC, FSCAI, RPVI

Director of Cardiology
St. John Oakland Hospital
Madison Heights, Michigan
hkado@hotmail.com
Disclosures: None.

A 61-year-old man with an unremarkable medical history presented to the emergency room (ER) with acute respiratory failure due to massive pulmonary embolism (PE). Systemic tissue plasminogen activator (tPA) was administered with the patient showing significant improvement in symptoms. A posttreatment echocardiogram showed normal right ventricular size, function, and pressure. Venous duplex ultrasound, however, showed significant right leg deep vein thrombosis (DVT) remaining after the tPA administration. The patient was discharged on a novel oral anticoagulant with a follow-up office visit scheduled 1 week later.

PROCEDURAL OVERVIEW

During follow-up, the patient's right leg was still very edematous with significant discomfort. Examination revealed pitting edema and CEAP (clinical, etiology, anatomy, pathophysiology) C3 disease. The patient was scheduled for further imaging with venography and intravascular ultrasound (IVUS). In a supine position, a micropuncture sheath was inserted into the popliteal vein using ultrasound guidance. Venography revealed a large residual thrombus with probable compression of the common iliac vein (Figure 1). The occlusion was crossed with a 0.035-inch Glidewire Advantage device (Terumo Interventional Systems) and a Navicross support catheter (Terumo Interventional Systems).

A 13-F ClotTrieve funnel sheath (Inari Medical) was inserted into the popliteal vein (Figure 2). A ClotTrieve catheter (Figure 3) was advanced through the thrombus and into the inferior vena cava to begin pullback. Two pullbacks were performed, extracting significant clot both times. Venoplasty of the residual thrombus was performed to promote maceration, followed by an additional pass of the ClotTrieve catheter, allow-

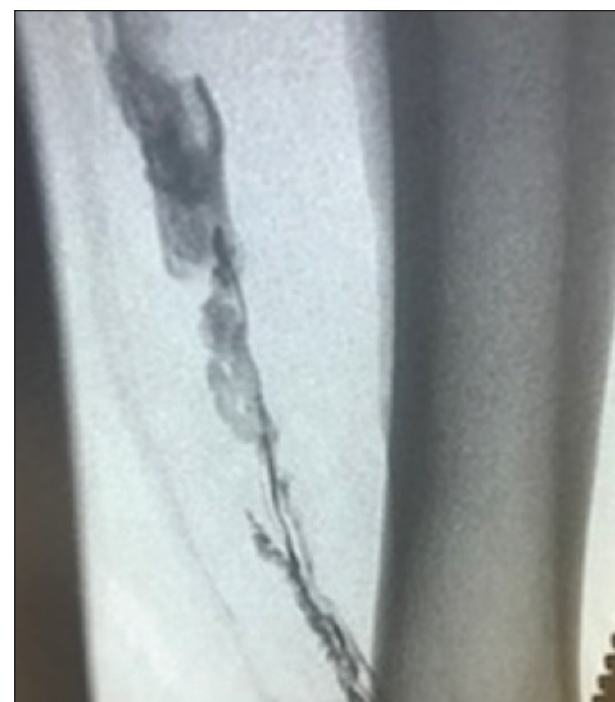

Figure 1. Preprocedural venogram.




Figure 2. ClotTrieve sheath.




Figure 3. ClotTrieve catheter.

ing the remaining thrombus to be extracted (Figures 4 and 5). Repeat venography showed excellent results after a total thrombectomy time of 30 minutes.

Next, an IVUS pullback was performed to confirm severe iliac vein compression. An 18- X 90-mm Wallstent device (Boston Scientific Corporation) was implanted and postdilated with a 16- X 40-mm Atlas balloon (BD Interventional).

RESULTS

Final venography and IVUS confirmed excellent results, normal venous flow, and no residual thrombus (Figure 6). The total procedure time including venography, IVUS, ClotTrieve thrombectomy, and stenting was 65 minutes, without the need for adjunctive tPA or intensive care unit monitoring. The patient was discharged a few hours after the procedure.

DISCUSSION

The ClotTrieve System is an exciting new treatment option to extract significant clot burden without the bleeding risks or costs associated with

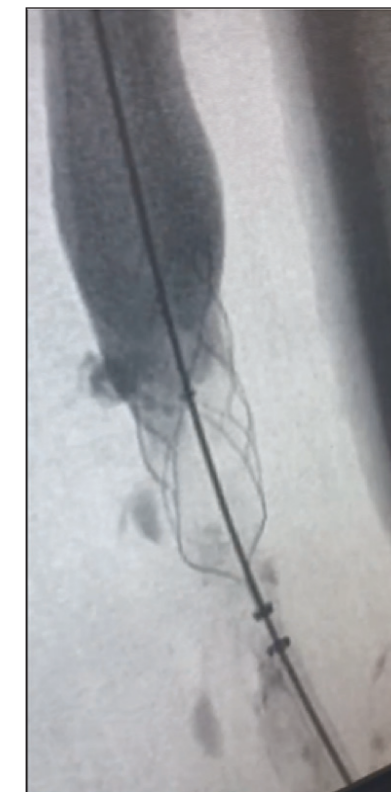

Figure 4. Venogram showing the ClotTrieve catheter capturing clot.

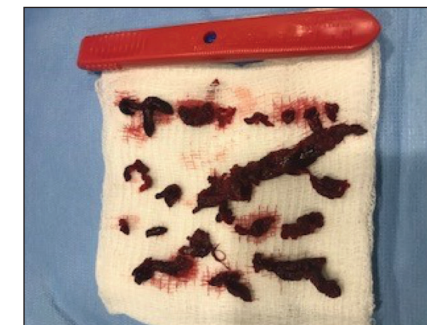

Figure 5. Extracted clot.

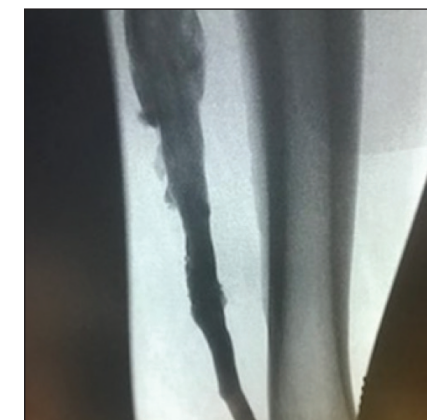

Figure 6. Venogram after ClotTrieve thrombectomy.

thrombolytic drugs and hospital admission. The convenience and savings associated with the ability to perform thrombectomy and stenting in a single session are compelling. ■