

Repair of Aortic Coarctation

New and emerging techniques in coarctation of the thoracic aorta.

BY ANDREW W. SHAFFER, MD; ROCHUS VOELLER, MD; AND AMY B. REED, MD, FACS

Aortic coarctation is typically diagnosed in infancy and childhood, accounting for approximately 7% of congenital heart defects. It most commonly describes the congenital narrowed part of the thoracic aortic isthmus around the insertion of the arterial duct. In the majority of cases, it is associated with one or more cardiac anomalies, including hypoplastic aortic arch, ventricular septal defect, patent ductus arteriosus, and bicuspid aortic valve.¹

There is extensive literature describing pediatric aortic coarctation repair, which was first noted in 1945. Techniques including balloon dilation and endovascular management continue to evolve for the management of both primary and recurrent coarctation. Given the excellent outcomes, open surgical repair remains the gold standard, particularly for infants and younger children. Late complications, including aneurysm formation, pseudoaneurysm, dissection, and recurrent (secondary) coarctation, occur in 11% to 24% of patients.² Delay in diagnosis may occur if the coarctation is subclinical and can play a role in the type of repair undertaken. Bare-metal stents have largely replaced open repair for older children and adults,³ although the late complications are similar. Thoracic endovascular aortic repair (TEVAR) has evolved as a potential solution for late complications and primary repair in older children and adults. Although the principles of repair are similar between children and adults, a few key differences exist. As technique evolves to a less invasive approach, it is important to note the types of open surgical procedures that are performed for aortic coarctation.

OPEN SURGICAL REPAIR

Preparing the Operating Room

Standard preparation for open heart surgery should be performed preoperatively. Patients should have the diagnosis of aortic coarctation confirmed with

echocardiography, MRI, or CT scan. Additionally, patients should undergo a fitness assessment prior to the operation. Standard assessment includes electrocardiography, chest x-ray, cardiac catheterization, carotid arterial duplex ultrasound, and echocardiography to assess the cardiac valves. Pulmonary function testing is important as well. Patients undergoing open repair of coarctation will face recovery from a thoracotomy and lung injury. Otolaryngology evaluation is important, especially in redo surgical candidates, to document vocal cord status prior to proceeding to the operating room. Patients with vocal cord dysfunction will require special attention for airway management perioperatively.

Vascular Control and Systemic Perfusion Techniques

Choice of vascular control, anastomotic technique, and perfusion support technique depends on multiple factors. The anticipated time to complete anastomosis, proximal and distal extent of coarct, and patient tolerance of lower body ischemia are all factors to consider when selecting where to clamp and how to support systemic circulation.

The aorta is exposed by isolating the left lung and retracting the lung anterior and inferior. The parietal pleura is incised. It is important to mobilize the distal aortic arch, proximal left carotid artery, proximal left subclavian artery, and proximal descending aorta and avoid injury to the spinal arteries. The patient is given systemic intravenous heparin with a target activated clotting time of > 300 seconds.

The Clamp-and-Sew Technique

The most straightforward approach to aortic coarctation repair is the clamp-and-sew technique. This technique is primarily used in infants and children. Younger patients are better able to tolerate several

minutes of lower body ischemia compared with adults. In appropriately selected adult patients, this is a viable option for surgery. It is important to have a convenient site to place a proximal and distal clamp on the aorta. Having sufficient room between the left carotid artery and the proximal extent of the abnormal aortic tissue is key. Adult patients can tolerate clamping (or even ligation) of the left subclavian artery.

When using the clamp-and-sew technique, a straight or angled DeBakey clamp is placed across the distal aortic arch. The clamp can be placed just distal to the takeoff of the left carotid artery, and the distal clamp should be positioned on the proximal descending aorta distal to the area of abnormal aortic tissue.

Resection With End-to-End Anastomosis

For limited-segment coarcts with an adequate length of healthy proximal and distal aorta, end-to-end anastomosis should be performed. This technique is straightforward, reproducible, and relatively quick to execute. Completion of the end-to-end anastomosis is performed in a standard fashion. It is important to perform adequate mobilization of the aorta proximally and distally before clamping. Special attention needs to be made for the left recurrent laryngeal nerve at the proximal extent of the dissection. Appropriate vascular control and perfusion technique should be selected depending on the anticipated time to restoration of blood flow. We commonly buttress the anastomosis with bovine pericardial strips (Figure 1). The anastomosis should be deaired by

releasing the distal clamp first and proximal clamp after the stitch is tied. Distal perfusion is assessed by checking Doppler signals in the groins or feet before completing the case.

Subclavian Flap Aortoplasty

Although subclavian flap aortoplasty is rarely performed in current practice, it is important to be familiar with this technique, as patients with a history of this repair as a neonate or infant are still alive today. This technique was used historically when it was thought that there was inadequate length of aorta available to create a tension-free anastomosis. These patients may present with recurrent coarctation.

The aorta and branches are adequately mobilized, and the left subclavian artery is then ligated near the takeoff of the vertebral artery. The aorta is cross-clamped proximally and distally. Next, the aorta is incised in a longitudinal fashion from distal to the coarctation extending proximally out onto the proximal segment of the subclavian artery. The subclavian “flap” is then used to create an extended end-to-end anastomosis. Buttressing materials are not routinely utilized in neonates and infants.

Bypass/Interposition Graft Repair

Aortic coarctation with a long segment of affected tissue will have tension on the anastomosis when completed. If aortic mobility is not adequate to achieve end-to-end anastomosis, reconstruction with an inter-

position graft is an excellent option in adults. This technique is less advantageous in children, as the graft will not grow with the child. For cases with significant proximal extension or those necessitating hypothermic circulatory arrest, this is an excellent option.

The technique for reconstruction is similar to what has been previously outlined. Vascular control and perfusion support are selected on a case-by-case basis. Reconstruction with an interposition graft is easily performed with bypass assistance. We routinely

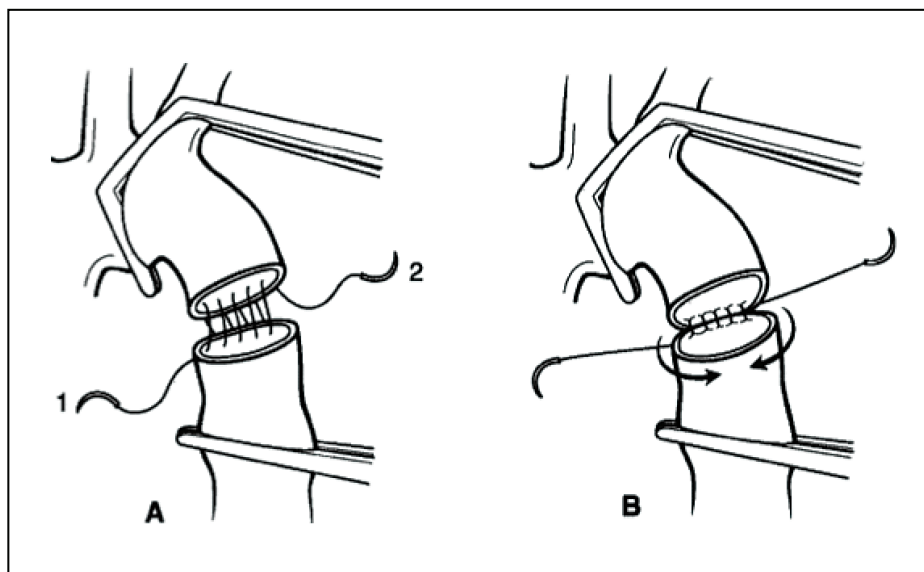


Figure 1. End-to-end reconstruction of aortic coarctation. Reprinted from *Oper Tech Thorac Cardiovasc Surg*, 7/1, Jaquiss R. Coarctation of the aorta: end-to-end anastomosis, 2-10, Copyright 2002, with permission from Elsevier.

complete the proximal anastomosis first. Buttressing the anastomosis with bovine pericardium facilitates good hemostasis. Performing the proximal anastomosis first allows removal of the proximal clamp (a clamp must be placed on the graft distal to the anastomosis) and improved perfusion of the upper body vasculature. The aorta is deaired by removing the distal clamp first, followed by the proximal clamp. Distal perfusion is assessed by Doppler ultrasound.

Patch Aortoplasty

Patch aortoplasty is an alternative option for patients with limited mobility of aortic tissue. Vascular control and systemic perfusion are performed in similar fashion. The aorta is incised longitudinally across the segment of coarctation and then augmented with a synthetic patch. Options for patch material include autologous pericardium, bovine pericardium, aortic homograft, or synthetic material (eg, Dacron or Gelweave patch [Terumo Aortic]). Autologous tissue or homograft are excellent options in an infected field.

Aortic Arch Advancement

This technique is typically reserved for young infants with mobile, elastic tissues, and the surgeon may encounter adult patients with previous reconstruction in this fashion. A high degree of mobility is necessary to complete this anastomosis without undue tension. This reconstruction is best performed by median sternotomy or bilateral thoracotomies.

Vascular control and systemic perfusion are complex with this form of reconstruction, and often, a brief period of circulatory arrest is necessary to complete the anastomosis. When performed in neonates, a patent ductus arteriosus is often present. Blood flow from a patent ductus arteriosus on full bypass can be torrential and can make completion of the anastomosis impossible without low flows or circulatory arrest.

The aortic arch and proximal descending aorta are completely mobilized. The anastomosis is completed by transecting the aorta distal to the left subclavian. The underside of the arch is incised longitudinally proximally to the level of the innominate takeoff. The distal aorta can be incised on the cranial left-sided aspect to make the size match.

Sliding Arch Aortoplasty

This technique is used in older children or young adults and is best approached via a median sternotomy. A considerable degree of tissue mobility needs to be achieved to create a tension-free anastomosis.

If there is any doubt of undue tension, we recommend creating an interposition graft anastomosis. This technique is best performed with bypass assistance, including possible circulatory arrest, so preparations should be made for this part of the procedure.

The anastomosis is created by transecting the ascending aorta. The underside of the aortic arch is incised longitudinally and distally. An end-to-side anastomosis is created between the ascending aorta and transverse aortic arch. If there is inadequate augmentation, the anastomosis can be further augmented with a patch. We prefer to use a Dacron patch and incorporate this in the anterior aspect of the anastomosis.

ENDOVASCULAR REPAIR

Older children, adults, and patients who are poor surgical candidates should be considered for percutaneous options. Restenosis rates after angioplasty are 20% to 35%. The addition of stent grafting reduces the risk of restenosis. Other risks of this procedure include aortic dissection or rupture, aneurysm formation, and femoroarterial complications.

Bare-metal stents are balloon mounted and deployed in the area of coarctation, typically with the patient under general anesthesia.³ Femoral access is obtained, and the coarctation is crossed with an angled catheter. A 260-cm curved stiff wire is placed in the ascending aortic arch and pressure gradients are measured across the coarctation. Arch aortography is performed, taking into account angulation as well as location of the origin of the great vessels. The final stent diameter is based on the proximal aortic arch diameter with an eye toward not exceeding the diameter of the distal aortic arch. The bare-metal stent is hand crimped on the balloon, then advanced through the sheath. To keep this stent from slipping, we have found it easiest to track the sheath through the coarctation, slowly retract the sheath when in the proper position, and then inflate the balloon. After stent placement, gradient pressures are checked with a goal of < 10 mm Hg and a vessel diameter at least 80% of the normal adjacent aorta.

TEVAR has been used to treat complications after open coarctation repair. Given that a proportion of patients with coarctation first present as adults, a tapered TEVAR may more easily accommodate the proximal-distal aortic mismatch as well as the angulation and conformability that may not be possible with bare-metal stents. Although TEVAR is beneficial for late complications after open coarctation repair, it may not have enough radial force to treat the primary

or recurrent coarctation repair in adults compared to younger patients. This is in part due to decreased vessel compliance and juxtaductal positions requiring increased complexity to secure an appropriate zone 1 or 2 landing zone.

Great vessel debranching procedures can facilitate adequate coverage and a landing zone for a stent graft placement. Debranching procedures can be performed by placing an ascending aorta-to-innominate-left carotid-left subclavian three-arm graft. Alternatively, management of coarctation with ascending aorta-to-innominate artery bypass, followed by carotid-to-carotid and carotid-to-subclavian bypass can facilitate arch stent graft placement and appropriate landing zones. Branched stent grafts and parallel stent grafting with a subclavian chimney-covered stent can also help to facilitate a more favorable landing zone for stent graft repair.

Lala et al described TEVAR for aortic coarctation in 21 adult patients who were 33 to 71 years of age, six of which were primary interventions. Technical success was 100% with no mortality or paraplegia events at 30 days, although two patients had nondisabling perioperative strokes. A reintervention rate of 10% was noted at 12 months—all were due to type II endoleaks, the majority of which arose from the left subclavian artery.⁴

CONCLUSION

Endovascular technology for aortic coarctation continues to evolve since its inception in the 1990s. The best therapeutic approach—stenting versus surgery—in the treatment of primary coarctation continues to be debated due to the paucity of long-term follow-up data. In 2018, early and intermediate follow-up favors endovascular treatment of coarctation in older children and adults, although the long term remains speculative. We find it best to come to a multidisciplinary decision before any type of repair is undertaken. Open surgical treatment or balloon angioplasty continues to be the procedure of choice in management for children. Ongoing follow-up is required to determine which treatment paradigm is best for which particular coarctation anatomy. ■

Andrew W. Shaffer, MD

Division of Cardiothoracic Surgery
Department of Surgery
University of Minnesota
Minneapolis, Minnesota
Disclosures: None.

Rochus Voeller, MD

Division of Vascular Surgery
Department of Surgery
University of Minnesota
Minneapolis, Minnesota
Disclosures: None.

Amy B. Reed, MD, FACS

Director, Fairview Vascular Services
Professor and Chief, Vascular and Endovascular Surgery
University of Minnesota
Minneapolis, Minnesota
reed@umn.edu
Disclosures: None.

1. Becker AE, Becker MJ, Edwards JE. Anomalies associated with coarctation of the aorta: particular reference to infancy. *Circulation*. 1970;41:1067-1075.
2. Cramer JW, Ginde S, Bartz PJ, et al. Aortic aneurysms remain a significant source of morbidity and mortality after use of Dacron patch aortoplasty to repair coarctation of the aorta: results from a single center. *Pediatr Cardiol*. 2013;34:296-301.
3. Forbes TJ, Gowda ST. Intravascular stent therapy for coarctation of the aorta. *Methodist DeBakey Cardiovasc J*. 2014;10:82-87.
4. Lala S, Scali ST, Feezor RJ, et al. Outcomes of thoracic endovascular aortic repair in adult coarctation patients. *J Vasc Surg*. 2018;67:369-381.