

# Current Status of Arch Branch Technology

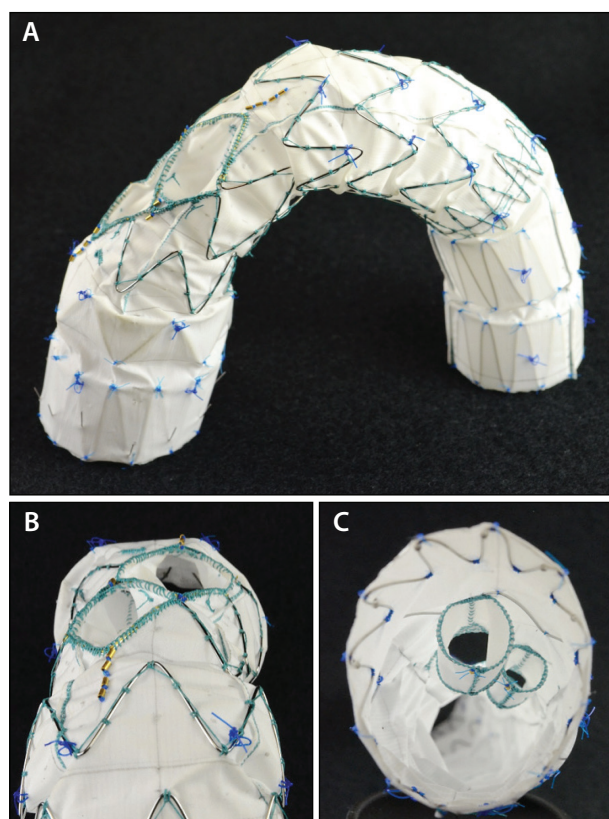
Initial experience with arch branch device technology and considerations for optimizing operator technique and future iterations of these devices.

**BY STÉPHAN HAULON, MD, PhD; JARIN KRATZBERG, PhD; JULIEN GUIHAIRE, MD, PhD; AND DOMINIQUE FABRE, MD, PhD**

Open surgical repair remains the gold standard of care for complete aortic arch replacement; however, alternative, less invasive procedures continue to show promise in treating the aortic arch due to their ability to decrease surgical morbidity and mortality. The ability to repair the aortic arch via endovascular means has clear advantages in that: (1) the surgery is done via a minimally invasive approach with no sternotomy or ministernotomy needed; (2) the procedure is done under general anesthesia without the use of hypothermic circulatory arrest; and (3) cardiopulmonary bypass is not required.

Currently, there are no commercially available endovascular grafts for total arch repair; however, several manufacturers have introduced designs through the custom-made device process in Europe and the early feasibility process within the United States. This article reflects the experience to date with the Cook Medical platform, and others are described in the accompanying *Aortic Arch Technologies in Development* sidebar. Over the past 15 years, Cook has produced several iterations of devices to treat the aortic arch from an endovascular approach. Although early versions proved clinically useful when the devices were appropriately delivered, they were hampered by technical difficulties, and extensive use was hindered due to associated peri- and postoperative complications. Specifically, the use of scallops and fenestrations in early designs proved extremely difficult due to the excessive manipulation needed to align these features with their appropriate branch vessels.<sup>1</sup>

However, research and development efforts were significantly aided by these early learning experiences, and in 2009, Cook designed an inner branch arch endovas-



Courtesy of Cook Medical.

**Figure 1.** The Zenith arch branch graft (A) with views from the abluminal side from above (B) and the luminal side from the proximal end of the graft (C).

cular graft, which was specifically aimed to overcome the recognized challenges of endovascular arch repair while offering high-risk patients a durable treatment option. It is important to note that the inner branch arch graft is investigational and not available commercially.

## AORTIC ARCH TECHNOLOGIES IN DEVELOPMENT

*A look at some of the platforms currently in development and trials.*

### VALIANT MONA LSA STENT GRAFT

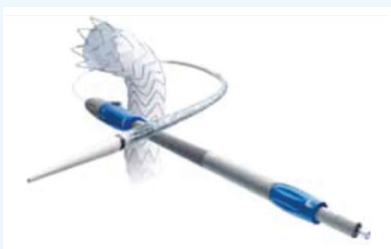The Valiant Mona LSA stent graft (Medtronic) is currently under investigation.

The main body of the graft has the same eight-peak self-expanding FreeFlo proximal design as the Valiant thoracic stent graft. The first two proximal covered stents have been modified to include space to accommodate a flexible cuff, which serves as a conduit between the main stent graft and the LSA branch stent graft. The cuff is radiopaque to aid visualization while positioning at the LSA. It also acts as a guide to ensure adequate overlap of the LSA branch stent graft with the cuff. There is a self-expanding stent at the top of the cuff to ensure fixation and seal of the LSA branch stent graft and the cuff.

The main stent graft delivery system is also modified from the currently available Captivia delivery system. It has a dual-wire lumen with the main wire supporting the main stent graft and a second wire for LSA access. It maintains the tip capture feature of Valiant Captivia for controlled and accurate deployment. The second lumen is cannulated with a hydrophilic wire. The proximal nosecone has been modified to accommodate passage of two wires.

The LSA branch stent graft is composed of a nitinol stent and a polyester graft material with a proximal flare to provide a seal between components. The branch stent graft will come in a range of sizes specifically designed to treat the LSA. It is delivered from a femoral approach through a hydrophilic delivery system.

A prospective, nonrandomized, single-arm, premarket study conducted at three centers (two sites in the United States and one in the United Kingdom). The primary objective was to assess effectiveness, defined as treatment success—successful delivery and deployment of the stent graft in the planned location, exclusion of the descending thoracic artery, and maintained patency of the main and branched stent grafts. All nine patients received one main stent graft (diameter, 28–42 mm) and one branch stent graft (diameter, 10–14 mm). Technical success, defined by the clinical investigational plan, was achieved in all nine patients intraoperatively, and treatment success was achieved in all eight evaluable patients at 1 month. There were no major, disabling strokes.



*Courtesy of Medtronic*

### NEXUS STENT GRAFT SYSTEM

The Nexus stent graft system (Endospan) aims to provide a standardized, approved endovascular procedure that can serve as a less invasive

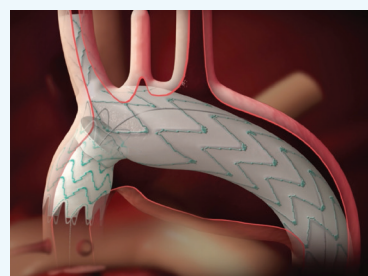
alternative to complex surgical aortic arch repair. Nexus is designed for enhanced intraprocedural and long-term stability attributable to its proprietary geometric design, with goals of reducing arch manipulation and stroke risks while providing an effective repair.

The main module is implanted from the innominate artery to the arch and the descending aorta, all as one integral module. The intention of this design is to provide an anatomic fixation point for long-term stability, as well as to ensure continuous perfusion to the brain and the descending aorta (also during the procedure). The main module has a projecting sleeve facing the ascending aorta.

The second module is an oriented, bent, tubular device implanted in the ascending aorta that overlaps with the main module's projecting sleeve. The connection between the modules incorporates an active fixation mechanism to ensure fixation and seal. The self-expanding stent grafts are composed of a nitinol skeleton, Dacron fabric, and tantalum radiopaque markers for correct rotational and longitudinal deployment. The delivery systems of both modules are precurved to reduce manipulation and friction at the arch; a 20-F introducer is required.

In the initial 25 patients treated with the single-branch device into the brachiocephalic trunk, there were no type I endoleaks or ruptures observed during follow-up of at least 1 year and no reports of permanent perioperative stroke, with only two cases of temporary strokes with full recovery.

Endospan is in the process of seeking CE Mark approval for the Nexus system after completing the required clinical trial. The company expects the platform to be the first off-the-shelf branched endovascular system to treat patients diagnosed with aortic pathology in or near the aortic arch to gain CE Mark approval.



*Courtesy of Endospan*

## RELAYBRANCH THORACIC STENT GRAFT SYSTEM

By Martin Czerny, MD, MBA

The RelayBranch thoracic stent graft system (Terumo Aortic) consists of a nonbare stent main body graft that is deployed in zone 0 and has two anterograde tunnels that give way to a large cannulation window. Supra-aortic branch grafts are deployed within the tunnels for the brachiocephalic trunk (posterior tunnel) and the LCC artery (anterior tunnel) and feature a similar proximal clasp system to the main body graft that allows for precise placement within the tunnels. The tunnels also feature Lock Stents, which are dull barbs that provide secure engagement with the stent apices of the branch grafts to prevent modular disconnection.

The preferred approach is to always revascularize the LSA first during the same procedure—a carotid-to-subclavian bypass with a high off-spring at the level of the LCC artery. This is because the site for endovascular extension to the LCC artery is chosen caudal to the site of the bypass offspring, as this allows manipulation in a surgically untouched area.

The main body of the device is inserted via either surgical cutdown or percutaneously with a preclosure approach using two Perclose ProGlide systems (Abbott Vascular) according to the size and quality of the common femoral arteries. After having deployed the main body using rapid pacing via a temporary pacemaker wire in the right ventricle, the aforementioned tunnels are cannulated via surgical cutdowns and the supra-aortic extensions are inserted with the cranial landing zone being the brachiocephalic trunk on the right and the common carotid artery on the left. If needed, distal extensions to the descending aorta are then inserted.

A 2018 publication on the shared experience of four centers describes a series of 15 patients with outcomes including an in-hospital mortality rate of 6.7%, disabling stroke rate of 6.7%, and nondisabling stroke rate of 13.3%.<sup>1</sup> Type I and III endoleaks occurred in 6.7%. The median follow-up period was 263 days (first quartile, 84 days; second quartile, 564 days). Four patients died during follow-up. Aortic-related survival was 100%.

Current worldwide clinical experience with the RelayBranch system has reached 150 patients in Europe, Asia, and Latin America. In 2018, Terumo Aortic began enrolling patients in the RelayBranch FDA Early Feasibility Study in the United States. Upon completion of this trial, the RelayBranch system will be available as an off-the-shelf device.

*Martin Czerny, MD, MBA, is with the Department of Cardiovascular Surgery, Heart Center Freiburg University, and Faculty of Medicine, University of Freiburg in Freiburg, Germany. He has disclosed that he is a consultant to Terumo Aortic (formerly Bolton Medical). Dr. Czerny may be reached at martin.czerny@universitaets-herzzentrum.de.*



Courtesy of Terumo Aortic.

## DEVICE DESIGN

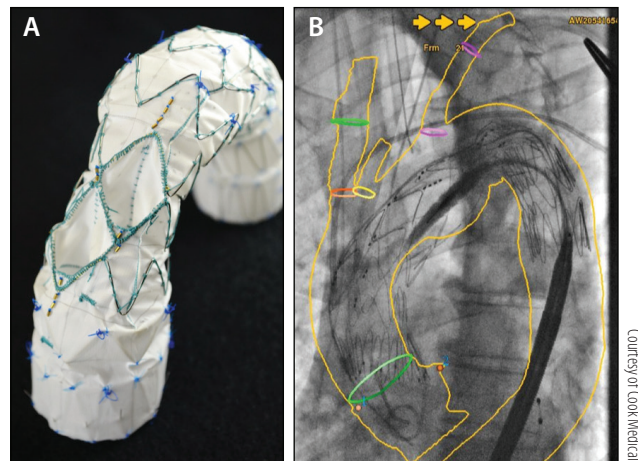
The Zenith arch branch graft (Cook Medical) was designed to target arch aneurysm and chronic dissection patients. The design and delivery of the graft have been previously described,<sup>2,3</sup> but they will be summarized here. The graft (Figure 1) is designed to seal in the healthy, ascending aorta and is customizable to have either one or two proximal internal sealing stents with active fixation (barbs) on the proximal-most sealing stent. Active fixation is critical in the arch region, as unlike thoracic endovascular aneurysm repair, where clinically significant migration is defined as movement > 10 mm, any motion of the arch device could crush the bridging components, causing catastrophic patient outcomes. A healthy, nondilated segment of aorta that is < 38 mm in diameter and > 40 mm in length is required proximal to the innominate artery (IA) and distal to the sinotubular junction for durable sealing to occur. The graft includes two or three internal branches for connection to the IA, left common carotid (LCC), and left subclavian artery (LSA). The graft and delivery system functionality have been optimized to achieve proximal seal with minimal “bird-beaking” and to prevent kinking in “gothic” arches. Distally, there are two internal sealing stents, but a distal extension can be utilized to treat extensive disease. A custom Zenith bridging component is used to connect the most proximal branch to the IA. A commercially available covered stent is used to bridge the second branch to the LCC and third branch to the LSA (when utilized).

1. Czerny M, Ryłski B, Morlock J, et al. Orthotopic branched endovascular aortic arch repair in patients who cannot undergo classical surgery. *Eur J Cardiothorac Surg*. 2018;53:1007–1012.



The device deployment is typically achieved via three access routes: femoral (for main body graft), left axillary (for the LCC covered bridging stent, advanced through a LSA-to-LCC bypass or transposition), and the right common carotid (for the bridging limb for the IA.) In order to control the device upon release from the delivery system, rapid ventricular pacing or inferior vena cava occlusion to lower cardiac output must be employed. Upon initial access to the IA and LCC, catheters are advanced to the IA and LCC ostia to optimize graft positioning. From femoral access, a Glidewire (Terumo Interventional Systems) is placed across the aortic valve and then exchanged for a stiff wire, with the tip of the wire curled in the left ventricle. The delivery system for the Zenith arch branch graft is tracked into place by advancing the tip of the delivery system through the aortic valve into the left ventricle. Markers on the branches are used to align the device with the origin of the IA and LCC (Figure 2). The delivery system is designed to automatically align the branches in a rotational orientation, thus simplifying the procedure with only longitudinal positioning of the device required. The self-aligning feature was designed to reduce manipulation of the delivery system and thus reduce the technical challenges seen in previous designs. Once the device is in position, the graft is unsheathed and released from the delivery system under rapid pacing. It is important to note that upon initial unsheathing, the delivery system tip is immediately pulled back to avoid further contact with the aortic valve. Finally, the branches are cannulated from above, and bridging components are placed.

For the three-branch system (Figure 3), the most distal (LSA) branch faces retrograde for access from a femoral approach. In this case, a preloaded wire and catheter are placed through the LSA branch and proximal to the graft edge. Upon unsheathing the device, the preloaded wire is exchanged with a second stiff wire and left proximal to the device when it is released from the delivery system. Once, the IA and LCC branches have been placed, the entire delivery system (including the first stiff wire) is removed over the second stiff wire. A short 20-F sheath is placed over the remaining wire to seal the femoral puncture site. A longer access sheath is next advanced through the 20-F sheath to the level of the branch to aid in branch cannulation, and finally, the third bridging graft is placed. It is important to note that the access to the LSA branch vessel is obtained after the bridging




**Figure 2.** View of the arch branch device demonstrating the radiopaque (gold) markers for alignment of innominate and left common carotid arteries (A). A deployed graft showing appropriate placement of the markers to allow for easy branch cannulation (B).

stents for the IA and LCC are placed to further protect the patient from embolic risk.

### CLINICAL EXPERIENCE

A retrospective, multicenter analysis of the first 38 patients treated with the inner branch arch graft deployed using the technique described in the previous section was published in 2014.<sup>3</sup> As a pioneer series, these data include the early learning curve for experienced practitioners using this complex device. An American Society of Anesthesiologists score of 3 or 4 was found in 34 of 38 (89.5%) patients. Five (13.2%) patients died within 30 days of the procedure, and there were six cerebrovascular complications noted at follow-up. Thirty-day mortality was 30% in the first 10 patients and 7.1% in the



**Figure 3.** A three-branch arch device with preloaded LSA branch.

**TABLE 1. DETAILS OF 286 CONSECUTIVELY IMPLANTED A-BRANCH ENDOGRAFTS**

Proximal Diameter (mm)	Number of Patients	Length (mm)	Average Number of Proximal Sealing Stents
34	19 (7%)	225.6	1.63
36	25 (9%)	230.0	1.24
38	45 (16%)	238.3	1.33
40	37 (13%)	234.6	1.46
42	45 (16%)	236.2	1.47
44	30 (10%)	233.8	1.60
46	85 (30%)	240.9	1.65

subsequent 28 patients, demonstrating that there was a learning curve with patient selection and performing the procedure. If death and neurologic complications were pooled, the risk of this composite outcome was significantly higher among the first 10 patients ( $P = .019$ ) than in the subsequent 28. This initial study demonstrated the feasibility of total endovascular arch repair in fragile patients.

Following the pioneering experience, three high-volume aortic centers published their experience using this technology among 27 patients, performed after the patients included in the first study.<sup>4</sup> The technical success was 100%, without perioperative death. Major complications included two major and one minor strokes and two cases of transient spinal cord ischemia. A significant reduction in overall mortality was observed compared to the pioneering experience (3.7% vs 23.6%, respectively;  $P = .02$ ). The authors concluded that they observed an improvement in patient outcomes compared with the early experience and confirmed the feasibility of total endovascular arch repair in patients who are unfit for open surgery with strict adherence to inclusion and exclusion criteria.

Last year, we reported the results of the first 30 procedures performed by our group,<sup>5</sup> with an operative mortality rate of 10.0%, permanent stroke rate of 3.3%, permanent spinal cord injury was 0%, and renal failure was 0%. We noticed that in patients who had undergone previous open ascending aortic repair (17/30), there was no incidence of in-hospital death, stroke, or spinal cord ischemia and one transient ischemic attack. Patients who develop aortic arch aneurysms in the years following open ascending aortic replacement for acute type A dissection are at increased risk of complications with open surgery. The presence of a prosthetic graft in the ascending aorta can act as an ideal proximal landing material for an arch endograft, precluding the risk of retrograde dissection.

We assessed the proportion of patients with previous open ascending aortic replacement for type A dissection, who may be anatomically suitable for branched arch endograft repair.<sup>6</sup> We reported that 71.2% patients had a suitable proximal landing zone in the previous ascending aortic graft. The reasons for unsuitable neck were that the graft was too short, there was a major kink ( $\geq 90^\circ$ ) in the graft, or the diameter was too large ( $> 38$  mm). We have collected the global experience (unpublished data) with arch branched endografting (a-Branch, Cook Medical) during follow-up after open type A repair. In 70 consecutive patients, the in-hospital combined mortality and stroke rate was 4% ( $n = 3$ ), including one minor stroke, one major stroke causing death, and one death following multiorgan failure. A high reintervention rate (29%) was observed, mostly to treat distal evolution of dissection.

## DISCUSSION

To date, more than 300 arch devices have been placed globally with excellent technical feasibility. As with any advanced endovascular procedure, a learning curve must be overcome to understand aspects of the device design, implantation procedure, and anatomical criteria to optimize longer-term outcomes. Even with a steep learning curve, 30-day mortality rates for the endovascular repair groups are similar to traditional open repair, despite the endo group consisting of a significantly more morbid patient population. Additionally, once the learning curve has been overcome, the 30-day mortality rates have significantly dropped in the hands of experienced operators.<sup>4</sup>

The arch device has the potential to be “off the shelf,” with diameters ranging from 34 to 46 mm, consisting of one or two seal configurations, and 240 mm in length to treat ~90% of arch patients. It should be noted that due to sealing in the ascending aorta, additional oversizing has been utilized in these patients, with 30% of patients receiving 46-mm proximal diameter devices, > 55% implanted with devices > 42 mm, and > 80% of patients being implanted with devices > 38 mm (Table 1). The design builds on the Zenith platform with significant clinical history and utilizing materials with proven performance history. In addition, the incorporation of the self-aligning and controlled release delivery system allows for precise placement of the device with minimal manipulation required to achieve branch alignment. Finally, the arch design utilizes strong sealing stents, active fixation, and delivery features that address type I endoleak, migration, and conformance issues that have historically plagued endovascular repair. The design has demonstrated excellent results through 12-month follow-up, with zero type I endoleaks and migrations to date when the device is implanted according to device limits reported by Haulon et al.<sup>3</sup>

With continued improvements in outcomes after the initial learning experience with arch endovascular repair, specifically related to 30-day mortality, stroke, and secondary interventions, the procedure has proven beneficial to those with elevated surgical risk. Furthermore, patients presenting with a postdissection aortic arch aneurysm after open ascending aortic replacement for a type A dissection may be the ideal candidate for arch endografting, as the anatomy presents with an excellent proximal seal site<sup>6</sup> and the need for redo sternotomy for a second open repair places these patients at an even higher surgical risk.

Further collaborations between cardiothoracic and vascular surgery are needed to ensure that initial open repairs of type A dissections are performed such that if postdissection aneurysms do occur, the initial repair provides an optimal landing zone for a future endovascular graft, if needed. Finally, larger cohort studies with mid- and long-term follow-up are warranted to determine the long-term durability of the repair and also the quality-of-life improvements for these patients. ■

1. Tsilimparis N, Debus E, von Kodolitsch Y, et al. Branched versus fenestrated endografts for endovascular repair of aortic arch lesions. *J Vasc Surg.* 2016;64:592-599.
2. Lioupis C, Corriveau MM, MacKenzie KS, et al. Treatment of aortic arch aneurysms with a modular transfemoral multi-branched stent graft: initial experience. *Eur J Vasc Endovasc Surg.* 2012;43:525-532.
3. Haulon S, Greenberg RK, Spear R, et al. Global experience with an inner branched arch endograft. *J Thorac Cardiovasc Surg.* 2014;148:1709-1716.
4. Spear R, Haulon S, Ohki T, et al. Editor's Choice—subsequent results for arch aneurysm repair with inner branched endografts. *Eur J Vasc Endovascular Surg.* 2016;51:380-385.
5. Clough RE, Spear R, Van Calster K, et al. Case series of aortic arch disease treated with branched stent-grafts. *Br J Surg.* 2018;105:358-365.
6. Milne CP, Amako M, Spear R, et al. Inner-branched endografts for the treatment of aortic arch aneurysms after open ascending aortic replacement for type A dissection. *Ann Thorac Surg.* 2016;102:2028-2035.

### Stéphan Haulon, MD, PhD

Aortic Center  
Hôpital Marie Lannelongue  
Université Paris Sud  
Le Plessis Robinson, France  
haulon@hotmail.com

*Disclosures: Consultant to Cook Medical.*

### Jarin Kratzberg, PhD

Research Engineer  
Cook Medical  
Bloomington, Illinois

*Disclosures: Employee of Cook Medical.*

### Julien Guihaire, MD, PhD

Aortic Center  
Hôpital Marie Lannelongue  
Université Paris Sud  
Le Plessis Robinson, France

*Disclosures: None.*

### Dominique Fabre, MD, PhD

Aortic Center  
Hôpital Marie Lannelongue  
Université Paris Sud  
Le Plessis Robinson, France

*Disclosures: None.*