

# Traumatic IVC Injury

## Repair: The Endovascular Alternative

Although surgical management has been refined, more protective techniques are still needed for these challenging lesions.

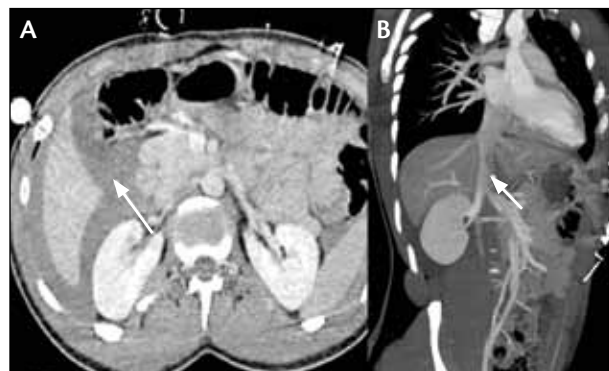**BY GABRIELE PIFFARETTI, MD, PhD; GIANPAOLO CARRAFIELLO, MD;  
FILIPPO PIACENTINO, MD; AND PATRIZIO CASTELLI, MD, FACS**

**T**raumatic lesions of the inferior vena cava (IVC) account for approximately 25% of abdominal vascular injuries and are among the most challenging and lethal lesions sustained by trauma patients. Whether caused by blunt or penetrating mechanisms of injury, the overall mortality rate is up to 92%; as many as 50% of patients with such injuries die before reaching medical care, and the mortality rate among patients who arrive at the trauma center with signs of life and/or receive operative treatment ranges between 20% and 57%.<sup>1</sup>

During the last few decades, the surgical management of traumatic IVC injury has improved, but results are not well updated.<sup>2-4</sup> This is supported by the fact that endovascular treatment for this type of vascular trauma has not been addressed in the literature and that endovascular techniques for the venous system have not developed as widely as those for the arterial segment.

### CASE REPORT

A 23-year-old man was involved in a motorcycle-car crash. Upon admission to the emergency department, resuscitation therapies were carried out according to advanced trauma life support. He presented with mild hypotension (systolic blood pressure of 110/50 mm Hg) and tachycardia (102 bt/min). Blood tests revealed a hemoglobin level of 12.2 g/dL, platelet count of 78/mm<sup>3</sup>, GOT of 340 IU/L, GPT of 309 IU/L, and creatine kinase of 891 IU/L. Radiography showed bilateral pneumothorax and a right lung contusion. Total-body spiral CT revealed a contusion of the fourth and eighth hepatic



**Figure 1. Preoperative CT angiography of the perihepatic hematoma (arrow, A), which had no sign of caval rupture (arrow, B).**

segments until the hilum, a fracture in the middle third of the upper spleen that extended until the hilum, and the perihepatic hematoma, which had no signs of active bleeding from the retroperitoneal large vessels (Figure 1). The Injury Severity Score was 30. A right chest tube was inserted, and the patient was taken to the operating room for a laparotomy, which ruled out the need for splenectomy.

During the intervention, the patient became hemodynamically unstable (systolic blood pressure, 70/50 mm Hg) when active bleeding abruptly occurred from the posterior segment of the liver. Temporary packing was performed, the right common femoral vein was isolated at the groin, and a cavogram was obtained. A bleeding tear was not identified at the level of segments 1 and 3 when the left renal vein and the suprahepatic veins were clearly identi-

fied. A 32- x 58-mm tube endograft (Zenith, Cook Medical; Bloomington, IN) was deployed in segment 2 just below the suprahepatic veins. The packing was temporarily removed, and the final angiogram confirmed the patency of the endograft and the absence of active bleeding; no active bleeding was observed from the posterior segment of the liver. The duration of the entire endovascular procedure was 8 minutes.

The patient was admitted to the intensive care unit for 7 days. The postoperative course was uneventful, and he was discharged on postoperative day 14, when CT angiography confirmed patency of the renal veins and endograft and there was no sign of bleeding (Figure 2). His last follow-up was 12 months after the procedure, and he had no sign of deep venous thrombosis. Duplex ultrasound confirmed the patency of the endograft with no sign of stent-induced caval stenosis or intrastent thrombosis.

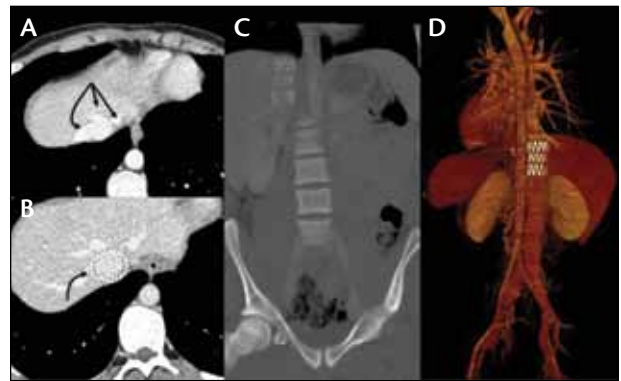
### ANATOMIC VARIABLES AND OUTCOMES OF SURGICAL REPAIR

The two most important factors for postoperative survival with traumatic IVC rupture are (1) the hemodynamic condition of the patient on arrival and (2) the location of the caval lesion. These key points emphasize the importance of a prompt diagnosis, rapid control of the injuries, and call attention to the challenging surgical maneuvers that are required to gain vascular control.

It has been observed that patients who arrive in shock and those who are still actively bleeding at the time of laparotomy have the worst outcomes. A recent comparison of survivors with nonsurvivors confirmed that factors related to hemorrhagic shock (systolic blood pressure, hemoglobin and bicarbonate levels, volume of blood products, blood loss, temperature, and coagulation) were significantly different between the two groups.<sup>2</sup> Of particular significance, hypotension at the scene of trauma was the most predictive variable that negatively affected postoperative survival. Additionally, in most patients with IVC injury who received surgical treatment, maximum shock levels were observed during the portion of the procedure when the hematoma was opened and caval hemorrhage due to decompression occurred.<sup>1,3</sup>

Attempting repair of a traumatic injury of the IVC at all segments requires great surgical skills; wide exposure is of the utmost importance. The most practical classification to define topographic anatomy of the IVC divides it into three segments:

- **Infrarenal (segment 1):** extends from the confluence of the common iliac veins to the renal veins;



**Figure 2.** Postoperative computed tomography angiography showed the patency of the suprahepatic veins (A) and the successful deployment of the endograft (B). Postprocessing reconstructions showed the position of the endograft (C, D).

- **Suprarenal (segment 2):** extends between the renal and hepatic veins. This segment should be specified as infrahepatic between the inferior edge of the liver and the confluence of the renal veins, and retrohepatic behind the liver;
- **Suprahepatic (segment 3):** extends between the hepatic veins and the right atrium.

Infrarenal location is associated with the lowest mortality rate (23%), whereas both suprarenal and retrohepatic locations are associated with a mortality rate of approximately 70%.<sup>1-5</sup> This is probably due to anatomic and technical reasons. First, although the full exposure of the caval bifurcation zone may need the division of the right common iliac artery between clamps, this is a more familiar territory for vascular surgeons than the other segments of the IVC. Second, this injury location is more frequently repaired with venorrhaphy.

More complex suprarenal injuries and any other injury that requires prosthetic repair are burdened by higher mortality rates. In particular, active hemorrhage from the retrohepatic IVC is infrequently controlled; the radical hepatic mobilization to expose the retrohepatic injured IVC is associated with an extremely high mortality rate and is not advisable unless active bleeding is present and cannot be contained by perihepatic packing.

In spite of that, the results of successful repair are durable. Patients who survive IVC injuries tend to be long-term survivors regardless of the method of management, and complications are very uncommon.<sup>1</sup> In summary, minimization of the shock period and rapid control of active caval hemorrhage are the principal goals in definitive surgical management of patients with traumatic IVC injuries.<sup>5</sup>

## THE ENDOVASCULAR ALTERNATIVE

Innovative operative techniques to deal with supra-renal and retrohepatic IVC injuries have been advocated because these injuries are invariably associated with increased mortality rates.<sup>3</sup> Endovascular technology has revolutionized the management of several degenerative pathologies as an important alternative approach for traumatic lesions such as occlusive dissection, arteriovenous fistulas, and false aneurysms. The main advantages of the endovascular approach include the speed with which endovascular procedures can be performed and the minimal additional tissue trauma from remote accesses. This is particularly attractive in the trauma setting to rapidly control bleeding, especially after injuries at the level of the suprarenal vena cava or the ilio caval bifurcation, in which hemostasis requires extensive dissection that increases the operative time and potentially worsens either the injury or bleeding.<sup>6-9</sup>

Effective management of patients with IVC injuries relies heavily on the prompt transportation of these patients from the accident scene to a medical center that is capable of delivering aggressive and definitive medical care.<sup>2,3</sup> In this sense, traumatic injuries of the IVC mimic a concern already voiced about endovascular repair of ruptured aneurysms: the effect of preoperative delay. Most patients with major IVC lesions present with hemodynamic instability that necessitates urgent laparotomy, but patients with relatively stable or contained hematomas can tolerate additional evaluation to exclude intra-abdominal synchronous and competitive injuries and to optimize the sizing of the target vessels. Establishing a management protocol may help reduce preoperative shock time and opti-

mize subsequent treatment.<sup>3</sup> Prompt availability of CT facilities for urgent cases is essential for a successful outcome and reducing the period of preoperative shock.<sup>9</sup> The routine and successful use of endografts for arterial pathology has made vascular surgeons handier with the material and techniques of endovascular procedures. The availability of a multidisciplinary team may further refine treatment strategies, including the endovascular approach, and help gain rapid vascular control of active hemorrhage and avoid additional operative dissection of the IVC or adjacent structures.<sup>9</sup>

The endograft's remote insertion site may help limit the invasiveness of the endovascular approach. In contrast to arterial interventions, where the diseased femoroiliac vessels may rule out the use of endovascular devices, vein vessels are almost always viable. A common femoral vein approach should be used preferentially; the working length of the devices produced for aortic anatomies are also suitable for the adjacent IVC. Alternatively, the devices may be deployed via a jugular approach, but this route should not be considered a first choice given the size of the delivery system and the more tortuous path to negotiate the targeted IVC area.<sup>8,9</sup>

No dedicated devices have been produced for use in the IVC, and the available endografts have no instructions for use for vein pathologies. In these life-threatening situations, however, careful consideration should balance the potential risks of inserting a device designed for intra-arterial use to treat a venous injury against the extremely high risk of a fatal outcome. Even though very rare, literature has reported successful treatment of traumatic IVC injuries with endografts after conventional surgical options were exhausted to arrest the bleeding.<sup>6-9</sup> In these situations, endografts could be used to rapidly seal off the bleeding, borrowing the "damage control surgery" concept: endografts may be used as a "bridge" treatment to a subsequent definitive repair after turning an emergent situation into a more manageable one.

## PENDING MATTERS

As is true for conventional open surgery, endovascular treatment of traumatic vascular injuries is not free from concerns. First and foremost, the available devices are not intended for veins, potentially leading to erosion or rupture of the IVC. From a technical point of view, branch occlusion may be required in some circumstances; fenestrated endografts have been reported to be effective,<sup>6</sup> but they need to be customized, and time is crucial in these circumstances. Despite oral anti-coagulant therapy, thrombosis may occur, and there is

### TAKE-HOME POINTS

- Early outcome is still negatively influenced by the hemodynamic status of the patient on arrival, but results of successful repair are durable.
- Rapid diagnosis and vascular control are essential to limit mortality after traumatic injury of the IVC; in this situation, retrohepatic IVC injuries carry the worst prognosis.
- Endograft repair of traumatic injuries of the IVC is technically feasible and effective to rapidly seal the bleeding tear.
- Hemorrhagic patients after blunt traumas should be evaluated to rule out or early identify caval injuries and reduce the time of preoperative shock.

risk of progressive IVC narrowing and pulmonary embolization. Close follow-up of these patients is strongly advised.

Refinement of techniques and devices for endovascular vein repair could confirm this approach as an effective alternative for traumatic injuries. ■

*Gabriele Piffaretti, MD, PhD, is with the Department of Vascular Surgery, Department of Surgery and Morphological Sciences, Circolo University Hospital, University of Insubria School of Medicine in Varese, Italy. He has disclosed that he has no financial interests related to this article. Dr. Piffaretti may be reached at +39 0332 393259; gabriele.piffaretti@uninsubria.it.*

*Gianpaolo Carrafiello, MD, is with the Department of Vascular Surgery and is Chief of Interventional Radiology, Department of Surgery and Morphological Sciences, Circolo University Hospital, University of Insubria School of Medicine in Varese, Italy. He has disclosed that he has no financial interests related to this article.*

*Filippo Piacentino MD, is with the Departments of Vascular Surgery and Interventional Radiology, Department of Surgery and Morphological Sciences, Circolo University Hospital, University of Insubria School of Medicine in Varese, Italy. He has disclosed that he has no financial interests related to this article.*

*Patrizio Castelli, MD, FACS, is Chief of Vascular Surgery, Department of Surgery and Morphological Sciences, Circolo University Hospital, University of Insubria School of Medicine in Varese, Italy. He has disclosed that he has no financial interests related to this article.*

1. Buckman RF, Pathak AS, Badellino MM, et al. Injuries of the inferior vena cava. *Surg Clin North Am.* 2001;81:1431-1447.
2. Kuehne J, Frankhouse J, Modrall G, et al. Determinants of survival after inferior vena cava trauma. *Am Surg.* 1999;65:976-981.
3. Hansen CJ, Bernadas C, West MA, et al. Abdominal vena caval injuries: outcomes remain dismal. *Surgery.* 2000;128:572-578.
4. Asensio JA, Chahwan S, Hanpeter D, et al. Operative management and outcome of 302 abdominal vascular injuries. *Am J Surg.* 2000;180:528-533; discussion 533-534.
5. Huerta S, Bui TD, Nguyen TH, et al. Predictors of mortality and management of patients with traumatic inferior vena cava injuries. *Am Surg.* 2006;72:290-296.
6. Watarida S, Nishi T, Furukawa A, et al. Fenestrated stent-graft for traumatic juxtahepatic inferior vena cava injury. *J Endovasc Ther.* 2002;9:134-137.
7. Erzurum VZ, Shoup M, Borge M, et al. Inferior vena cava endograft to control surgically inaccessible hemorrhage. *J Vasc Surg.* 2003;38:1437-1439.
8. de Naeyer G, Degrieck I. Emergent infrahepatic vena cava stenting for life-threatening perforation. *J Vasc Surg.* 2005;41:552-554.
9. Castelli P, Caronno R, Piffaretti G, et al. Emergency endovascular repair for traumatic injury of the inferior vena cava. *Eur J Cardiothorac Surg.* 2005;28:906-908.