

Endovascular Treatment of Type A Dissections

Barriers to therapy and considerations for access and approach.

BY NICOLA MANGIALARDI, MD; EUGENIA SERRAO, MD; SONIA RONCHEY, MD, PHD;
HOLTA KASEMI, MD; AND MATTEO ORRICO, MD

Type A aortic dissection (TAAD) is a life-threatening emergency and requires immediate surgical intervention. For untreated TAADs, mortality risk increases up to 50% in the first 24 hours and 75% within 2 weeks after the initial event.¹ Medical treatment is associated with a poor outcome, with a mortality rate of 60%.^{2,3} Although surgical techniques and perioperative care have significantly improved, mortality remains high and is reported between 30% and 60%, especially in high-risk patients.⁴⁻⁶

Over the last decades, endovascular intervention has emerged as the therapy of choice in patients with descending thoracic and abdominal aortic disease.⁷ The introduction of new techniques and extensive experience has broadened the indication for these interventions, and even diseases affecting the ascending aorta can be treated. Primary reports focused on retrograde type A dissections affecting the aortic arch, in which the primary entry tear was located in the descending segment. These patients were treated by stent graft placement in the descending aorta.⁸ Recently, stent graft placement in the ascending aorta for the treatment of aneurysms, pseudoaneurysms, penetrating ulcers, intramural hematomas, and even type A dissections has been described in case reports.⁹⁻¹²

ANATOMIC AND ENDOGRAFT LIMITS FOR TAAD ENDOVASCULAR TREATMENT

A thorough understanding of the anatomic limits of TAAD and the adjacent anatomy is a prerequisite before such procedures are performed. Inclusion criteria are (1) entry tear in the ascending aorta, (2) distance

of at least 2 cm between the sinotubular junction and the entry tear, (3) distance of at least 0.5 cm between the entry tear and the brachiocephalic trunk, (4) no signs of cardiac tamponade or severe aortic regurgitation, (5) no signs of ischemia of aortic branches, (6) adequate femoral and iliac arteries, (7) no cardiac revascularization from the ascending aorta, and (8) aortic diameter < 38 mm.¹³

Because the proximal and distal landing zones are very close to the coronary and innominate arteries, stent graft placement in the ascending aorta may be performed only in selected cases. Moon et al showed that 32% of patients with TAADs were anatomically suitable for endovascular repair, as valvular involvement was absent, and the length and diameter of the proximal sealing zones were appropriate.¹⁴ CT scan imaging studies show that endovascular repair is anatomically feasible in about 30% of patients with TAAD with a proximal entry tear in the ascending aorta.¹⁵ This percentage of patients may increase up to 39% with the use of extra-anatomic bypass, such as a left-to-right carotid-carotid bypass, in order to obtain an adequate distal landing zone.

Specifically designed endografts for the ascending aorta with a longer delivery system (100 cm) and a short tip (2 cm) are necessary for the endovascular treatment of TAADs. Recently, Metcalfe et al published their experience with the implementation of a stent designed specifically for the ascending aorta in a TAAD patient. The stent consisted of a 65-mm covered component and proximal and distal bare stents.¹⁶ The use of bare stents in aortic dissection remains highly

debated, because this may induce a new dissection or a reentry tear.

Precise endograft deployment is ensured by cardiac pacing (180 beats/min), used to reach a systolic blood pressure up to 40 to 60 mm Hg to prevent dislodgement of the stent graft during the procedure.

Adequate endograft oversizing with respect to the true lumen diameter is fundamental to avoid complications such as aortic valve insufficiency because of stent graft–induced aortic dilatation. A maximum oversizing of 10% is indicated in the case of TAADs and 20% in the case of previous ascending aorta replacement and subsequent TAADs.¹³ Transesophageal echocardiography (TEE) should be performed in all cases to assess cardiac and aortic valve function in combination with angiography to confirm the patency of the supra-aortic branches and coronary arteries.

ACCESS SITE OPTIONS

Access artery selection is an important part of preoperative planning of the endovascular procedure. Adequate femoral and iliac vessels are necessary for endograft placement. In patients with small, tortuous, stenotic, or heavily calcified access site arteries, other options may be considered. In 2000, Dorros et al reported their first case of TAAD treated with an endovascular technique through a transseptal approach.¹⁷

The transapical approach through the left ventricular apex using left thoracotomy was described by Murakami et al for the endovascular treatment of an ascending aorta pseudoaneurysm.¹⁸ The tips of stent graft delivery systems for the ascending aorta are so long that there may be a danger of damaging the aortic valve, coronary artery, and left ventricle. Another way to provide blood flow to the supra-aortic vessels during the transapical approach is the use of periscope grafts oriented from the vessels down the descending thoracic aorta, implanted in the supra-aortic vessels before the main stent graft placement. The technique was described by Krankenberg et al for ascending aortic aneurysm repair and may be useful in case of TAAD if retrograde endograft placement is not feasible.¹⁹

Right common carotid artery (RCCA) and left common carotid artery (LCCA) access sites have also been described for ascending aorta pseudoaneurysm endovascular treatment.^{20,21} This may be another way to facilitate endograft delivery for TAADs.

Other retrograde endograft deployments may be performed using the iliac conduits, internal endoconduits, or the retroperitoneal approach described and performed for TEVAR.²²⁻²⁴

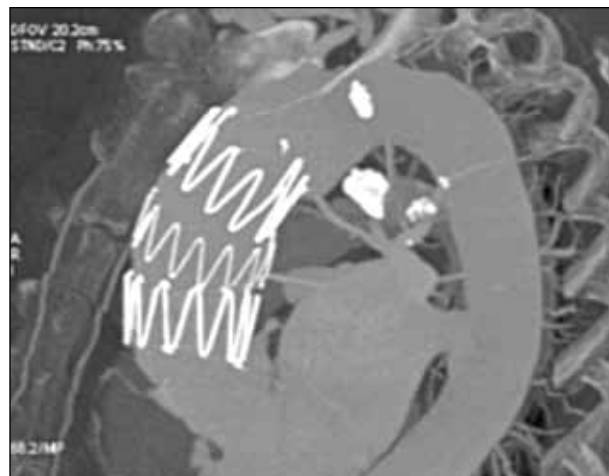


Figure 1. A standard Zenith TX2 (Cook Medical, Bloomington, IN) endograft was used to treat the first TAAD.

OUR EXPERIENCE

Thirty-seven patients with TAAD were admitted to the emergency department between April 2009 and June 2012. A multidisciplinary team evaluated nine of these patients, who were considered high risk for open TAAD repair due to comorbidities and previous sternotomy; their anatomic characteristics were studied for an endovascular approach. Four of these patients met our inclusion criteria (mean age, 70 years; two men). One patient had prior aortic valve repair. Two patients had previous ascending aortic repair for TAAD (one of which was associated with aortic valve replacement) with residual entry tear in the ascending aorta.

Computed tomography angiography (CTA) images were acquired on multislice CT scan with a 0.625-mm detector configuration; 1.25-mm contrast axial images and retroconstruction at 0.625 mm from the origin of the carotid arteries to the femoral arteries were also obtained. The acquired CTA data sets were transferred to a workstation (Osirix 3.9.4—64-bit) for analysis. A center lumen line was generated, and the distances between the entry tear and the sinotubular junction and innominate artery were measured. Stent graft selection was based on the aortic diameter at the level of the entry tear, with at least 10% oversizing in respect to the true lumen but not exceeding the original aortic diameter. In case of previous ascending aortic graft replacement, 20% oversizing with respect to the graft diameter was performed. Aortic valve involvement was investigated with the use of TEE.

Three patients were treated in an acute setting (< 8 hours after acute onset of symptoms), and the fourth patient's procedure was delayed (48 hours). Written informed consent was obtained before the procedures.

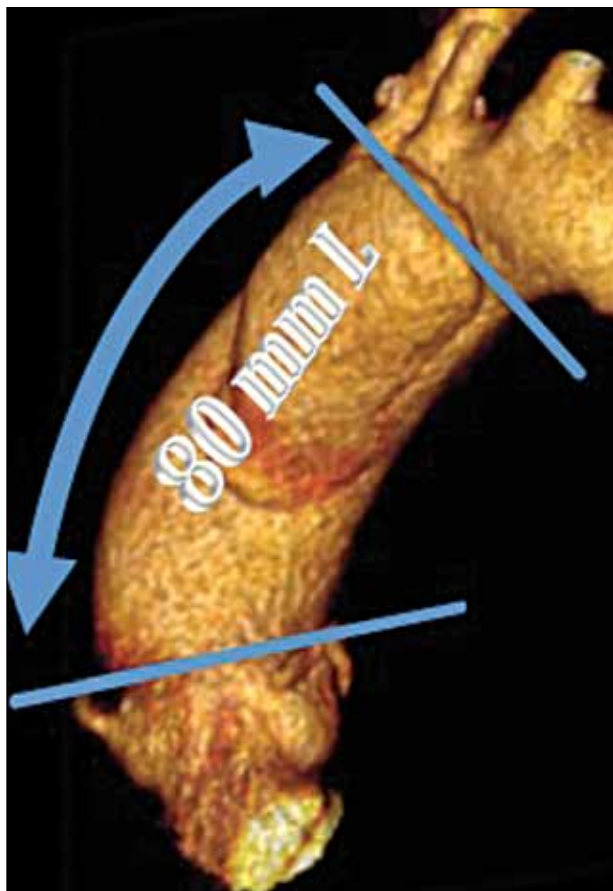


Figure 2. A preoperative CT scan showing 80-mm distance between the sinotubular junction and the brachiocephalic trunk.

All procedures were performed under general anesthesia via surgical femoral access. Supra-aortic vessel access was achieved in three patients by introducing a guidewire into the arch and descending aorta through a percutaneous right brachial access. The fourth patient had TAAD and brachiocephalic trunk symptomatic dissecting dilatation (32 mm; no neurologic signs, neck pain not responding to medical therapy) 48 months after ascending aorta replacement; the patient underwent a left common carotid-right common carotid-right subclavian artery bypass.

Standard Zenith TX2 (Cook Medical, Bloomington, IN) was used in one patient (Figure 1), and an off-the-shelf Zenith TX2 ESBE-custom device for the ascending aorta (Cook Medical) was used in the other three patients. Stent graft length ranged between 55 and 81 mm, and the diameter was between 35 and 40 mm (Figure 2). Cardiac pacing was performed just before endograft deployment. TEE and completion angiography were used to verify the aortic valve function and

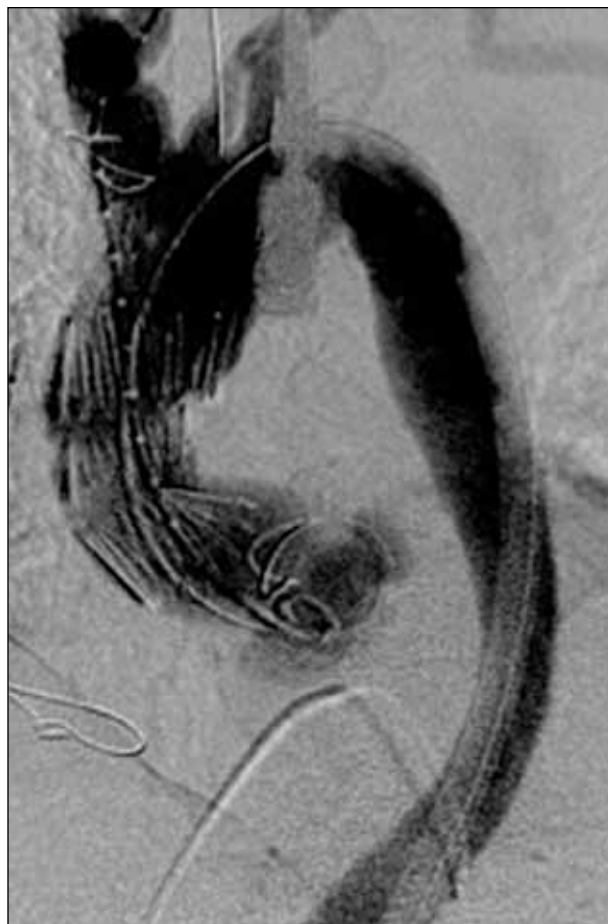

Figure 3. A completion angiogram showing transfemoral endograft deployment in the ascending aorta.

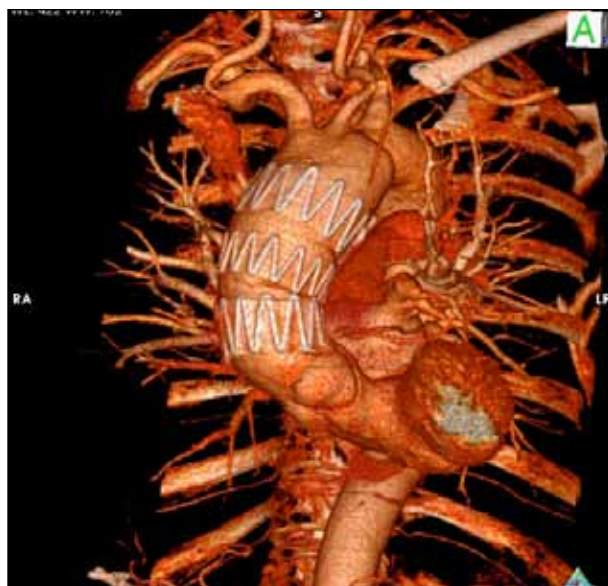

Figure 4. Four-year follow-up CT scan showing complete false lumen thrombosis of the ascending aorta.

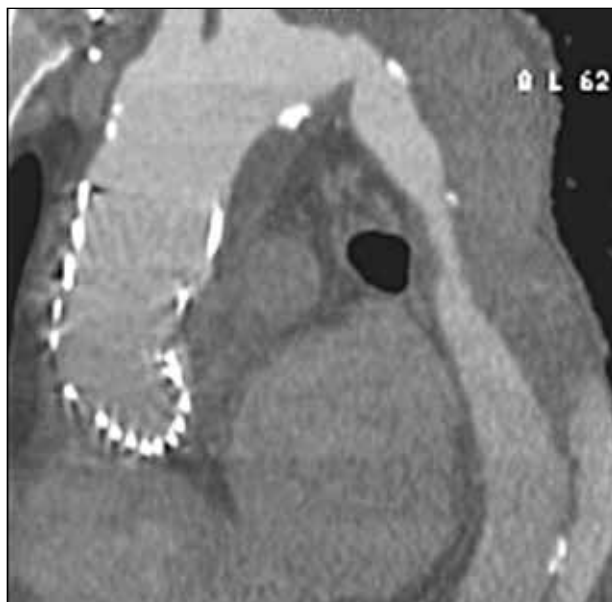


Figure 5. Four-year follow-up CT scan showing partial false lumen thrombosis of the descending aorta.

patency of the supra-aortic and coronary vessels and to evaluate the dissection exclusion (Figure 3).

Technical success was 100%. No deaths were registered during the perioperative and follow-up period (range, 16–51 months; mean, 29 months). Complete false lumen thrombosis of the ascending aorta was achieved in three patients (Figure 4), while in the fourth patient, the false lumen is still patent without aortic enlargement. The patient remains asymptomatic at 21-month follow-up. Complete descending false lumen thrombosis was achieved in two patients; partial thrombosis was observed in the other two (Figure 5).

CONCLUSION

Endovascular procedures in TAAD patients harbor considerable risk, which is associated with aortic arch manipulation, dissection extension, or thrombus dislodgement because of stent graft positioning and deployment. Previous ascending aortic replacement eliminates the risk of retrograde dissection and reduces the risk of cardiac tamponade or aortic rupture. The presence of a mechanical valve makes the procedure more challenging. Our experience demonstrated that endovascular treatment of TAADs is feasible in selected patients and is associated with favorable results. Further research remains mandatory. ■

Nicola Mangialardi, MD, is with the Department of Vascular Surgery at San Filippo Neri Hospital in Rome, Italy. He has disclosed no financial interest related to this article.

Dr. Mangialardi may be reached at +39 06 3306 3938; n.mangialardi@sanfilippo.roma.it.

Eugenia Serrao, MD, is with the Department of Vascular Surgery at San Filippo Neri Hospital in Rome, Italy. She has disclosed no financial interest related to this article.

Sonia Ronchey, MD, PhD, is with the Department of Vascular Surgery at San Filippo Neri Hospital in Rome, Italy. She has disclosed no financial interest related to this article.

Holta Kasemi, MD, is with the Department of Vascular Surgery at San Filippo Neri Hospital in Rome, Italy. She has disclosed no financial interest related to this article.

Matteo Orrico, MD, is with the Department of Vascular Surgery at San Filippo Neri Hospital in Rome, Italy. He has disclosed no financial interest related to this article.

1. Woo KM, Schneider JJ. High-risk chief complaints I: chest pain—the big three. *Emerg Med Clin N Am*. 2009;27:685–712.
2. Hagan PG, Nienaber CA, Isselbacher EM, et al. The International Registry of Acute Aortic Dissection (IRAD): new insights into an old disease. *JAMA*. 2000;283:897–903.
3. Mehta RH, O’Gara PT, Bossone E, et al. Acute type A aortic dissection in the elderly: clinical characteristics, management, and outcomes in the current era. *J Am Coll Cardiol*. 2002;40:685–692.
4. Trimarchi S, Nienaber CA, Rampoldi V, et al. Contemporary results of surgery in acute type A aortic dissection: the International Registry of Acute Aortic Dissection experience. *J Thorac Cardiovasc Surg*. 2005;129:112–122.
5. Piccardo A, Regesta T, Pansini S, et al. Should octogenarians be denied access to surgery for acute type A aortic dissection? *J Cardiovasc Surg (Torino)*. 2009;50:205–212.
6. Trimarchi S, Eagle KA, Nienaber CA, et al. Role of age in acute type A aortic dissection outcome: report from the International Registry of Acute Aortic Dissection (IRAD). *J Thorac Cardiovasc Surg*. 2010;140:784–789.
7. Dake MD, Miller DC, Semba CP, et al. Transluminal placement of endovascular stent-grafts for the treatment of descending thoracic aortic aneurysms. *N Engl J Med*. 1994;331:1729–1734.
8. Kato N, Shimono T, Hirano T, et al. Transluminal placement of endovascular stent-grafts for the treatment of type A aortic dissection with an entry tear in the descending thoracic aorta. *J Vasc Surg*. 2001;34:1023–1028.
9. Moon MC, Morales JP, Greenberg RK. The aortic arch and ascending aorta: are they within the endovascular realm? *Semin Vasc Surg*. 2007;20:97–107.
10. Akin I, Kische S, Nienaber CA. Indication, timing and results of endovascular treatment of type B dissection. *Eur J Vasc Endovasc Surg*. 2009;37:289–296.
11. Kolvenbach RR, Karmeli R, Pinter LS, et al. Endovascular management of ascending aortic pathology. *J Vasc Surg*. 2011;53:1431–1437.
12. Shabaneh B, Gregoric ID, Loyalka P, Krajcar Z. Complex endovascular repair of a large dissection of the ascending aorta in a 70-year-old man. *Tex Heart Inst J*. 2013;40:182–185.
13. Ronchey S, Serrao E, Alberti V, et al. Endovascular stenting of the ascending aorta for type A aortic dissections in patients at high risk for open surgery. *Eur J Vasc Endovasc Surg*. 2013;45:475–480.
14. Moon MC, Greenberg RK, Morales JP, et al. Computed tomography-based anatomic characterization of proximal aortic dissection with consideration for endovascular candidacy. *J Vasc Surg*. 2011;53:942–949.
15. Sobocinski J, O’Brien N, Maurel B, et al. Endovascular approaches to acute aortic type A dissection: a CT-based feasibility study. *Eur J Vasc Endovasc Surg*. 2011;42:442–447.
16. Metcalfe MJ, Karthikesalingam A, Black SA, et al. The first endovascular repair of an acute type A dissection using an endograft designed for the ascending aorta. *J Vasc Surg*. 2012;55:220–222.
17. Dorros G, Dorros AM, Planton S, et al. Trans-septal guidewire stabilization facilitates stent-graft deployment for persistent proximal ascending aortic dissection. *J Endovasc Ther*. 2000;7:506–512.
18. Murakami K, Kotani T, Ito C, et al. A case of thoracic endovascular aortic repair using a transapical approach through the left ventricular apex for an ascending aortic pseudoaneurysm. [Article in Japanese.] *Masui*. 2013;62:190–192.
19. Krankenberg H, Bader R, Sixt S, et al. Endovascular repair of ascending aortic aneurysm by transapical approach and periscope technique. *J Endovasc Ther*. 2013;20:13–17.
20. Lin PH, Kougias P, Huynh TT, et al. Endovascular repair of ascending aortic pseudoaneurysm: technical considerations of a common carotid artery approach using the Zenith aortic cuff endograft. *J Endovasc Ther*. 2007;14:794–798.
21. Gray BH, Langan EM 3rd, Manos G, et al. Technical strategy for the endovascular management of ascending aortic pseudoaneurysm. *Ann Vasc Surg*. 2012;26:734–738.
22. Tsilimiparis N, Dayama A, Perez S, Ricotta JJ 2nd. Iliac conduits for endovascular repair of aortic pathologies. *Eur J Vasc Endovasc Surg*. 2013;45:443–448.
23. Peterson BG, Matsumura JS. Internal endoconduit: an innovative technique to address unfavorable iliac artery anatomy encountered during thoracic endovascular aortic repair. *J Vasc Surg*. 2008;47:441–445.
24. Etezadi V, Katzen BT, Benenati JF, et al. Retroperitoneal versus direct femoral artery approach for thoracic endovascular aortic repair access: a case-control study. *Ann Vasc Surg*. 2011;25:340–344.