

Crossing Lower Extremity CTOs

A vascular surgeon's techniques for the endovascular treatment of complex lower extremity arterial lesions.

BY RICHARD PIN, MD

I am a fellowship-trained vascular surgeon whose comfort and security are grounded in traditional open vascular surgery. This background makes it somewhat surprising, even to myself, that almost all of my patients with lower extremity peripheral arterial disease are now treated endovascularly. For me, the growing appeal of a minimally invasive practice has developed from the realization that more and more difficult lesions can be effectively managed without having to make a single incision, without the propensity for postoperative pain and morbidity, and with much lower overall risk than open surgery.

As endovascular products continue to evolve with greater sophistication, immediate technical success and long-term results have improved. This progress has allowed the vascular surgeon to effectively intervene upon increasingly complex lesions through percutaneous techniques, thereby avoiding the need for surgery. Even within the past year, my patients who would have otherwise been treated with primary surgical bypass have instead undergone successful angioplasty and stenting. New technologies in combination with significant improvements to existing angiographic tools have made this shift possible.

There are certain categories of lower extremity arterial lesions in which it has become clear that a percutaneous approach should be the primary treatment modality. Infrainguinal lesions with areas of short occlusion or stenoses without occlusion should be managed percutaneously because these inherent lesion characteristics make crossing fairly straightforward. When lesion morphology worsens, however, as in

long chronic total occlusions (CTOs) or occlusions that involve the popliteal artery and proximal tibial vessels (TASC II C and D), crossing them becomes much more challenging. Certainly, there are advocates who would favor primary surgical intervention for these particular subsets of lower extremity arterial occlusive disease. One of the reasons for potential surgical bias is the difficulty in achieving technical success endovascularly, leading to persistently poor distal perfusion in patients who typically present with symptoms of critical limb ischemia and threatened limb loss. As crossing technology has advanced, I have found that even the most difficult TASC II C and D lesions can be managed endovascularly with good technical and clinical results.

To restore nutrient blood flow to a chronically ischemic limb, the first and essential step is to cross the blockages with a wire. As simple as this may sound, we know that this task represents the crux and essence of any successful endovascular lower extremity intervention. Depending on whom you ask, you will get varying responses on how to best address this issue, and undoubtedly, there is no single right answer. There are

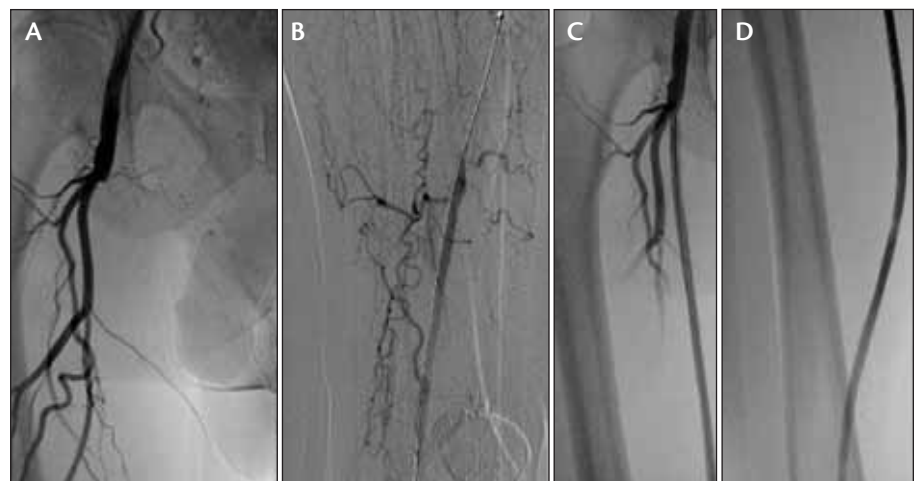


Figure 1. Flush occlusion of the SFA (A). Wire access established in reconstituted above-knee popliteal artery using 12-gram tip load Approach CTO wire (Cook Medical, Bloomington, IN) and laser atherectomy (B). Proximal SFA treated with angioplasty and stenting (C). Distal SFA treated with angioplasty and stenting (D).

many devices on the market, all in constant evolution and with particular subtleties and nuances in their use. Coupled with the unique behavioral response of each lesion, the idea of crossing lesions through a cookie cutter approach becomes simply impossible. Although countless methods surely exist, I offer some basic steps that I have relied on to treat difficult TASC II C and D lesions in patients with severe rest pain and tissue loss.

The foundation of successfully crossing a lesion centers on pushability. To have reliable pushability, there must be a strong supporting sheath when coming up and over the aortic bifurcation. A 45-cm 6-F Flexor sheath (Cook Medical) works well regardless of wire platform, and if using 0.014- or 0.018-inch systems, angiograms can easily be obtained without having to remove an indwelling balloon, which lessens the possibility of losing wire access and also saves time.

The sheath is placed as distally as possible without entering the potential treatment area. After sheath placement, the occlusion is engaged with a 0.035-inch CXI support catheter (Cook Medical) and a straight 0.035-inch HiWire (Cook Medical). The angled CXI catheter provides good directionality as well as fixed stability with wire manipulation, particularly for entering flush occlusions of the superficial femoral artery (SFA). The straight HiWire maintains true lumen access well and has good support for engaging a long-segment lesion.

As progress is made distally, the 0.035-inch wire platform is maintained until the HiWire can no longer be advanced without significant bowing. The angled CXI catheter is brought to this level of occlusion, and the HiWire is exchanged for a 0.014-inch Approach CTO wire with a 12-gram tip load. The weighted short-taper design transfers focused force to the end of the wire. If the wire bows or “Js” in this process, I typically do not try to advance it but instead switch to a different crossing modality because further attempts will likely enter a dissection plane.

The CXI catheter is exchanged for a 1.4-mm-diameter Turbo Elite laser catheter (Spectranetics Corporation, Colorado Springs, CO). The Approach CTO wire is wiped down meticulously before loading the laser catheter

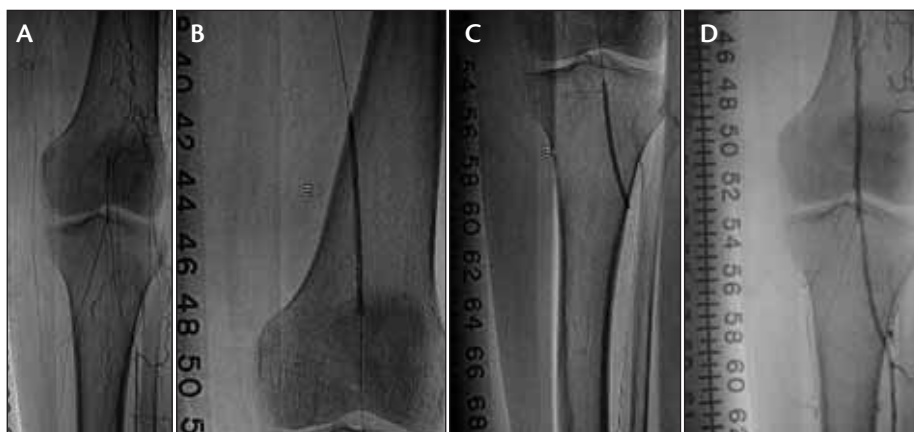

Figure 2. Occluded popliteal artery and proximal tibial vessels (A). Wire access established using 12-gram tip load Approach CTO wire and laser atherectomy. Balloon angioplasty of the popliteal artery and proximal anterior tibial artery performed using Advance 14LP balloons (B, C). Completion angiogram with one-vessel runoff through the anterior tibial artery (D).

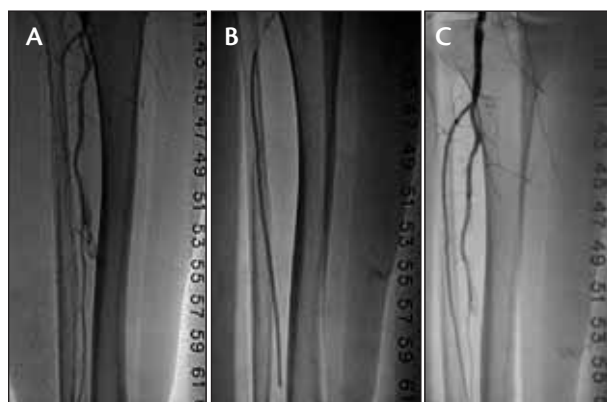

Figure 3. Occluded anterior tibial artery and diseased peroneal artery with arteriovenous fistula (A). Wire access established using 12-gram tip load Approach CTO wire followed by balloon angioplasty with an Advance 14LP balloon (B). Completion angiogram showing two-vessel runoff through the anterior tibial artery and peroneal artery with diminished arteriovenous fistula flow (C).

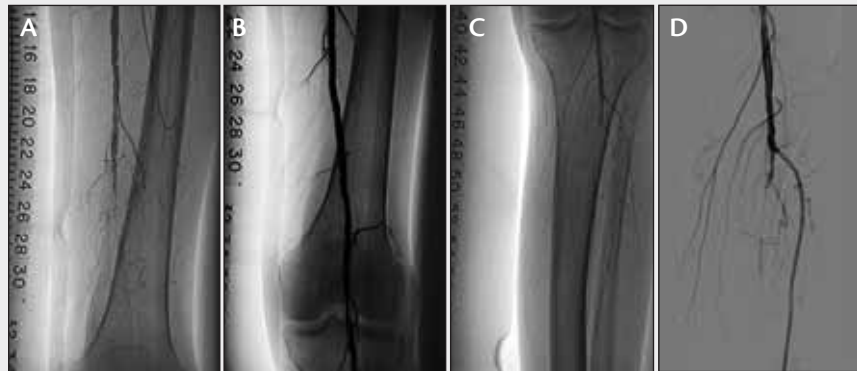because it is easy for the wire and catheter to stick together if bloody. Laser atherectomy is then performed in a stepwise fashion without wire support. Once the laser catheter begins advancing and manual resistance falls, the Approach CTO wire is reintroduced through the tip of the catheter and advanced until the next area of resistance is encountered.

If the Approach CTO wire does not cross this area easily without bowing, the laser catheter is advanced to this level, and repeat laser atherectomy is performed without wire access across the lesion. The laser catheter tracks well intraluminally, even through the bend at the

(Continued on page 35)

Case 1: Popliteal and Tibial Artery Occlusions

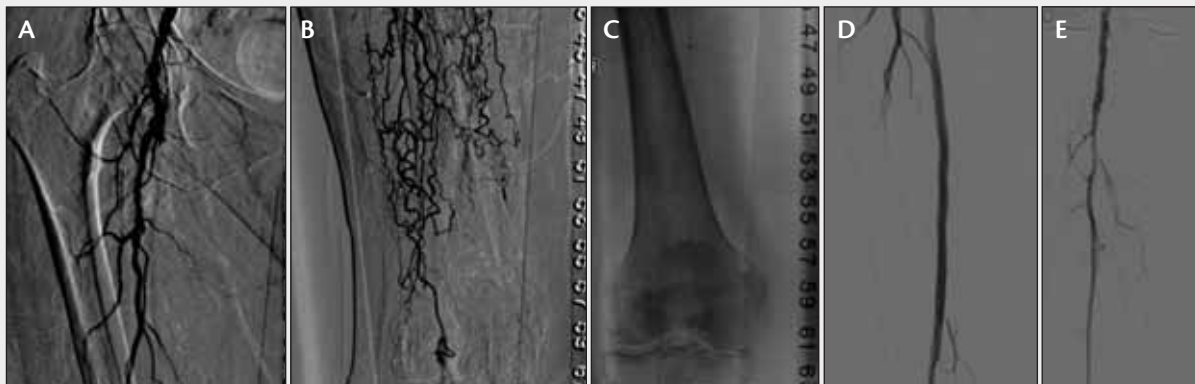A 70-year-old patient with severe rest pain and left foot ulcerations. The ankle-brachial index of the left lower extremity was 0.39 with a nonpalpable toe pressure. After the procedure, the patient had a palpable dorsalis pedis pulse and resolution of rest pain.



Case 1. Occluded distal SFA and above-knee popliteal artery (A). Distal SFA and popliteal artery crossed using a 0.035-inch CXI catheter and straight HiWire followed by a 12-gram tip load Approach CTO wire. Widely patent distal SFA and popliteal artery following angioplasty with 5- X 100-mm Advance 18LP balloon (B). Multilevel disease with occluded tibial vessels noted after SFA and popliteal intervention (C). ATA lesion crossed using Approach CTO wire and angioplasty performed with 2.5- X 200-mm Advance 14LP balloon (D).

Case 2: CTO of the SFA

An 87-year-old patient with severe rest pain. The patient had undergone angiography 5 years ago at another facility, and attempts at crossing the complete SFA occlusion were unsuccessful at that time. The ankle-brachial index of the right lower extremity was 0.44 before intervention. After the procedure, the ankle-brachial index improved to 0.9 and rest pain resolved.



Case 2. Occluded SFA just distal to its origin (A). Reconstitution of behind-knee popliteal artery through profunda femoris collaterals (B). Wire access through popliteal artery achieved using 12-gram tip load Approach CTO wire and laser atherectomy (C). SFA widely patent after angioplasty with a 6- X 100-mm 18LP balloon and stenting (D). One-vessel peroneal runoff (E).

The Next Frontier in Below-the-Knee Interventions

How long balloons may change our approach to treating BTK arterial occlusive disease.

BY NELSON L. BERNARDO, MD

Percutaneous endovascular intervention (PEI) for treating peripheral arterial disease (PAD) has greatly evolved in the past 2 decades. This is both in the acceptance of this treatment option as well as in the continued development of new devices and techniques to treat patients percutaneously. The efficacy and high success rate of PEI in the treatment of peripheral arterial occlusive disease coupled with the exponentially growing technological advances have inevitably enabled practitioners to tackle more complex lesions. This is also true for the treatment and recanalization of below-the-knee (BTK) arterial occlusive disease. The early years of infrapopliteal/BTK percutaneous interventions evolved around making use of coronary equipment (ie, guidewires and balloon catheters) and using them when treating tibial and peroneal stenoses. In general, 0.014-inch coronary systems have been well suited for BTK intervention in view of the comparable luminal size of both arterial systems. Success in applying PEI in the treatment of BTK disease, specifically in the subset of patients with critical limb ischemia (CLI), has seen the increase in the number of BTK interventional procedures.^{1,2} Notwithstanding the clinical need, industry has responded by investing significant resources in the development of catheters, wires, balloons, and devices specifically designed for use in infrapopliteal interventions.

As with all percutaneous interventions, either coronary or peripheral endovascular therapy, using the right tool is key to the success of the procedure. This article focuses on a new family of long balloons and their use in BTK interventional procedures, with the term *long*

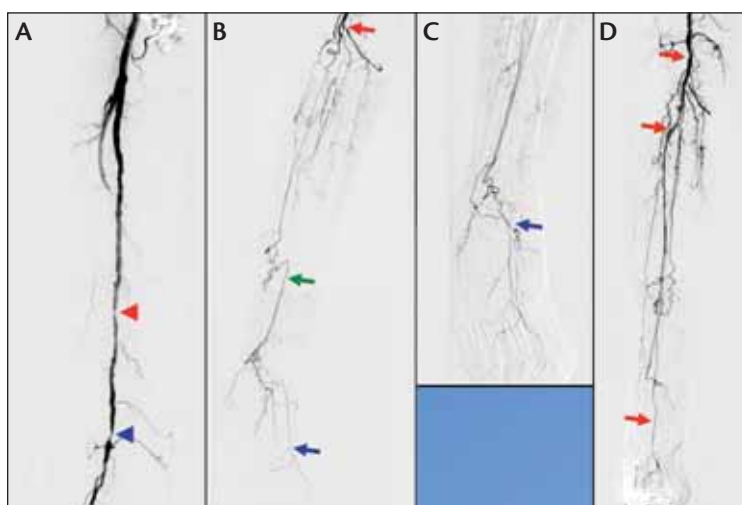


Figure 1. Baseline angiogram of the right superficial femoral artery (SFA), right deep femoral artery, and proximal segment of the right popliteal artery. The red and blue arrowheads point to the mid and distal right SFA stenotic lesions, respectively (A). Angiogram of the right infrapopliteal arterial system. The red arrow indicates the stump of the totally occluded mid-right popliteal artery. The green arrow points to the reconstituted distal right posterior tibial artery segment, and the blue arrow points to the right dorsalis pedis artery (B). Angiogram of the right foot. The blue arrow points to the looped distal end of a 0.018-inch Glidewire (Terumo Interventional Systems, Somerset, NJ) entering the right dorsalis pedis artery (C). Angiogram of the right lower extremity after balloon angioplasty showing successful percutaneous endovascular intervention/recanalization of the totally occluded right anterior tibial (AT) artery. The red arrows indicate the track of the pulsatile straight-in-line flow from the patent right SFA, through the right popliteal artery and right AT artery (one-vessel runoff) (D).

referring to the long balloon length that is inflated to dilate the stenotic segment as well as the innovative long shaft of this new balloon catheter (Advance 14LP low-profile PTA balloon dilatation catheter [Cook Medical, Bloomington, IN]), which determines the farthest distance of the stenotic lesion that can be treated as measured from the vascular access site.

CASE STUDY

The patient is a 77-year-old woman with hypertension, diabetes mellitus, hyperlipidemia, and PAD. She presented with lifestyle-limiting right lower extremity intermittent claudication after walking less than 50 yards. She was a nonsmoker and was also being evaluated for right knee surgery and replacement. Ankle-brachial index on the right leg was 0.5 and 0.8 on the left leg. There was no recent history for nonhealing ulcer or wound or of rest pain. An arterial duplex scan showed bilateral SFA occlusive disease and significant BTK arterial occlusive disease.

Right lower extremity angiography from the contralateral left common femoral artery access site showed high-grade right SFA mid and distal segment stenotic lesions and a totally occluded right popliteal artery. Bridging collaterals reconstitute the right posterior tibial artery and delayed filling of the right dorsalis pedis artery (Figure 1A and 1B).

A 5-F 90-cm Shuttle sheath (Cook Medical) was inserted through the left femoral artery and crossed over into the right iliofemoral artery system. The tip of the sheath was initially positioned in the proximal segment of the right SFA. After successfully advancing a 0.014-inch Hi-Torque Whisper ES 300-cm guidewire (Abbott Vascular, Santa Clara, CA) across the SFA lesions, scoring balloon angioplasty (5- X 40-mm AngioSculpt scoring balloon catheter [AngioScore, Inc., Fremont, CA]) was performed with excellent angiographic results. The Cook Shuttle sheath was then advanced fully into the distal segment of the right SFA. A 0.018-inch Glidewire (Terumo Interventional Systems) loaded in a CXI 0.018-inch, 150-cm-length support catheter (Cook Medical) was successfully advanced across the occluded distal right popliteal artery, the occluded right tibioperoneal trunk, and through the totally occluded right AT artery into the distal right dorsalis pedis artery (Figure 1C).

With the Cook CXI support catheter barely reaching the ankle area, the 0.018-inch Glidewire was exchanged out for the 0.014-inch Whisper guidewire. Balloon angioplasty was then performed to dilate the long occluded segments. An Advance 14LP 0.014-inch, 2- X 200-mm

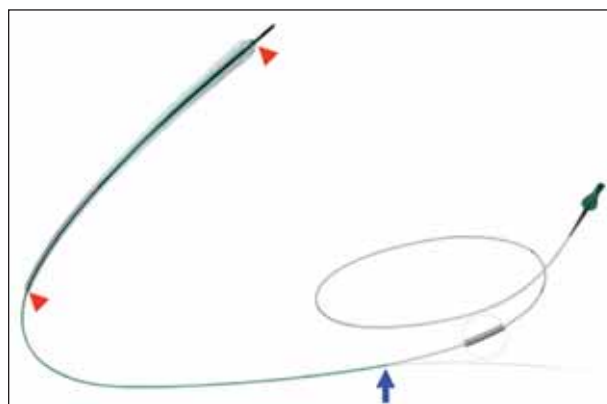


Figure 2. Cook Advance 14LP low-profile PTA balloon catheter. The red arrowheads indicate the proximal and distal edges of the balloon and signify the length of the balloon that is inflated. Balloon sizes range from 20- to 200-mm long and in 2-, 2.5-, 3-, and 4-mm diameters. The blue arrow indicates the proximal exit side port of the monorail guidewire lumen.

balloon catheter (Cook Medical) was used to dilate the occluded distal right AT segment. An Amphirion Deep 2.5- to 3- X 210-mm PTA conical balloon catheter (Medtronic Invatec, Frauenfeld, Switzerland) was used to dilate the mid-right AT segment and proximally into the right tibioperoneal trunk. The latter was further dilated using a Fox sv 4- X 80-mm PTA catheter (Abbott Vascular). The final angiogram shows excellent dilatation of the stenotic segments with no significant residual stenosis and TIMI 3 flow to the distal vessels. There was pulsatile straight-in-line flow from the patent right SFA, through the right popliteal artery and the one-vessel runoff to the periphery (ie, right AT artery) (Figure 1D). The patient was discharged home the following morning much improved.

DISCUSSION

The case study clearly illustrates one of the technical limitations encountered in the PEI of BTK disease. The patient is tall, as evidenced by the 90-cm Cook Shuttle sheath reaching only the distal segment of the SFA. This is further substantiated by the fact that the 150-cm-long Cook CXI support catheter barely reached the ankle area. The Cook Advance 14LP low-profile balloon catheter was chosen to dilate the occluded distal right AT artery segment, because this 0.014-inch wire-based balloon currently is the only balloon catheter in the United States with the longest catheter shaft length of 170 cm. This ensured the advancement of the balloon catheter into the dorsalis pedis artery to treat the distal end of the occluded right AT artery. Using the contralateral up-and-over approach in infrapopliteal interventions, the physician is besieged by the possibility that this may limit the

LIMITATIONS TO THE ANTEGRADE STICK APPROACH FOR BTK INTERVENTION

- Obese patients
- High bifurcation of the SFA and deep femoral artery from the common femoral artery
- Diseased or occluded proximal segment of the SFA precluding an adequate landing zone for sheath placement

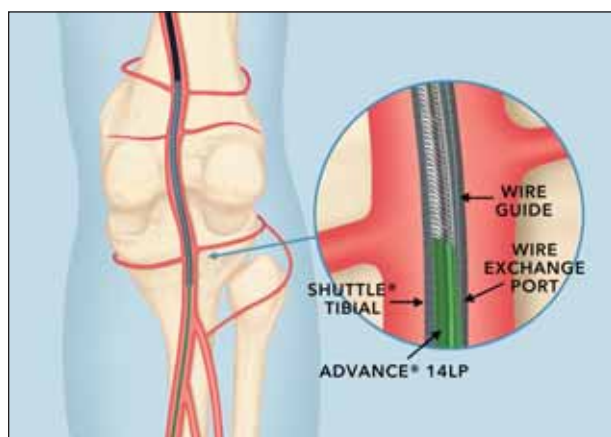


Figure 3. Cook Advance 14LP low-profile PTA balloon catheter advanced through a sheath positioned in the right popliteal artery. The segment of the balloon catheter outside the sheath is over the wire, and the rapid-exchange monorail system is confined within the sheath.

working length of guidewires, balloon catheters, and devices to treat a distal BTK lesion, especially in tall patients. An alternative is to gain vascular access using the antegrade approach.³ This, however, would entail the need to manage and achieve hemostasis of another access site, and the antegrade approach itself has its own limitations (see *Limitations to the Antegrade Stick Approach for BTK Intervention* sidebar).

The Cook Advance 14LP low-profile PTA balloon catheter is a single- to double-lumen catheter with a balloon near its distal tip. The proximal part of the catheter consists of one lumen attached to a luer lock. The distal part of the balloon catheter consists of two independent lumens; one of these two, the proximal lumen, extends the length of the catheter and is used to inflate the balloon. The distal lumen extends from the catheter tip to a point approximately 50 cm proximal to the balloon and

is used for placement of the guidewire (Figure 2). The well-thought design of the Advance 14LP balloon catheter using the rapid-exchange monorail system takes advantage of the short guidewire length needed to advance the device to the lesion. This voided the current limitation of a working balloon shaft length of 150 cm because currently available guidewires are 300 cm in length. The proximal exit side port of the guidewire lumen is positioned way back, ensuring that the monorail system is confined within the sheath when used as previously described (Figure 3).

The coiled-wire shaft construction of the balloon catheter provides the pushability to track the balloon to its destination. The flexibility and kink resistance of the shaft affords the operator the additional push needed as the interventionist advances the balloon catheter through the crossover sheath from a contralateral access across a hostile aortic arch and the tortuous vasculature of the lower leg. The balloon catheter has a low crossing profile, and it can be advanced through 4-F sheaths. The added hydrophilic coating on the balloon and on the distal shaft segment, along with a smooth tip transition, improves the ability of the balloon catheter to cross through a tight stenosis and long occluded segment.

Lastly, the long balloon lengths allow treating long lesions or occlusions with fewer balloon inflations and deflations. This certainly allows long inflation times to treat lesions with much-improved angiographic results.⁴ The need to inflate the 200-mm-long balloon catheter twice to treat the entire length of a BTK artery also results in a shortened total procedure time. More importantly, the latter translates to a lesser radiation exposure time for both the patient and the treating staff (see *Advantages of Long Balloons* sidebar).

The application and acceptance of PEI in treating BTK disease, especially in CLI, is gaining a lot of ground. The increasing patient population due to an increasing prevalence of diabetes mellitus and the increased awareness of the disease entity has contributed to this. More importantly, the recognition of the utility and success of PEI in limb salvage or limb preservation also played a major factor. Notwithstanding the limited application of surgical revascularization in CLI, the excellent acute technical success rates of PEI of above 90%, low complication rate, and a high limb-salvage rate of approximately 95% justify a more widespread use of endovascular therapy in infrapopliteal arteries.^{1,5}

The primary goal of PEI in CLI is the re-establishment of pulsatile, straight-in-line flow to the foot. Successful recanalization typically results in relieving ischemic pain, healing of ulcers, preventing limb loss, and improving quality of life. Even though the current results of BTK balloon angioplasty studies show a 1-year restenosis rate

ADVANTAGES OF LONG BALLOONS

- Long balloon:
 - Treats long lesions with fewer inflations and deflations
 - Allows long inflation time and improved angiographic results
 - Shortened procedure time
 - Lessens radiation exposure time
- Long-shaft catheter:
 - Allows treatment of distal BTK lesions from a contralateral access site
 - The monorail-guidewire system allows the treatment of lesions with a distance > 150 cm from the access site

between 30% for short stenoses treatment and up to 80% after recanalization of a long total occlusion,¹ the outcomes measured of clinical relevance are the limb salvage or limb preservation rates and not the vessel patency rate. Moreover, PEI can be readily repeated to sustain wound healing.

The exponential growth in the number of device options (ie, balloons, catheters, stents, adjunctive debulking devices, re-entry devices, etc.) that are available for PEI has been much appreciated by interventionists. These certainly have improved the acute outcome of the interventional procedure but do not equate to better long-term patency rates. Novel devices such as excimer laser atherectomy, excisional and rotational atherectomy systems, drug-eluting stents, or drug-coated balloons still lack data demonstrating improved efficacy compared to conventional balloon angioplasty.

CONCLUSION

Balloon angioplasty with provisional bailout stent implantation is currently the accepted treatment for BTK arterial occlusive disease, including patients with CLI. Success of the interventional procedure, however, is dependent on the successful delivery of the device (eg, balloon catheter) to the target lesion. The introduction of the Cook Advance 14LP low-profile PTA balloon catheter has been much welcomed. The 170-cm-long

shaft of the balloon catheter allowed the treatment of a very distal BTK lesion (ie, dorsalis pedis artery, using the contralateral up-and-over access approach in a tall patient). The long balloon of up to 200 mm in length allows the treatment of long lesions with fewer balloon inflations and deflations but with longer inflation times. Prolonged balloon inflation affords improved angiographic results, shortened total procedure time, and reduced radiation exposure for both the patient and the operator(s). ■

Nelson L. Bernardo, MD, is Director for Peripheral Intervention with the Division of Cardiology at the Washington Hospital Center in Washington, DC. He has disclosed that he holds no financial interest in any product or manufacturer mentioned herein. Dr. Bernardo may be reached at (202) 877-5975; nelson.l.bernardo@medstar.net.

1. Schwarzwald U, Zeller T. Below-the-knee revascularization. Advanced techniques. *Cardiovasc Surg (Torino)*. 2009;50:627-634.
2. Jämsén T, Manninen H, Tulla H, et al. The final outcome of primary infrainguinal percutaneous transluminal angioplasty in 100 consecutive patients with chronic critical limb ischemia. *J Vasc Interv Radiol*. 2002;13:455-463.
3. Nice C, Timmons G, Bartholemew P, et al. Retrograde vs. antegrade puncture for infrainguinal angioplasty. *Cardiovasc Intervent Radiol*. 2003;26:370-374.
4. Zorger N, Manke C, Lenhart M, et al. Peripheral arterial balloon angioplasty: effect of short versus long balloon inflation times on the morphologic results. *J Vasc Interv Radiol*. 2002;13:355-359.
5. Balzer JO, Khan V, Thalhammer A, et al. Below the knee PTA in critical limb ischemia results after 12 months: single center experience. *Eur J Radiol*. 2010;75:37-42.

(Continued from page 30)

adductor hiatus. I have not had a perforation using this technique. Once wire access is obtained in a patent area of the distal popliteal artery or tibial vessel, balloon angioplasty of the SFA and popliteal artery are performed (Figure 1).

An Advance 18LP balloon (Cook Medical), which has good pushability and maintains a low profile over the 0.014-inch wire, is brought into the SFA for this purpose. Quick deflation of the Advance 18LP balloon enables rapid treatment of the entire SFA if necessary. Any areas of previous total occlusion or dissection after angioplasty are then stented.

Multilevel disease is often encountered in these patients with critical limb ischemia, and having now treated the femoropopliteal segment, focus shifts to the infrapopliteal tibial vessels. The CXI catheter is reintroduced into the popliteal artery and is used to redirect the weighted Approach CTO wire. The Approach CTO wire with the 12-gram tip load is selected initially because it delivers firm pressure while also providing good manual sensitivity. If the 12-gram wire is unable to cross a tibial occlusion, I switch to an

18-gram wire, which offers even greater force transmission in straight segments of the tibial vessels. If the dominant runoff vessel is the anterior tibial artery (ATA), the CXI catheter has good transference of torque to easily engage a heavily diseased ATA origin, and a gentle curve can be applied to the tip of the 12-gram Approach CTO wire to cross an occluded proximal ATA beyond the origin. Once wire access is obtained across areas of tibial occlusion, angioplasty with rapid-exchange Advance 14LP balloons is performed (Figure 2).

In this fashion, recanalized total occlusions of the tibial system can be effectively treated even with a single balloon because the longer low-profile Advance 14LP allows for smooth primary crossing of extensive lesions and fewer balloon inflations (Figure 3). ■

Richard Pin, MD, is a vascular and endovascular surgeon with Grant Medical Center in Columbus, Ohio. He has disclosed that he holds no financial interest in any product or manufacturer mentioned herein. Dr. Pin may be reached at rpin2@ohiohealth.com.