

Effects of Hypovolemia on Aortic Dimensions

Implications for endovascular repair of thoracic aortic rupture.

BY FREDERIK H.W. JONKER, MD; FELIX J.V. SCHLÖSSER, MD, PhD; FRANS L. MOLL, MD, PhD;
HENCE J.M. VERHAGEN, MD, PhD; AND BART E. MUHS, MD, PhD

A ruptured thoracic aorta is a rare but life-threatening condition requiring immediate intervention. Possible causes of a ruptured thoracic aorta are ruptured descending thoracic aneurysms, acute type B aortic dissections, penetrating aortic ulcers, and traumatic thoracic aortic injuries (TTAI). Thoracic endovascular aortic repair (TEVAR) offers an effective treatment for these acute thoracic aortic pathologies, and the endovascular approach appears to reduce the morbidity and mortality rates compared with traditional open surgery.¹⁻⁹ At many institutions, TEVAR has become the preferred treatment for acute thoracic aortic disease.^{2,5,9,10}

However, endovascular repair of these acute aortic pathologies is still associated with the occurrence of endoleak in 5% to 30% of cases.^{2,3,6,8,9,11} The majority of these endoleaks are proximal type I endoleaks, and urgent reintervention is often needed.^{3,11} Adequate endograft sizing using preoperative computed tomography angiography (CTA) is thought to be important in minimizing risks of endoleak and other endograft-related complications and for improving long-term outcomes after endovascular repair.

Patients with thoracic aortic rupture are often admitted with considerable blood loss or hypovolemic shock. Although peripheral vasoconstriction

is a well-known response to hypovolemic shock to maintain perfusion of the heart and brain,¹²⁻¹⁴ the effects of hypovolemia on the aortic dimensions remain unclear. Temporary changes in the aortic diameter during blood loss could lead to incorrect aortic measurements on preoperative CTA, inadequate endograft sizing, and increased risks of endograft-related complications after TEVAR for thoracic aortic emergencies.

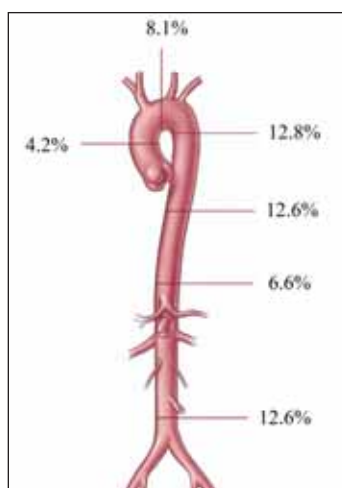


Figure 1. A decrease in mean aortic diameters in trauma patients admitted with a heart rate \geq 130 bpm and a MAP $<$ 95 mm Hg. Reprinted from the *Journal of Vascular Surgery*, 52(1), Jonker FH et al. Aortic endograft sizing in trauma patients with hemodynamic instability, 39–44, Copyright (2010), with permission from Elsevier.¹⁵

EFFECTS OF HYPOVOLEMIA ON AORTIC DIMENSIONS

We performed several research projects to study the effects of hypovolemia on the aortic dimensions and the potential implications for the endovascular management of thoracic aortic rupture. In the first project, we retrospectively investigated aortic changes in trauma patients who were admitted with hemodynamic instability (mean arterial pressure [MAP] $<$ 95 mm Hg and a heart rate $>$ 100 bpm).¹⁵ All trauma patients with these vital signs who had undergone a CT of the thorax and abdomen both at admission and at another time (control CT scan) were included for analysis. All CT examinations were blinded, and differences in aortic diameter between the initial CT scans obtained in the trauma bay and the control CTs were compared. This comparison revealed that these trauma patients had significantly smaller aortic diameters at

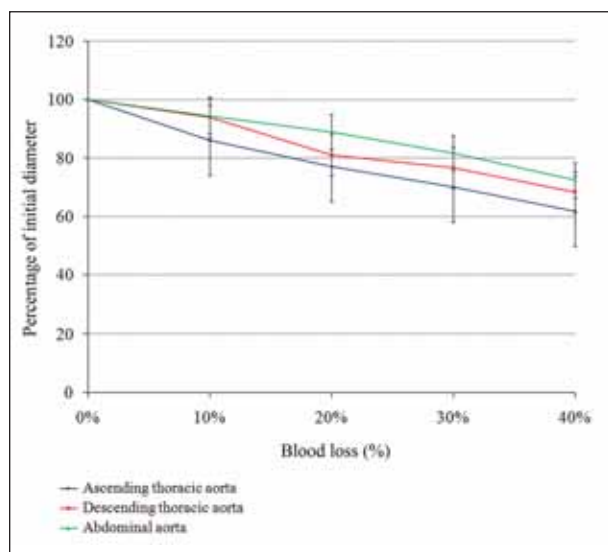


Figure 2. Mean aortic diameter during blood loss in an experimental porcine model. Error bars represent the 95% confidence interval of the mean. Reprinted from the *European Journal of Vascular and Endovascular Surgery*, 40(5), Jonker FH et al. The impact of hypovolaemic shock on the aortic diameter in a porcine model, 564–571, Copyright (2010), with permission from Elsevier.¹⁶

admission when they were hemodynamically unstable, compared with the control CT scans.¹⁵ The decrease in aortic diameter was observed at all evaluated levels, and the inferior vena cava was also significantly smaller at admission compared with the control CT. A subanalysis of the patients who had more severe hemodynamic instability (a heart rate ≥ 130 bpm) showed that the mean difference in aortic diameter between the two different scans was even larger. At the level of the mid-descending thoracic aorta and the abdominal aorta, the aortic diameter was on average 13% smaller at admission when hemodynamically unstable compared with the control CT scans (Figure 1).¹⁵ Our hypothesis for these remarkable findings was that the decreased pressure on the aortic wall due to hypovolemic shock and endogenous production of vasoconstrictors may have caused the decrease in aortic diameter in these trauma patients.

Because this retrospective study had several limitations, we also performed several pig experiments to further investigate the exact effects of blood loss on the aortic dimensions.¹⁶ The circulating blood volume of seven Yorkshire pigs was gradually lowered in 10% increments. At 40% blood loss, an endograft was deployed in the descending thoracic aorta followed by gradual fluid resuscitation. Potential changes in aortic

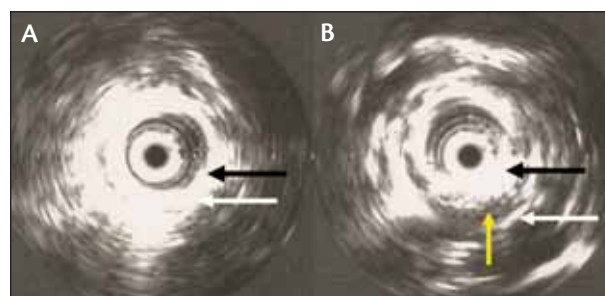


Figure 3. IVUS images of an endoleak after complete resuscitation in an experimental porcine model. The descending thoracic aortic diameter of this Yorkshire pig decreased from 15.5 to 7.4 mm (52.3%) after 40% blood loss, and a 12-mm stent graft was deployed (62% oversizing; black arrow: stent graft; white arrow: aortic wall) (A). The same Yorkshire pig after complete fluid resuscitation; a large endoleak (yellow arrow) is visible between the stent graft (black arrow) and the aortic wall (white arrow) (B). The leakage was already detected after 20% fluid resuscitation and further increased during continued resuscitation. Reprinted from the *European Journal of Vascular and Endovascular Surgery*, 40(5), Jonker FH et al. The impact of hypovolaemic shock on the aortic diameter in a porcine model, 564–571, Copyright (2010), with permission from Elsevier.¹⁶

diameter during the experiment were recorded using intravascular ultrasound (IVUS). We observed that during blood loss, the aortic diameter gradually decreased in all subjects at the level of the ascending, descending, and abdominal aorta (Figure 2). The ascending aortic diameter decreased on average by 38% after 40% blood loss (range, 24%–62%), the descending thoracic aorta by 32% (range, 18%–52%), and the abdominal aorta by 28% (range, 15%–39%).¹⁶ Linear regressions analysis showed that the degree of blood loss was highly correlated with the descending thoracic aortic diameter. There was also a strong correlation between the blood pressure during the experiment and the aortic diameter in the Yorkshire pig, whereas the heart rate was less reliable for predicting the aortic diameter. Once the animals received fluid resuscitation, the aortic diameters quickly regained their initial size. Two of the seven Yorkshire pigs developed endoleaks during fluid resuscitation, whereas no abnormalities were observed after initial endograft deployment at 40% blood loss (Figure 3).¹⁶

Theoretically, these aortic changes could take place in all patients with considerable blood loss, but we expect that these changes will be most extreme in young TTAI patients. Because aortic compliance decreases with age^{17,18} due to a loss of elasticity and increased preva-

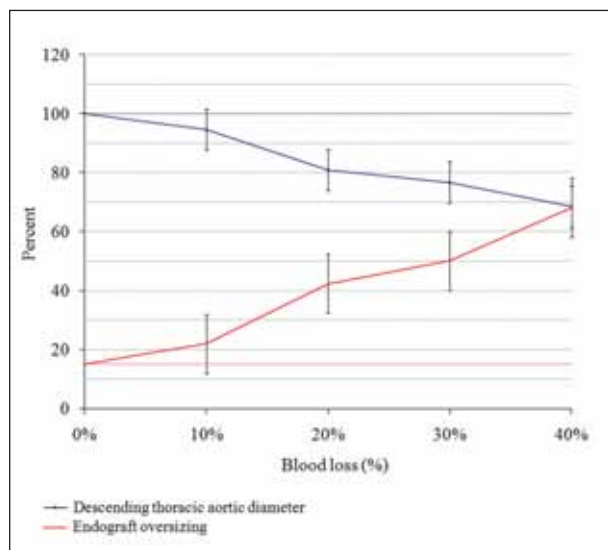


Figure 4. Theoretic percentage of oversizing required during TEVAR based on findings in a porcine model. The red line represents the theoretic percentage of oversizing of the aortic diameter to obtain a 15% oversizing of the normal aortic diameter, which is recommended by most endograft manufacturers. Error bars represent the 95% confidence interval of the mean. Reprinted from the *European Journal of Vascular and Endovascular Surgery*, 40(5), Jonker FH et al. The impact of hypovolaemic shock on the aortic diameter in a porcine model, 564–571, Copyright (2010), with permission from Elsevier.¹⁶

lence of aortic calcification,^{19–21} we believe that aortic changes may be less dramatic in patients with ruptured aortic aneurysms who are typically much older than the average trauma patient. The aortic changes during blood loss and fluid resuscitation may have implications for the endovascular management of thoracic aortic rupture.

IMPLICATIONS FOR TEVAR OF THORACIC AORTIC RUPTURE

Endograft sizing for TEVAR is usually performed using the preoperative CTA scan; however, if the diameter of the descending thoracic aorta is considerably smaller at admission due to blood loss, physicians may undersize the endograft. This mismatch between the aortic diameter and the endograft could theoretically result in increased risks of endoleak or other endograft-related complications such as endograft migration after TEVAR. Physicians performing TEVAR should be aware that changes in aortic diameter due to hypovolemia could take place, and there may be two options to adjust for this phenomenon.

First, because the actual aortic diameter measurements may be larger than observed on preoperative CTA, physicians could consider slightly increasing the percentage of oversizing for the endograft (Figure 4). Because of the many variables that may affect the aortic dimensions, it is difficult to provide a recommendation with regard to the exact percentage of oversizing needed in hypovolemic patients. Based on the finding that the mid-descending thoracic aorta of trauma patients with a pulse > 130 bpm and a MAP < 95 mm Hg was on average 13% smaller on the CT at admission, physicians could consider applying approximately 20% to 30% oversizing in TTAI patients with similar vital signs, instead of the standard 10% to 20% oversizing. Caution is needed when increasing the percentage of oversizing during TEVAR because some reports suggest that this may increase the risk of endograft collapse, an uncommon but serious complication of TEVAR.^{22–24}

“This mismatch between the aortic diameter and the endograft could theoretically result in increased risks of endoleak or other endograft-related complications . . .”

An alternative to increasing the percentage of oversizing could be performing additional imaging after fluid resuscitation for more adequate aortic measurements. Several recent studies have suggested that delaying TEVAR for patients with TTAI improves survival,^{25–28} and this approach may also be beneficial for correct endograft sizing. Additional aortic imaging could be performed using either a second CT scan or using IVUS during the endovascular procedure. IVUS offers the benefit of real-time sizing during the endovascular procedure when the patient may be better resuscitated than during the CT scan at admission. Therefore, the aortic measurements on IVUS during endovascular repair may be more reliable, and regular use of IVUS during TEVAR of TTAI may be recommended. However, the strategy to delay the endovascular procedure could be lethal in hypovolemic patients with active bleeding. Some studies suggest that fluid resuscitation should be limited in patients with hemorrhagic shock due to trauma or ruptured aneurysm because fluid restriction may limit internal bleeding and its associated loss of platelets and clotting factors.^{29–32}

Further research is warranted to better understand the aortic dynamics during hypovolemia to more accurately predict the normal aortic measurements in hypovolemic patients requiring TEVAR. A better understanding of the

aortic dynamics may eventually result in a reduction of endograft-related complications and further improvements of the prognosis of patients with thoracic aortic rupture.

CONCLUSIONS

Endovascular repair is emerging as the preferred treatment for patients with thoracic aortic rupture. Hypovolemic shock could result in decreased aortic dimensions, which could lead to undersizing of the endograft and an increased risk of endoleak during TEVAR. Therefore, increased oversizing of the endograft or additional aortic imaging after fluid resuscitation may be required in hypovolemic patients with thoracic aortic rupture. ■

Frederik H.W. Jonker, MD, is with the Section of Vascular Surgery and Interventional Radiology, Yale University School of Medicine in New Haven, Connecticut. He has disclosed that he holds no financial interest in any product or manufacturer mentioned herein. Dr. Jonker may be reached at frederik.jonker@yale.edu.

Felix J.V. Schlösser, MD, PhD, is with the Section of Vascular Surgery and Interventional Radiology, Yale University School of Medicine in New Haven, Connecticut. He has disclosed that he holds no financial interest in any product or manufacturer mentioned herein.

Frans L. Moll, MD, PhD, is with the Section of Vascular Surgery, University Medical Center in Utrecht, The Netherlands. He has disclosed that he is a paid consultant to Medtronic, Inc. and Nellix, Inc.

Hence J.M. Verhagen, MD, PhD, is with the Section of Vascular Surgery, Erasmus University Medical Center in Rotterdam, The Netherlands. He has disclosed that he is a paid consultant to Medtronic, Inc. and W. L. Gore & Associates, and receives grant/research funding from Medtronic, Inc.

Bart E. Muhs, MD, PhD, is with the Section of Vascular Surgery and Interventional Radiology, Yale University School of Medicine in New Haven, Connecticut. He has disclosed that he is a shareholder in and receives grant/research funding from Volcano Corporation. Dr. Muhs may be reached at (203) 785-2564; bart.muhs@yale.edu.

1. Tang GL, Tehrani HY, Usman A, et al. Reduced mortality, paraplegia, and stroke with stent graft repair of blunt aortic transections: a modern meta-analysis. *J Vasc Surg.* 2008;47:671-675.
2. Jonker FH, Giacomelli JK, Muhs BE, et al. Trends and outcomes of endovascular and open treatment for traumatic thoracic aortic injury. *J Vasc Surg.* 2010;51:565-571.
3. Demetriades D, Velmahos GC, Scalia TM, et al. Operative repair or endovascular stent graft in blunt traumatic thoracic aortic injuries: results of an American Association for the Surgery of Trauma Multicenter Study. *J Trauma.* 2008;64:561-570.
4. Jonker FH, Trimarchi S, Verhagen HJ, et al. Meta-analysis of open versus endovascular

- repair for ruptured descending thoracic aortic aneurysm. *J Vasc Surg.* 2010;51:1026-1032.
5. Patel HJ, Williams DM, Upchurch GR Jr, et al. A comparative analysis of open and endovascular repair for the ruptured descending thoracic aorta. *J Vasc Surg.* 2009;50:1265-1270.
6. Jonker FH, Verhagen HJ, Lin PH, et al. Outcomes of endovascular repair of ruptured descending thoracic aortic aneurysms. *Circulation.* 2010;121:2718-2723.
7. Fattori R, Tsai TT, Myrmet T, et al. Complicated acute type B dissection: is surgery still the best option? A report from the International Registry of Acute Aortic Dissection. *JACC: Cardiovasc Interv.* 2008;1:395-402.
8. Mastroroberto P, Onorati F, Zofrea S, et al. Outcome of open and endovascular repair in acute type B aortic dissection: a retrospective and observational study. *J Cardiothorac Surg.* 2010;5:23.
9. Cambria RP, Crawford RS, Cho JS, et al. A multicenter clinical trial of endovascular stent graft repair of acute catastrophes of the descending thoracic aorta. *J Vasc Surg.* 2009;50:1255-1264.
10. Demetriades D, Velmahos GC, Scalea TM, et al. Diagnosis and treatment of blunt thoracic aortic injuries: changing perspectives. *J Trauma.* 2008;64:1415-1418.
11. Neschis DG, Moainie S, Flinn WR, et al. Endograft repair of traumatic aortic injury—a technique in evolution: a single institution's experience. *Ann Surg.* 2009;250:377-382.
12. Wiggers HC, Ingraham RC. Vasoconstriction and the development of irreversible hemorrhagic shock. *Am J Physiol.* 1948;153:511-520.
13. Cohn JN, Luria MH. Studies in clinical shock and hypotension. IV. Variations in reflex vasoconstriction and cardiac stimulation. *Circulation.* 1966;34:823-832.
14. Peitzman AB, Billiar TR, Harbrecht BG, et al. Hemorrhagic shock. *Curr Probl Surg.* 1995;32:925-1002.
15. Jonker FH, Verhagen HJ, Mojibian H, et al. Aortic endograft sizing in trauma patients with hemodynamic instability. *J Vasc Surg.* 2010;52:39-44.
16. Jonker FH, Mojibian H, Schlosser FJ, et al. The impact of hypovolaemic shock on the aortic diameter in a porcine model. *Eur J Vasc Endovasc Surg.* 2010;40:564-571.
17. Mohiaddin RH, Underwood SR, Bogren HG, et al. Regional aortic compliance studied by magnetic resonance imaging: the effects of age, training, and coronary artery disease. *Br Heart J.* 1989;62:90-96.
18. Sonesson B, Hansen F, Stale H, Lanne T. Compliance and diameter in the human abdominal aorta: the influence of age and sex. *Eur J Vasc Surg.* 1993;7:690-697.
19. Mohiaddin RH, Schoser K, Amanuma M, et al. MR imaging of age-related dimensional changes of thoracic aorta. *J Comput Assist Tomogr.* 1990;14:748-752.
20. Bazan HA, Pradhan S, Mojibian H, et al. Increased aortic arch calcification in patients older than 75 years: implications for carotid artery stenting in elderly patients. *J Vasc Surg.* 2007;46:841-845.
21. Takeda S, Watanabe H, Matsuzawa T. Age-related change in calcifications in the thoracic aorta: a study with computed tomography. *Tohoku J Exp Med.* 1986;149:73-78.
22. Muhs BE, Balm R, White GH, Verhagen HJ. Anatomic factors associated with acute endograft collapse after Gore TAG treatment of thoracic aortic dissection or traumatic rupture. *J Vasc Surg.* 2007;45:655-661.
23. Sze DY, Mitchell RS, Miller DC, et al. Infolding and collapse of thoracic endoprostheses: manifestations and treatment options. *J Thorac Cardiovasc Surg.* 2009;138:324-333.
24. Bandorski D, Bruck M, Gunther HU, Manke C. Endograft collapse after endovascular treatment for thoracic aortic disease. *Cardiovasc Intervent Radiol.* 2010;33:492-497.
25. Demetriades D, Velmahos GC, Scalea TM, et al. Blunt traumatic thoracic aortic injuries: early or delayed repair—results of an American Association for the Surgery of Trauma prospective study. *J Trauma.* 2009;66:967-973.
26. Symbas PN, Sherman AJ, Silver JM, et al. Traumatic rupture of the aorta: immediate or delayed repair? *Ann Surg.* 2002;235:796-802.
27. Hemmila MR, Arbabi S, Rowe SA, et al. Delayed repair for blunt thoracic aortic injury: is it really equivalent to early repair? *J Trauma.* 2004;56:13-23.
28. Pate JW, Fabian TC, Walker W. Traumatic rupture of the aortic isthmus: an emergency? *World J Surg.* 1995;19:119-125.
29. Veith FJ, Lachat M, Mayer D, et al. Collected world and single center experience with endovascular treatment of ruptured abdominal aortic aneurysms. *Ann Surg.* 2009;250:818-824.
30. Bickell WH, Wall MJ Jr, Pepe PE, et al. Immediate versus delayed fluid resuscitation for hypotensive patients with penetrating torso injuries. *N Engl J Med.* 1994;331:1105-1109.
31. Roberts K, Revell M, Youssef H, et al. Hypotensive resuscitation in patients with ruptured abdominal aortic aneurysm. *Eur J Vasc Endovasc Surg.* 2006;31:339-344.
32. van der Vliet J, van Aalst DL, Schultze Kool LJ, et al. Hypotensive hemostasis (permissive hypotension) for ruptured abdominal aortic aneurysm: are we really in control? *Vascular.* 2007;15:197-200.