

Enhancing Carotid Endarterectomy

Like its interventional counterpart, open surgical carotid revascularization has also seen technical improvements, including the mini-incision Jikei method.

BY TAKAO OHKI, MD, PhD

Carotid endarterectomy (CEA) has been scrutinized by nonvascular surgeons for decades. As a result, CEA has been involved in a large number of randomized controlled trials comparing it to a variety of therapeutic options. Compared to other surgical procedures, CEA's involvement in so many randomized trials has made it something of an iconic presence in evidence-based medicine.¹⁻⁴ In addition to medical therapies, CEA has been compared head to head with carotid artery stenting (CAS) and has never been defeated outright.⁵⁻⁷ Indeed, CEA has stood the test of time.

Although I am a vascular surgeon, I am also an interventionist who took part in the development of neuro-

protection devices and performed the first protected CAS procedure in the United States. Therefore, I have some bias toward CAS. However, based on the available data, I believe CEA should be performed over CAS whenever possible.⁸⁻¹¹ However, there is no such thing as a perfect operation or therapy with no room for improvement, and this is also true of CEA. For example, differences still exist between these revascularization strategies with regard to minor stroke and myocardial infarction (MI), with the latter being more prevalent in CEA. A comprehensive discussion of the advantages and disadvantages of both options and the clinical scenarios in which each procedure is most appropriate is beyond the scope of this paper, although

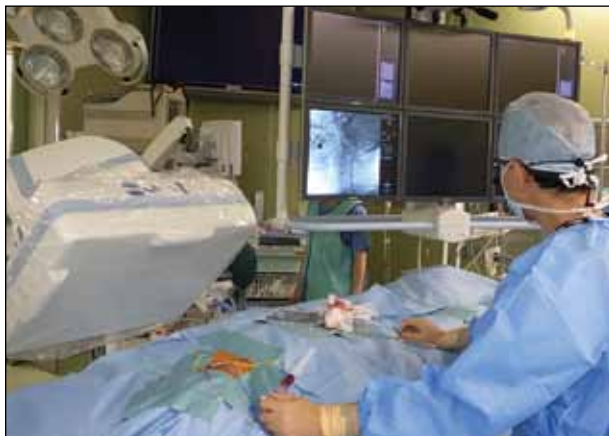

Figure 1. A 3-cm skin incision is made precisely over the carotid bifurcation using fluoroscopic guidance.

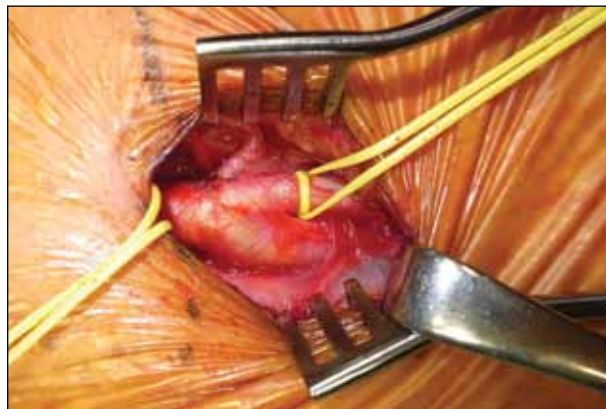


Figure 2. The retractor is used to visualize the distal ICA. Note that the CCA and the ECA are dissected, but the ICA is not (head toward right).

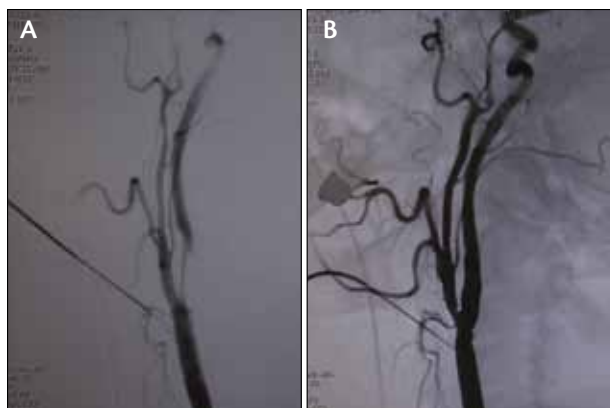

Figure 3. Intraoperative angiogram shows high-grade ICA stenosis (A). Completion angiogram shows satisfactory result with absence of distal flaps (B).

significant research continues in this regard. In this article, we detail the Jikei method, which attempts to make a reliable operation even better.

THE JIKEI METHOD

At the Jikei University School of Medicine in Tokyo, we have developed a CEA technique aimed at improving outcomes.¹² The Jikei method is characterized by a small-incision eversion technique along with unique vascular clamping sequences to minimize intraoperative embolization.

Mini Skin Incision

In order to optimize the location of the incision, we first identify the location of the carotid bifurcation relative to the cervical vertebrae using preoperative computed tomography angiography. In the operating room, a fluoroscope is used to localize the cervical vertebrae and thus the carotid bifurcation. Under this fluoroscopic guidance, a 3-cm skin incision is made precisely over the carotid bifurcation (Figure 1). This maneuver obviates creation of a large skin incision.

Carotid Exposure, Dissection, and the Vascular Clamping Sequence

In order to maximize the surgical field through the small skin incision, the neck skin is moved cranially and caudally with retractors as needed. When visualization of the common carotid artery (CCA) is needed, the incision is moved caudally and for distal internal carotid artery, it is moved cranially. Fortunately, the skin at the neck is very mobile and stretchable, making this maneuver effective.

It is well known that embolization during CEA primarily takes place during the dissection phase of the procedure and originates from the carotid plaque located within the internal carotid artery (ICA), so we only dis-

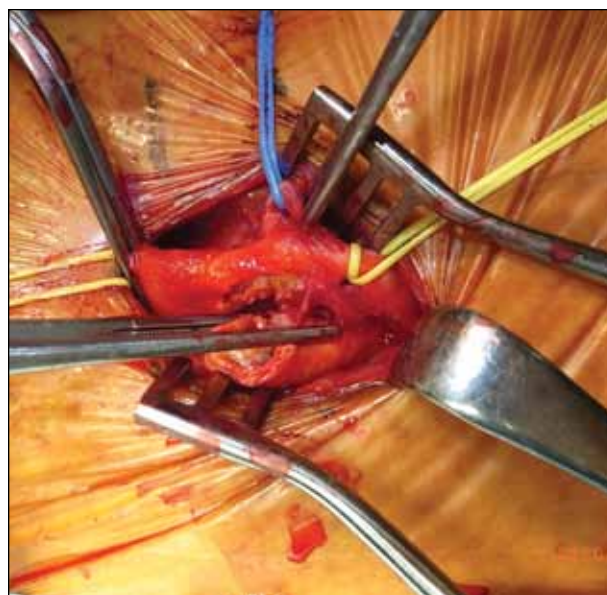


Figure 4. The retractor placed at the cranial edge of the skin incision can be pushed downward to compress the distal ICA and control the back bleeding. Note the absence of vascular clamp or loop on the ICA at this point (head toward right).

sect the CCA and the external carotid artery prior to vascular clamping and do not attempt to visualize the distal ICA (Figure 2). A 23-gauge needle is inserted in the CCA, and a preoperative carotid and intracranial angiogram is obtained (Figure 3A). After the CCA and ECA are exposed and clamped, the ICA is separated from the CCA at its orifice, as is done in standard eversion CEA procedures. Because a vascular clamp is not yet applied to the distal ICA at this time, a certain amount of bleeding from the ICA is encountered depending on how well developed the intracranial collaterals are. If back bleeding is excessive, a retractor placed at the cranial edge of the skin incision is pushed downward in order to compress the distal ICA (Figure 4). It is only at this point that the ICA or the sinus is maneuvered. Embolization may take place at this time, but because there is no prograde flow to the brain, the risk of stroke is very low; we have not experienced stroke in our series to date.

The proximal edge of the separated ICA is held with forceps, and circumferential dissection of the ICA is carried out distally. Distal ICA vascular clamps are applied only after this step. Eversion CEA is then carried out, and the plaque is resected from the ICA (Figure 5). Taking into account the ability to prevent embolization, the minimal amount of bleeding encountered between ICA arteriotomy and application of distal ICA clamping is of no concern; in fact, we have not encountered any cases requiring blood transfusion.

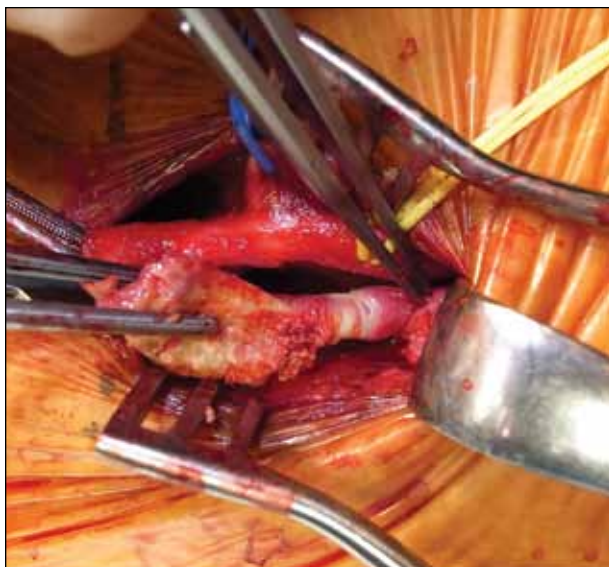


Figure 5. Eversion CEA is carried out.

If there is plaque within the CCA that requires endarterectomy, the cranially placed retractors are removed, and the incision (skin) is moved caudally to provide a better view of the proximal CCA (Figure 6). Finally, the ICA is sewn back to the CCA as is done during standard eversion CEAs. Aggressive flushing of air and loose materials is performed prior to tying the knot and releasing the vascular clamps. A 23-gauge needle is inserted in the CCA, and completion carotid and intracranial angiograms are taken to check for distal ICA flaps and intracranial embolization. The incision is closed in layers in a standard fashion (Figure 7).

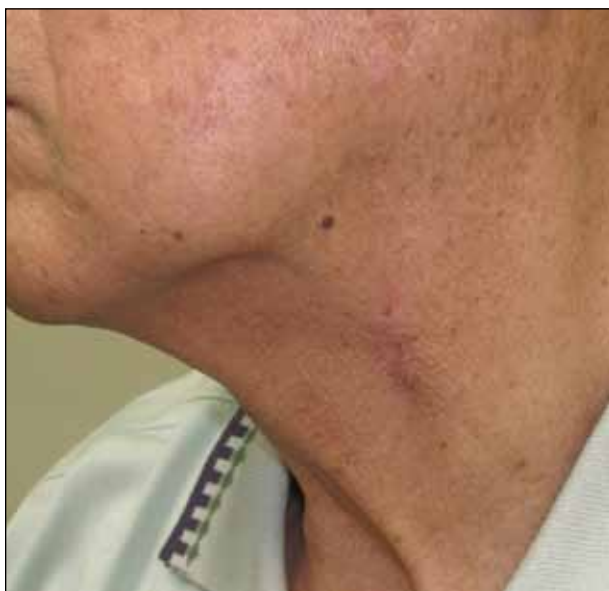

Figure 7. Six-month postoperative photograph of the mini incision (almost invisible).

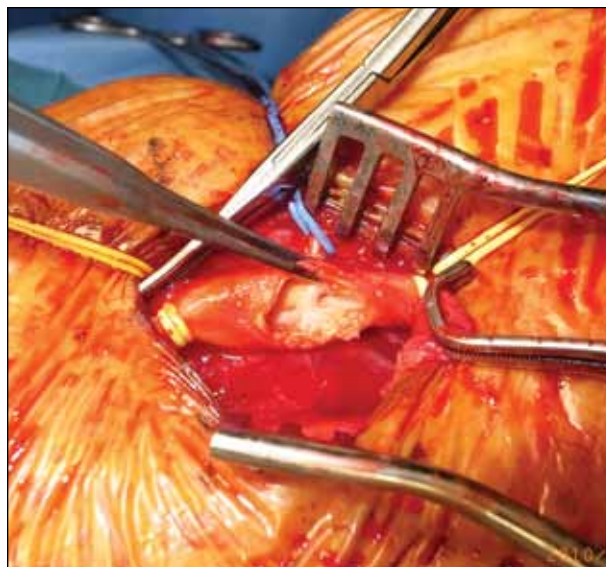


Figure 6. The incision (skin) can be moved caudally to provide a better view of the proximal CCA if needed.

POTENTIAL ADVANTAGES OF THE JIKEI METHOD

We performed the Jikei method in 70 cases between April 2008 and April 2011.¹² No intraoperative cerebral infarctions were observed, and every patient woke up without any neurological defects. A fatal cerebral hemorrhage due to hyperperfusion syndrome was observed on day 3 in one case (1.4%). Completion intracranial angiography has shown absence of cerebral embolization in every case. However, this imaging method is not as sensitive to microembolization as is diffusion-weighted magnetic resonance imaging (DW-MRI). The mean skin incision length was 3.1 ± 0.5 cm, and the mean clamping time was 36 ± 13 minutes.

I believe the Jikei method is advantageous compared to conventional CEA or standard eversion techniques for several reasons: (1) Because manipulation of the ICA is performed only after prograde flow to the brain is ceased, theoretically, the risk of intraoperative cerebral infarction is diminished. To date, we have not encountered one. (2) Although the conventional CEA method requires approximately a 10-cm skin incision, the Jikei method has minimized the aesthetic concern with a 3-cm incision. (3) The conventional method involves a longitudinal arteriotomy from the internal ICA to the CCA and often requires patching after endarterectomy. The eversion method involves only end-to-side anastomosis; the operative complexity is thus lessened, resulting in a short clamping time. In addition, foreign bodies (eg, patches, suture threads) that can lead to restenosis are not left at the delicate, distal end of the ICA, and Prolene sutures are left only at the ICA-CCA anastomosis

(Continued on page 77)

(Continued from page 70)

where there is little concern of restenosis due to the large vessel diameter.

POTENTIAL LIMITATIONS

We are currently conducting a trial to determine the occurrence rate of DW-MRI lesions after the Jikei method for CEA. Preliminary analyses have shown that only 6% of patients undergoing the Jikei method showed new DW-MRI lesions. This appears to be 44% to 72% less compared to that of standard eversion CEA reported in the literature,^{13,14} although our data are only preliminary at this time.

The Jikei method does not address the concern of perioperative myocardial infarction, one endpoint in which CAS bests CEA. However, due to careful perioperative hemodynamic monitoring and care in the ICU and possibly influenced by our relatively small sample size, we have not encountered a myocardial infarction in this series.

CONCLUSION

Based on our experience to date, we currently treat more than 80% of our carotid stenosis patients using CEA and less than 20% with protected CAS. In our practice, the Jikei method has made a reliable operation even better and the indication for CAS narrower. ■

Takao Ohki, MD, PhD, is Chairman of the Department of Surgery and Professor and Chief of the Division of Vascular Surgery at Jikei University School of Medicine in Tokyo, Japan. He has disclosed that he is a consultant for consultant for Boston Scientific Corporation, Medtronic, Inc., Gore & Associates, and Cordis Corporation. Dr. Ohki may be reached at +81-3-3433-1111 ex. 3400; takohki@msn.com.

1. European Carotid Surgery Trialists' Collaborative Group. Randomised trial of endarterectomy for recently symptomatic carotid stenosis. *Lancet*. 1998;351:1379-1387.
2. North American Symptomatic Carotid Endarterectomy Trial Collaborators. Beneficial effect of carotid endarterectomy in symptomatic patients with high-grade carotid stenosis. *N Engl J Med*. 1991;325:445-453.
3. Executive Committee for the Asymptomatic Carotid Atherosclerosis Study. Endarterectomy for asymptomatic carotid artery stenosis. *JAMA*. 1995;273: 1421-1428.
4. MRC Asymptomatic Carotid Surgery Trial (ACST) Collaborative Group. Prevention of disabling and fatal strokes by successful carotid endarterectomy in patients without recent neurological symptoms. *Lancet*. 2004;363:1491-1502.
5. The SPACE Collaborative Group. 30 day results from the SPACE trial of stent-protected angioplasty versus carotid endarterectomy in symptomatic patients. *Lancet*. 2006;368:1239-1247.
6. Mas JL, Chatellier G, Beyssens B, et al. Endarterectomy versus stenting in patients with symptomatic severe carotid stenosis. *N Engl J Med*. 2006;355:1660-1671.
7. Carotid Stenting Trialists' Collaboration. Short-term outcome after stenting versus endarterectomy for symptomatic carotid stenosis—a preplanned meta-analysis of individual patient data. *Lancet*. 2010;376: 1062-1073.
8. Ohki T, Marin ML, Lyon RT, et al. Human ex-vivo carotid artery bifurcation stenting: correlation of lesion characteristics with embolic potential. *J Vasc Surg*. 1998;27:463-471.
9. Ohki T, Veith FJ. The potential of the Percutaneous Guardwire to prevent embolic events in endovascular interventions. *Endovascular Multimedia Magazine*. 1998;2:33-38.
10. Ohki T, Roubin GS, Veith FJ, et al. The efficacy of a filter device in preventing embolic events during carotid artery stenting: an ex-vivo analysis. *J Vasc Surg*. 1999;30:1034-1044.
11. Ohki T, Veith FJ, Grenell S, et al. Initial experience with cerebral protection devices to prevent embolization during carotid artery stenting. *J Vasc Surg*. 2003;36:1175-1185.
12. Shukuzawa K, Sumi M, Kanaoka Y, Ohki T. Mini incisional eversion carotid endarterectomy to minimize embolic complications: the Jikei method. *Nihon Geka Gakkai Zasshi*. 2011;112:394-398.
13. Timaran CH, Rosero EB, Higuera A, et al. Randomized clinical trial of open-cell vs closed-cell stents for carotid stenting and effects of stent design on cerebral embolization. *J Vasc Surg*. 2011;54:1310-1316.
14. Barbato JE, Dillavou E, Horowitz MB, et al. A randomized trial of carotid artery stenting with and without cerebral protection. *J Vasc Surg*. 2008;47:760-765.