

MEDTRONIC MEDICAL AFFAIRS CORNER

SPONSORED BY
Medtronic

Intraprocedural Monitoring of Blood Flow Using FlowMet-R

By Mahmood K. Razavi, MD, FSIR, FSVM



The economic and health consequences of critical limb ischemia (CLI) have expanded research and development efforts. However, as we move forward, it is important to continue optimizing medical therapies and revascularization techniques.

Early and late failures are both common in the complex CLI patient population.¹ Given the multilevel and multivessel nature of the disease, as well as the complexities of endovascular revascularization strategies for CLI, careful planning and techniques are required to optimize procedural results, which may lead to better clinical outcomes. These key procedural decisions to give the best chances for wound healing include:

- How many vessels need to be addressed?
- Which vessels need to be addressed?
- How much flow is needed in each vessel?

THE PROBLEM

Currently, there are few objective methods to assess the adequacy of blood flow to the foot or ulcer during an interventional procedure apart from the angiographic appearance of the vessels. However, angiography alone does not provide reliable physiologic information, making it hard to predict when enough is enough. Common scenarios in below-the-knee (BTK) interventions, such as what to do with a 50% to 60% recoil or a grade C dissection, are often decided based on the operator's judgment. Similarly, how many and which vessels need to be approached and whether reestablishment of angiographic flow in a particular BTK vessel is sufficient cannot be objectively assessed while the patient is still on the angiography table. Common tools such as ankle-brachial index (ABI), toe-brachial index (TBI), or segmental pressures are used after the patient has left the angiography room and

provide no opportunity to fine-tune the revascularization procedure. Supplementary adjunctive techniques or revascularization of multiple vessels require expenditure of additional resources and time, as well as exposure of patients to additional contrast and both patients and personnel to radiation. Furthermore, opening more arteries may not always be possible and could result in complications. Hence, it is critical to know when enough is enough.

FLOWMET™*-R INTRAPROCEDURAL MONITORING SYSTEM

A noninvasive intraprocedural device called the FlowMet-R intraprocedural monitoring system (Laser Associated Sciences; Figure 1) received 510(k) clearance from the FDA in February 2019. This device uses a modified form of laser speckle imaging referred to as *affixed*

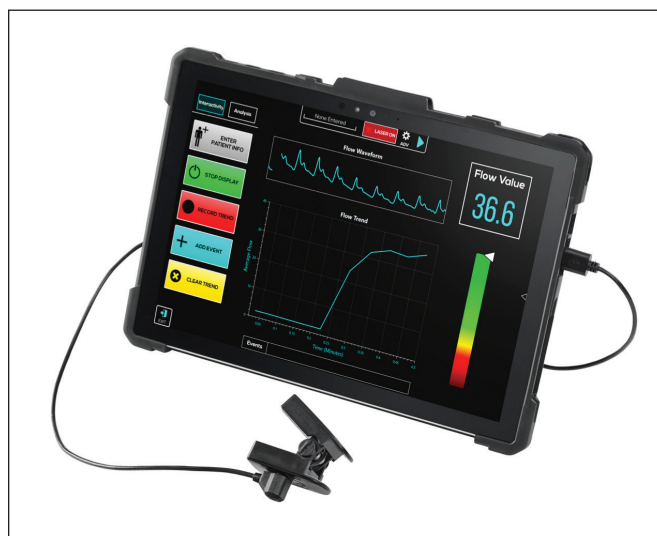


Figure 1. The FlowMet-R device display.

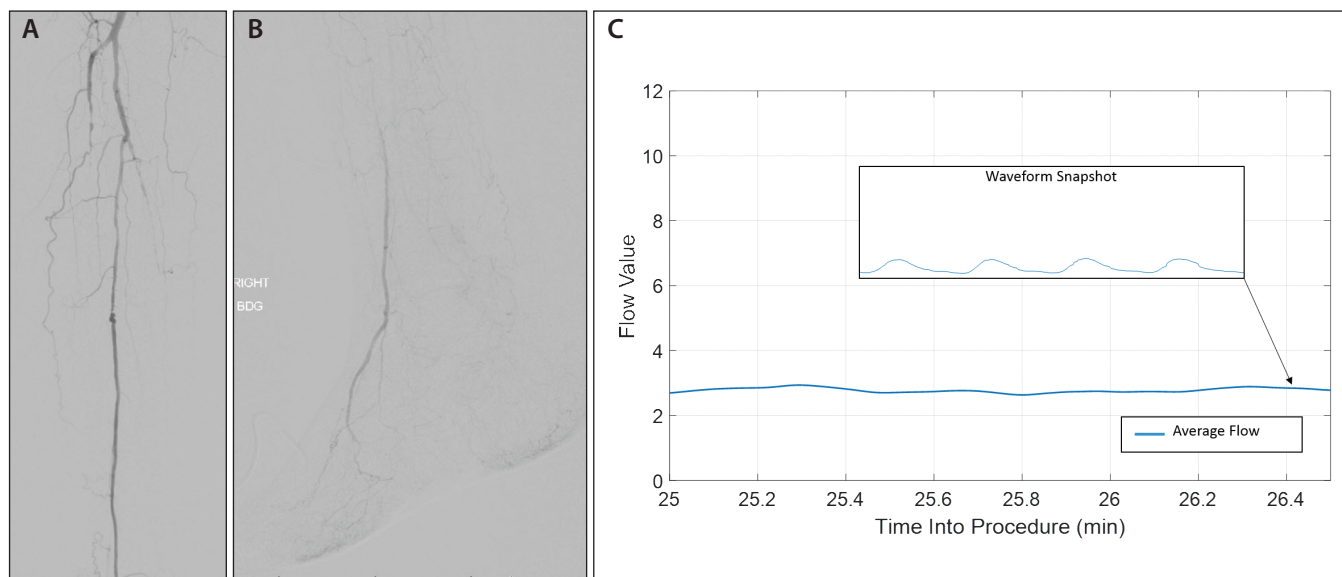


Figure 2. Baseline arteriography showing occlusion of anterior and posterior tibial arteries and reconstitution of ATA above the ankle (A, B). The FlowMet-R system flow values display showing low blood flow in the CLI range (C).

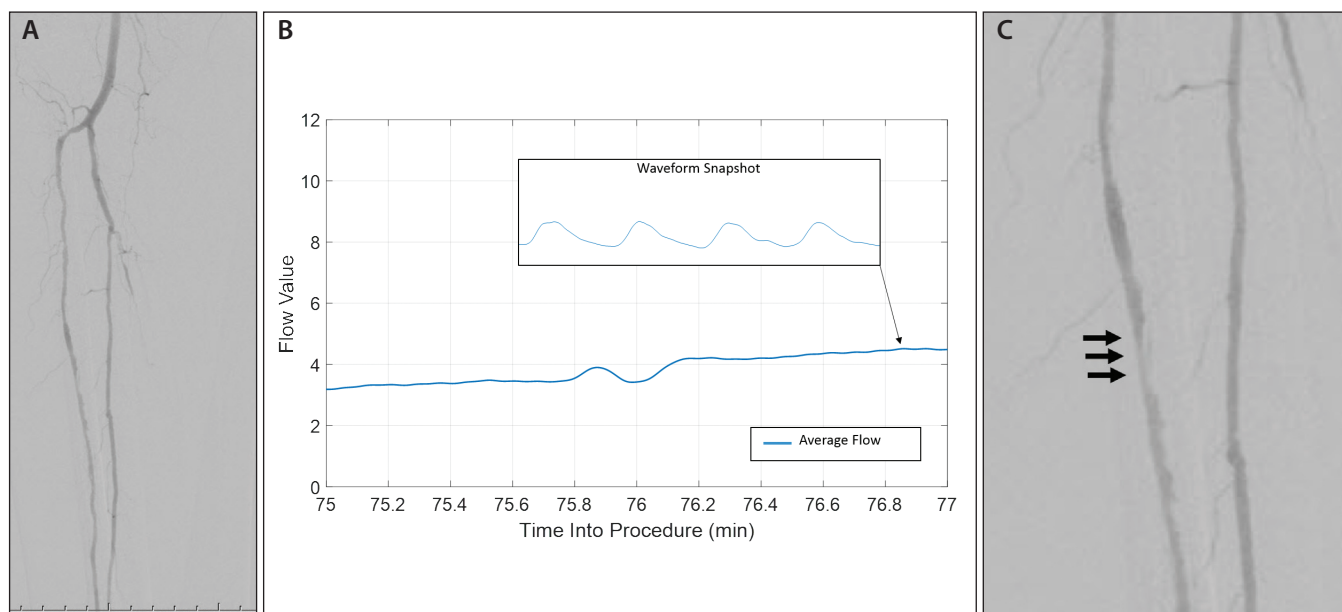


Figure 3. After recanalization and angioplasty of the ATA, angiographic flow is reestablished (A). The FlowMet-R system flow values display shows improved results above the CLI range (B). Despite improved flow and angiographic patency, focal recoil was seen a few minutes after balloon angioplasty (arrows) (C).

transmission speckle analysis to provide quantitative and real-time measurements of volumetric blood flow rates within digits. Unlike ABI and TBI, the device is not affected by arterial calcification.²

Given the previously discussed issues, we embarked on using the FlowMet-R intraprocedural monitoring system as a tool for intraprocedural assessment of blood flow. The device offers two metrics of real-time, continuous blood flow information: (1) flow value, which quantifies blood flow

using a numeric scale; and (2) velocity waveform, which reflects real-time changes in blood flow during the cardiac cycle, enabling the characterization of blood flow as "normal" or "abnormal."

The following case example demonstrates how the dual-modality feedback from the FlowMet-R intraprocedural monitoring system can guide the intervention. A man in his late 70s with diabetes mellitus, hypertension, and a history of compensated congestive heart failure presented with a

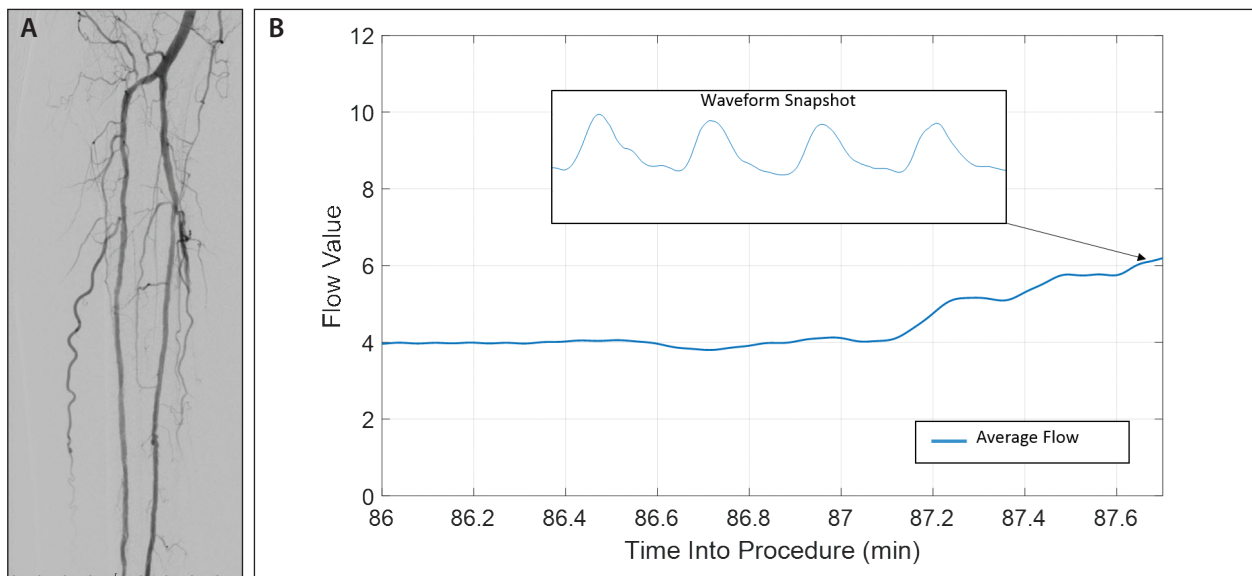


Figure 4. Prolonged balloon dilation with a larger balloon was performed in the ATA with improved angiographic appearance (A). The FlowMet-R system flow values show further improvement in flow, close to the normal range (B).

nonhealing ischemic wound on his second toe. A non-invasive exam showed multivessel disease involving the trifurcation vessels, with a TBI of 0.15 and toe pressure of 22 mm Hg. Angiography revealed occluded anterior and posterior tibial arteries and a 50% to 60% focal stenosis of the midperoneal artery (Figure 2A).

There was reconstitution of the anterior tibial artery (ATA) above the ankle, with the dorsalis pedis as the only vessel supplying blood to the toes (Figure 2B). The flow reading was in a range consistent with TBI and with what I see in my patients with CLI (Figure 2C).

After recanalization and balloon dilation of the ATA, the flow improved to above the CLI threshold in my practice (Figure 3A and 3B). Magnified views of the mid-ATA showed recoil in a short segment of the vessel (see the arrows in Figure 3C).

A common practical question at this point is whether we should take other adjunctive measures, such as scaffolding, or see how the patient fares in follow-up. In this case, although the flow was above my CLI threshold, we decided to escalate the treatment in an attempt to further improve the flow. This segment was thus redilated using a 0.5-mm larger balloon (Figure 4A). The flow value was close to my observed normal range (Figure 4B), and hence no stent or atherectomy was needed.

CONCLUSION

In this example, flow readings showed that recoil prevented resumption of optimal flow to toes, and a simple balloon maneuver was sufficient. Therefore, there was no need for implantation of scaffolding. Although satisfactory answers to the technical and procedural questions require more investigation, data so far suggest that real-time measurement of tissue blood flow rate can be used as a procedural guide. ■

Mahmood K. Razavi, MD, FSIR, FSVM

Medical Director, Comprehensive Aortic Center

Director, Department of Clinical Trials

St. Joseph Heart & Vascular Center

Orange, California

mravazi@pacbell.net

Disclosures: Paid advisor/consultant to Abbott

Vascular, Asahi, Boston Scientific Corporation,

Medtronic, Philips/Volcano, Terumo; shareholder of

LAS.

1. Abu Dabrh AM, Steffen MW, Undavalli C, et al. The natural history of untreated severe or critical limb ischemia. *J Vasc Surg.* 2015;62:1642-1651.e3.
2. Ankle Brachial Index Collaboration, Fowkes FG, Murray GD, et al. Ankle brachial index combined with Framingham risk score to predict cardiovascular events and mortality: a meta-analysis. *JAMA.* 2008;300:197-208.

FlowMet™-R intraprocedural monitoring system Reference Statement

Important Information: Indications, contraindications, warnings and instructions for use can be found in the product labeling supplied with each device.

Indications for Use: The FlowMet-R is a non-invasive probe that is affixed to the fingers or toes and intended to quantify tissue blood flow rate.

CAUTION: Federal (USA) law restricts this product for sale by or on the order of a physician.

© 2019 Medtronic. All rights reserved. Medtronic, Medtronic logo and Further, Together are trademarks of Medtronic. TM® third party brands are trademarks of their respective owner. All other brands are trademarks of a Medtronic company. 500146 A 10/19