

# Metastatic Osseous Disease: Current Interventional Oncology Treatment Options

Minimally invasive therapies such as embolization, thermal ablation, and consolidative therapy can be used for locoregional control and pain palliation or can be combined for a synergistic effect.

**BY STEVEN YEVICH, MD, MPH**

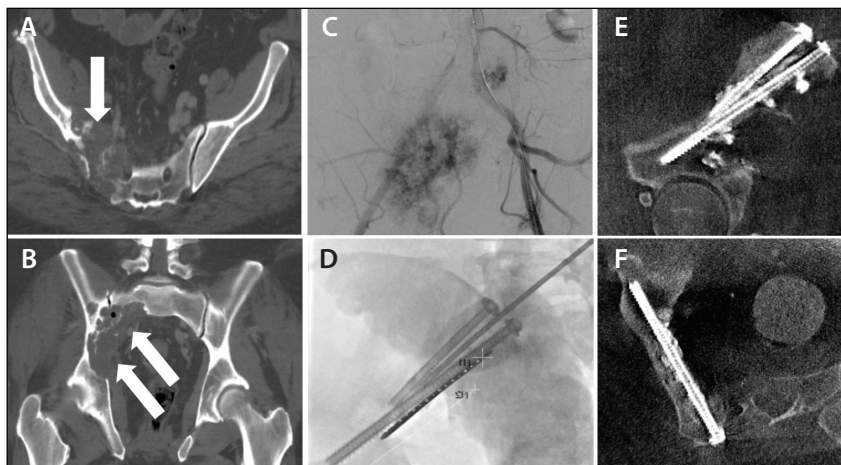
**T**he musculoskeletal system is the third most common site of metastatic disease after the liver and lung, with > 50% of cancer patients developing osseous metastases.<sup>1-4</sup> The associated morbidity with bone metastases includes pain, pathologic fracture, hypercalcemia, and neurologic deficits.<sup>5-7</sup> Minimally invasive therapies can relieve pain or provide locoregional control that translates into improvements in quality of life, decreased opioid dependence, improved mobility, and lower overall health care costs.<sup>7-11</sup> Treatment challenges can be attributed to the high variability in disease presentation. For example, the etiology of pain may be a result of structural bone instability, lost integrity of muscle and tendon insertions, cytokine-mediated tumor-associated inflammation, increased intraosseous pressure caused by tumor growth or increased vascularity, periosteal stretching, or extrinsic pressure on adjacent nerves and muscles.<sup>3,12</sup> To meet these challenges, multiple interventional oncology (IO) techniques have been developed.

Common IO procedures used to treat osseous metastases include tumor embolization, thermal ablation, vertebral augmentation, and cementoplasty.<sup>13</sup> In addition, image guidance software has expanded the capability to

stabilize pathologic fractures with percutaneous placement of cannulated screws. The procedural approach is often tailored to individual tumor biology, location, vascularity, and size. This article reviews the current IO treatment options for osseous metastases. Supportive literature and potential future research directions are discussed for each treatment separately.

## EMBOLIZATION

Embolization can be an effective treatment for hypervascular tumors as a presurgical adjunct to facilitate resection or as an independent pain palliative measure



**Figure 1.** A 55-year-old man with metastatic RCC of the right iliac and sacral bones (arrows) (A, B). Initial treatment with particle embolization resulted in improvement in resting pain (C). After embolization, mechanical pain with weight bearing persisted. Consolidative treatment with percutaneous screw fixation and cementoplasty significantly relieved mechanical pain (D–F).

(Figure 1); the latter will be the focus in this review.<sup>14-17</sup> Pain palliation occurs through impedance of locoregional osteolysis and reduction of tumor volume, which in combination, downregulates cytokine-mediated tumor-associated inflammation, decreases intraosseous pressure and periosteal stretching, and relieves tumoral compression on surrounding tissues and neurovascular structures. Multiple embolic materials can be used, including embolic beads, gelatin sponge, coils, or liquid agents such as ethanol, glue, or Onyx (Medtronic).<sup>18</sup> Microsphere or microparticulate embolization is typically performed to achieve distal occlusion, although the choice of embolic agent depends on operator experience, degree of tumor vascularity, tumor-feeding artery size, presence of arteriovenous shunting, and amount of collateral blood flow to the surrounding musculoskeletal tissue.

Several retrospective reviews support embolization as a pain palliative treatment, with most studies examining treatment of renal cell carcinoma (RCC) and thyroid metastases. A small case series of nine patients with metastatic RCC reported mild to marked immediate pain relief that lasted 1 to 6 months in all patients.<sup>19</sup> A more recent case series of 21 patients with metastatic RCC treated with embolization reported a > 50% decrease in narcotic use after treatment at 36 of 39 sites with a mean duration of 5.5 months.<sup>20</sup> In another study, embolization of 41 vascular thyroid metastases improved clinical symptoms in 59% (24/41) of treated lesions for at least 1 month without tumor progression.<sup>21</sup> To the author's knowledge, the largest retrospective review examined 309 embolization procedures in 243 cancer patients with painful bone metastases from renal, thyroid, breast, and lung cancer, reporting a > 50% reduction in Visual Analog Scale (VAS) and decreased analgesic use in 97% of procedures for a mean duration of 8.1 months.<sup>22</sup> Onset of pain relief occurred within 2 weeks of embolization for all studies.

Limitations and challenges exist in the current IO literature. The type of embolic agent employed is highly variable, as are the tumor types and subtypes. Subtle embolization outcome may be affected by the degree of vascularity, the amount of collateral circulation, or presence of intratumoral arteriovenous shunting. Furthermore, the location and size of osseous metastases may present confounding variables when assessing palliative outcome. For example, large lytic tumors located in weight-bearing bone may continue to cause pain due to structural instability from bone erosion. Lastly, the use of other treatments such as radiation therapy or chemotherapy combined with embolization is not uniformly reported. The combination of embolization and concomitant external therapy may

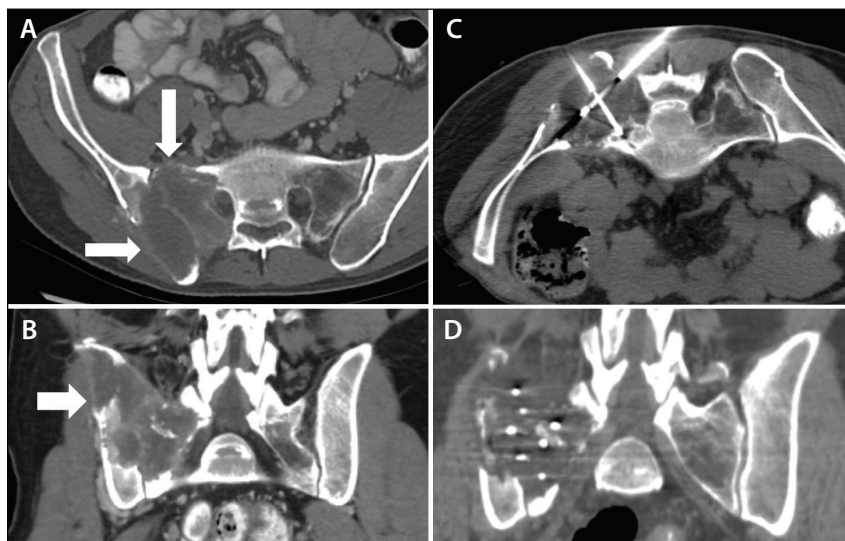
have synergistic effects. For example, Eustatia-Rutten et al noted an increased mean duration of pain palliation from 6 to 15.5 months in patients with thyroid cancer who underwent embolization combined with either radioiodine or external irradiation therapy.<sup>21</sup> A similar finding was seen in a smaller cohort of five patients with metastatic thyroid carcinoma treated with embolization and concomitant radioiodine treatment.<sup>23</sup>

Future embolization studies may benefit from a prospective design with a larger patient cohort, considering the aforementioned limitations and challenges in study design. In addition, the value of chemoembolization has not been thoroughly evaluated for osseous metastases. Koike et al evaluated the palliative treatment effect of either chemoembolization or bland embolization for 24 bone metastases from multiple different primary tumor types in 18 patients, although no direct comparison was offered.<sup>24</sup> Recent successes in the treatment of multiple cancer types with systemic or intratumoral injection of immunotherapy raise the question of whether concomitant treatment with embolization or endovascular injection plus embolization might augment local treatment or initiate an abscopal effect.

## THERMAL ABLATION

Thermal ablation encompasses a variety of percutaneous technologies that deliver energy within a defined ablation zone to achieve irreversible tumor cellular death.<sup>25</sup> The main thermal energy sources for ablation are radiofrequency, microwave, and cryotherapy (Figure 2). Thermal ablation can be used for pain palliation regardless of tumor size, although ablation of the interface between tumor and bone is usually sufficient to engender some symptomatic relief. The mechanism of pain relief is thought to occur through the destruction of sensory fibers supplying the periosteum, decompression of tumor volume, eradication of cytokine-producing tumor cells, and inhibition of osteoclast activity.<sup>26</sup> In addition, thermal ablation may provide an effective means for local control.<sup>27,28</sup> The selection of ablation modality depends on physician experience, patient comorbidities, and tumor location and size.<sup>13</sup>

Prospective trials have evaluated the effect of radiofrequency ablation and cryoablation on pain palliation of metastatic osseous disease. In a multicenter clinical trial for treatment of painful bone metastases, percutaneous radiofrequency ablation was found to decrease the worst pain score from 7.9 to 1.4 out of 10 at 24-week follow-up.<sup>29</sup> A subsequent single-arm prospective trial in 55 patients with a single painful bone metastasis demonstrated significant decrease in pain intensity and improved mood at 1- and 3-month



**Figure 2.** A 32-year-old man with metastatic RCC to the right sacrum and iliac bone (arrows) (A, B). Cryoablation was performed for pain control (C, D).

follow-up.<sup>30</sup> Evaluation of percutaneous cryoablation for the treatment of 69 painful bone metastases from multiple different primary cancers performed in a multicenter observational clinical trial reported significant pain relief in 75% of patients, with overall mean worst pain score decreasing from 7.1 to 5.1 out of 10 at 1 week and to 1.4 out of 10 at 6 months.<sup>31</sup> No significant difference was found when comparing palliative response in patients who underwent radiation prior to ablation. Across the majority of retrospective and prospective reports, patients can expect to have a lasting 2- to 3-point reduction in worst VAS pain score within the first week following ablation, regardless of the modality.

In comparison, the majority of studies that have evaluated the application of percutaneous thermal ablation for the local control of bone metastases are retrospective with small patient cohorts. Cryoablation of metastatic RCC to the bone in seven patients with 13 bone lesions (mean tumor size, 4.8 cm) demonstrated local control in 12 of 13 lesions with a median follow-up of 16 months.<sup>32</sup> A more recent retrospective cryoablation study in 40 patients with 50 RCC metastases (mean tumor size, 3.4 cm) reported an overall local control rate of 82% (41/50 lesions) with a median follow-up of 35 months.<sup>33</sup> A single-institute retrospective study of cryoablation of 40 patients with 52 tumors from multiple primary cancer types with a median size of 2 cm (range, 0.6–7.5 cm) reported local control in 87% (45/52 lesions) at a median follow-up of 21 months and with a median disease-free survival of 7 months.<sup>34</sup> The largest retrospective cohort evaluated 89 patients treated for

122 metastatic lesions of multiple primary cancer types with either radiofrequency ablation (74 lesions) or cryoablation (48 lesions), reporting a 1-year local control rate of 67% after a median follow-up of 22.8 months.<sup>35</sup>

Future studies of thermal ablation should include further evaluation of local control across different tumor types. The effects of ablation on sclerotic metastases by ablation modality should be assessed, as sclerotic lesions may be more responsive to cryoablation. In addition, the role of thermal ablation in oligometastases should be examined, as should the potentiation of palliative effects with radiation therapy,<sup>36</sup>

locoregional control in patients with recurrence after radiation therapy, and potential use as an adjunct to immunotherapies. Furthermore, the application for treatment in pediatric patients with metastatic disease may convey particular benefits in obviating the need for more invasive surgeries.<sup>37</sup>

Recent advances in imaging can be further explored to improve procedural safety and efficacy. Ablation margins may be difficult to accurately identify using CT, regardless of the modality employed, because of the high density of osseous structures. Advanced CT capabilities, such as metal artifact reduction algorithms and dual-energy CT, may help delineate the ablation margins or provide a means to facilitate computer-assisted detection. Further development of MRI-compatible bone needles may expand the potential for MRI-guided cryoablation.<sup>38–40</sup>

## CONSOLIDATIVE TECHNIQUES

Consolidative techniques for pain palliation include vertebral augmentation, cementoplasty, and percutaneous screw fixation. Vertebral augmentation and cementoplasty reinforce structurally weakened or fractured bones with the injection of bone cement through a percutaneously placed needle. The physical properties of bone cement (typically poly[methyl methacrylate] [PMMA]) provides resistance to the axial compressive forces experienced during weight-bearing activities. Vertebral augmentation encompasses the treatments of vertebroplasty and kyphoplasty,<sup>41</sup> while cementoplasty or osteoplasty applies the same techniques outside of the spine.<sup>42</sup> Percutaneous screw fixation



describes the minimally invasive placement of metallic screws across a bone lesion to stabilize or prevent a pathologic fracture.<sup>43-45</sup> The addition of metallic screws improves resistance to torque and tension stresses and provides a complement to the compression resistance of PMMA. Although the basic principles of internal fixation have been developed in surgical subspecialties, advanced IO imaging capabilities and expertise have driven a paradigm shift to extend this valuable palliative treatment option to nonsurgical candidates.

### Vertebral Augmentation

Vertebral augmentation has been extensively supported for the treatment of metastatic disease. The selection of vertebroplasty versus kyphoplasty is at the preference and discretion of the physician operator and based on operator experience, degree of vertebral body compression, and presence of tumor extension through the posterior vertebral body into the epidural space. In evaluating vertebroplasty results in 868 patients treated for vertebral body compression fractures of both metastatic and osteopenic etiology, patients with metastatic disease reported satisfactory pain results and decreased opiate analgesic dose requirements (83% vs 78%).<sup>46</sup> A multicenter randomized controlled trial of 134 patients with malignant vertebral compression fractures that compared kyphoplasty versus nonsurgical management reported a significant decrease in pain score in the treated group, without any significant change in the nontreated group.<sup>47</sup> In a meta-analysis of 111 studies including 4,235 patients and comparing vertebroplasty and kyphoplasty to treat pathologic compression fractures, the mean VAS pain score improved from  $\geq 7.0$  to  $< 4.0$ , with a corresponding reduction in analgesic use and improvement in pain-related disability scores.<sup>48</sup>

Future directions to improve the effects of vertebral augmentation include evaluation of combination treatment with thermal ablation to potentiate pain palliative effects.<sup>49</sup> Current small cohort reports remain inconclusive. A recent study has suggested that combination treatment improves safety by decreasing complications from cement leakage.<sup>50</sup>

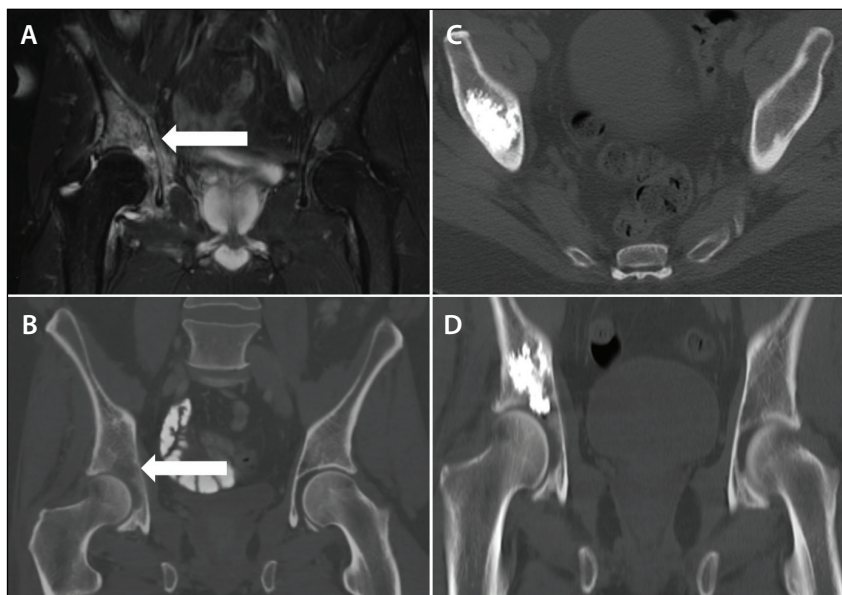
### Cementoplasty

Cementoplasty has shown a sustained palliative effect in patients with extraspinal metastatic bone disease (Figure 3). A retrospective review of the use of cementoplasty for 65 lesions in the pelvis or extremities demonstrated a significant decrease in VAS pain score from 8.19 to 3.02 at 3-month follow-up.<sup>51</sup> In a retrospective review of cementoplasty for 140 painful metastatic bone lesions outside of the spine in 105 patients, a significant pain reduction was seen in 91% of patients with a mean VAS pain score improvement from 8.7 to 1.9 after a median follow-up of 9 months.<sup>52</sup>

Future directions to improve the effects of extraspinal cementoplasty also include broader evaluation of the combination of a locoregional control method and cementoplasty. Several small case series have evaluated the feasibility of combination ablation and extraspinal cementoplasty, although to the author's knowledge, no direct comparison has been performed to evaluate pain palliative outcomes between combination treatment and cementoplasty alone.<sup>53</sup>

### Percutaneous Screw Fixation

Percutaneous screw fixation is predominantly performed for pain palliation or prevention of pathologic fractures in the pelvic ring or femoral neck (Figure 1). A recent retrospective review reported significant pain relief in the treatment of 20 pathologic fractures with mean VAS pain score improvement from 8 to



**Figure 3.** A 50-year-old man with lung adenocarcinoma. A metastatic lytic lesion to the right acetabular roof resulted in mechanical pain with weight bearing (arrows) (A, B). Consolidative treatment with percutaneous cementoplasty was performed (C, D).

2.5 out of 10.<sup>43</sup> In addition, the same study supported the application for the prevention of impending pathological fracture with the treatment of 45 locations in the pelvis and femoral neck.<sup>43</sup> Similar results have been confirmed in other small retrospective reviews.<sup>44-46,54</sup>

Future studies should continue to collect data on longer-term outcomes. In addition, the role for preventive treatment of potential impending pathological fractures outside of the femoral bones may prove beneficial for patients with large painful metastases that have yet to result in fracture. Lastly, combination treatments that include locoregional therapies such as thermal ablation or embolization may synergistically extend the duration of pain relief.

## CONCLUSION

Multiple valuable IO techniques have been advanced for the treatment of osseous metastases. Clinical success often relies on a tailored approach to address the challenges posed by the wide variability in metastatic tumor biology, location, size, and vascularity. The treatments can provide either locoregional control or pain palliation and may be combined for synergistic effect. Future research to cement the role of IO in bone relies on the continued collection of prospective large-cohort data. ■

- Coleman RE. Clinical features of metastatic bone disease and risk of skeletal morbidity. *Clin Cancer Res*. 2006;12:6243s-6249s.
- Roodman GD. Mechanisms of bone metastasis. *N Engl J Med*. 2004;350:1655-1664.
- Figura N, Smith J, Hsiang-Hsuan MY. Mechanisms of, and adjuvants for, bone pain. *Hematol Oncol Clin North Am*. 2018;32:447-458.
- Li S, Peng Yi, Weinhandl E, et al. Estimated number of prevalent cases of metastatic bone disease in the US adult population. *Clin Epidemiol*. 2012;4:87-93.
- Rizzoli R, Body JJ, Brandi ML, et al. Cancer-associated bone disease. *Osteoporos Int*. 2013;24:2929-2953.
- Oster G, Lamerato L, Glass A, et al. Natural history of skeletal-related events in patients with breast, lung, or prostate cancer and metastases to bone; a 15-year study in two large US health systems. *Support Care Cancer*. 2013;21:3279-3286.
- Saad F, Lipton A, Cook R, et al. Pathologic fractures correlate with reduced survival in patients with malignant bone disease. *Cancer*. 2007;110:1860-1867.
- Weinfurt KP, Li Y, Castel LD, et al. The impact of skeletal-related events on health-related quality of life in patients with metastatic prostate cancer. *Ann Oncol*. 2002;13(suppl 5):180.
- Sathikumar N, Detzell E, Morrisey MA, et al. Mortality following bone metastasis and skeletal-related events among women with breast cancer: a population-based analysis of U.S. Medicare beneficiaries, 1999-2006. *Breast Cancer Res Treat*. 2012;131:231-238.
- Oefelein MG, Ricchiuti V, Conrad W, Resnick MI. Skeletal fractures negatively correlate with overall survival in men with prostate cancer. *J Urol*. 2002;168:1005-1007.
- Lage MJ, Barber BL, Harrison DJ, Jun S. The cost of treating skeletal-related events in patients with prostate cancer. *Am J Manag Care*. 2008;14:317-322.
- Mundy GR. Mechanisms of bone metastasis. *Cancer*. 1997;80:1546-1556.
- Kurup AN, Callstrom MR. Expanding role of percutaneous ablative and consolidative treatments for musculoskeletal tumors. *Clin Radiol*. 2017;72:645-656.
- Ozkan E, Gupta S. Embolization of spinal tumors: vascular anatomy, indications, and technique. *Tech Vasc Interv Radiol*. 2011;14:129-140.
- Rilling WS, Chen GW. Preoperative embolization. *Semin Intervent Radiol*. 2004;21:3-9.
- Kobayashi K, Ozkan E, Tam A, et al. Preoperative embolization of spinal tumors: variables affecting intraoperative blood loss after embolization. *Acta Radiol*. 2012;53:935-942.
- Barton PP, Wanek RE, Kamel FJ, et al. Embolization of bone metastases. *J Vasc Interv Radiol*. 1996;7:81-88.
- Owen RJ. Embolization of musculoskeletal bone tumors. *Semin Intervent Radiol*. 2010;27:111-123.
- Chuang VP, Wallace S, Swanson D, et al. Arterial occlusion in the management of pain from metastatic renal carcinoma. *Radiology*. 1979;133(3 pt 1):611-614.
- Forauer AR, Kent E, Cwikiel W, et al. Selective palliative transcatheter embolization of bony metastases from renal cell carcinoma. *Acta Oncol*. 2007;46:1012-1018.
- Eustatia-Rutten CFA, Romijn JA, Guijt MJ, et al. Outcome of palliative embolization of bone metastases in differentiated thyroid carcinoma. *J Clin Endocrinol Metab*. 2003;88:3184-3189.
- Rossi G, Mavrogenis AF, Rimondi E, et al. Selective arterial embolisation for bone tumours: experience of 454 cases. *Radiol Med*. 2011;116:793-808.
- Van Tol KM, Hew JM, Jager PL, et al. Embolization in combination with radioiodine therapy for bone metastases from

- differentiated thyroid carcinoma. *Clin Endocrinol (Oxf)*. 2000;52:653-659.
- Koike Y, Takizawa K, Ogawa Y, et al. Transcatheter arterial chemoembolization (TACE) or embolization (TAE) for symptomatic bone metastases as a palliative treatment. *Cardiovasc Intervent Radiol*. 2011;34:793-801.
- Ahmed M, Brace C, Lee FT Jr, Goldberg S. Principles of and advances in percutaneous ablation. *Radiology*. 2011;258:351-369.
- Callstrom MR, Charboneau JW, Goetz MP, et al. Painful metastases involving bone: feasibility of percutaneous CT- and US-guided radio-frequency ablation. *Radiology*. 2002;224:87-97.
- Tomasian A, Wallace A, Northrup B, et al. Spine cryoablation: pain palliation and local tumor control for vertebral metastases. *Am J Neuroradiol*. 2016;37:189-195.
- Deschamps F, Farouil G, de Baere T. Percutaneous ablation of bone tumors. *Diagn Interv Imaging*. 2014;95:659-663.
- Goetz MP, Callstrom MR, Charboneau JW, et al. Percutaneous image-guided radiofrequency ablation of painful metastases involving bone: a multicenter study. *J Clin Oncol*. 2004;22:300-306.
- Dupuy DE, Liu D, Hartfield D, et al. Percutaneous radiofrequency ablation of painful osseous metastases: a multicenter American College of Radiology Imaging Network trial. *Cancer*. 2010;116:989-997.
- Callstrom MR, Dupuy DE, Solomon SB, et al. Percutaneous image-guided cryoablation of painful metastases involving bone: multicenter trial. *Cancer*. 2013;119:1033-1041.
- Bang HJ, Littrup PJ, Goodrich DJ, et al. Percutaneous cryoablation of metastatic renal cell carcinoma for local tumor control: Feasibility, outcomes, and estimated cost-effectiveness for palliation. *J Vasc Interv Radiol*. 2012;23:770-777.
- Gardner CS, Ensor JE, Ahrar K, et al. Cryoablation of bone metastases from renal cell carcinoma for local tumor control. *J Bone Joint Surg Am*. 2017;99:1916-1926.
- McMenomy BP, Kurup AN, Johnson GB, et al. Percutaneous cryoablation of musculoskeletal oligometastatic disease for complete remission. *J Vasc Interv Radiol*. 2013;24:207-213.
- Deschamps F, Farouil G, Ternes N, et al. Thermal ablation techniques: a curative treatment of bone metastases in selected patients? *Eur Radiol*. 2014;24:1971-1980.
- Di Staso M, Gravina GL, Zugaro L, et al. Treatment of solitary painful osseous metastases with radiotherapy, cryoablation or combined therapy: propensity matching analysis in 175 patients. *PLoS One*. 2015;10:e0129021.
- Botsa E, Poulou LS, Koutsogiannis I, et al. CT-guided radiofrequency tumor ablation in children. *Pediatr Radiol*. 2014;44:1421-1425.
- Smith KA, Carrino JA. MRI-guided interventions of the musculoskeletal system. *J Magn Reson Imaging*. 2008;27:339-346.
- Blanco Sequeiros R, Ojala R, Kariniemi J, et al. MR-guided interventional procedures: a review. *Acta Radiol*. 2005;46:576-586.
- Ahrar K, Sabir SH, Yevich SM, et al. MRI-guided interventions in musculoskeletal system. *Top Magn Reson Imaging*. 2018;27:129-139.
- Ruiz Santiago F, Santiago Chinchilla A, Guzmán Alvarez LG, et al. Comparative review of vertebroplasty and kyphoplasty. *World J Radiol*. 2014;6:329-343.
- Deschamps F, de Baere T. Cementoplasty of bone metastases. *Diagn Interv Imaging*. 2012;93:685-689.
- Deschamps F, de Baere T, Hakime A, et al. Percutaneous osteosynthesis in the pelvis in cancer patients. *Eur Radiol*. 2016;26:1631-1639.
- Deschamps F, Farouil G, Hakime A, et al. Percutaneous stabilization of impending pathological fracture of the proximal femur. *Cardiovasc Intervent Radiol*. 2012;35:1428-1432.
- Cazzato RL, Koch G, Buy, et al. Percutaneous image-guided screw fixation of bone lesions in cancer patients: double-centre analysis of outcomes including local evolution of the treated focus. *Cardiovasc Intervent Radiol*. 2016;39:1455-1463.
- Gangi A, Guth S, Imbert JP, et al. Percutaneous vertebroplasty: indications, technique, and results. *Radiographics*. 2003;23:e10.
- Berenson J, Pflugmacher R, Jarzem P, et al. Balloon kyphoplasty versus non-surgical fracture management for treatment of painful vertebral body compression fractures in patients with cancer: a multicenter, randomized controlled trial. *Lancet Oncol*. 2011;12:225-235.
- Health Quality Ontario. Vertebral augmentation involving vertebroplasty or kyphoplasty for cancer-related vertebral compression fractures: a systematic review. *Ont Health Technol Assess Ser*. 2016;16:1-202.
- Kam NM, Maignard J, Kok HK, et al. Combined vertebral augmentation and radiofrequency ablation in the management of spinal metastases: an update. *Curr Treat Options Oncol*. 2017;18:74.
- David E, Kaduri S, Yee A, et al. Initial single center experience: radiofrequency ablation assisted vertebroplasty and osteoplasty using a bipolar device in the palliation of bone metastases. *Ann Palliat Med*. 2017;6:118-124.
- Sun G, Jin P, Xun-wei L, et al. Cementoplasty for managing painful bone metastases outside the spine. *Eur Radiol*. 2014;24:731-737.
- Anselmetti GC. Osteoplasty: percutaneous bone cement injection beyond the spine. *Semin Intervent Radiol*. 2010;27:199-208.
- Basile A, Giuliano G, Scuderi V, et al. Cementoplasty in the management of painful extraspinal bone metastases: our experience. *Radiol Med*. 2008;113:1018-1028.
- Puscoddu C, Fancellu A, Ballicu N, et al. CT-guided percutaneous screw fixation plus cementoplasty in the treatment of painful bone metastases with fractures of a high risk of pathological fracture. *Skeletal Radiol*. 2017;46:539-545.

## Steven Yevich, MD, MPH

Department of Interventional Radiology  
Division of Diagnostic Imaging  
The University of Texas MD Anderson Cancer Center  
Houston, Texas  
syevich@mdanderson.org  
*Disclosures: Consultant to Healthtronics Endocare.*