

Plaque Excision for Treatment of Restenosis

Use of a novel device for recurrent stenosis in the superficial femoral artery.

BY BARRY S. WEINSTOCK, MD

Percutaneous intervention in the superficial femoral artery (SFA) has long been the poor stepchild of peripheral vascular intervention. Compared to the remarkably good results obtained in other vascular beds, such as the iliac and renal arteries and in the coronary arteries using drug-eluting stents, the results in the SFA have been disappointing.^{1,2} Multiple characteristics of the SFA contribute to the less durable results after SFA intervention. Specifically, vessel shortening, elongation and torsion, vessel length, flexion of the vessel due to bending the knee, reduced flow due to outflow disease, and external compression of the vessel by surrounding musculature all decrease the likelihood of long-term interventional success in the SFA.

Particularly in patients with long-segment disease and total occlusions, long-term results have been so poor that patients are frequently managed medically or are referred for femoropopliteal bypass rather than proceeding with intervention with a low chance for long-term patency. Restenosis rates at 12 months, even for relatively short lesions, often exceed 50% and results are even worse in patients with diabetes, a history of smoking, or poor distal run-off.

Because of the limitations of balloon angioplasty in the SFA, many alternative percutaneous approaches have been studied. Various investigators have evaluated laser angioplasty,³ rotational⁴ and directional atherectomy,^{5,6} remote endarterectomy,⁷ cutting balloon angio-

plasty,⁸ cryoplasty (studies in progress), phototherapy,⁹ and a wide variety of stents, including spiral stents,¹⁰ balloon-expandable stents,¹¹ self-expanding stents of various materials and designs,¹² and covered stents.¹³ This list is not exhaustive.

Although there has been considerable recent interest in the use of nitinol self-expanding stents in the SFA based on reduced restenosis rates compared to balloon angioplasty, there are also concerns about this approach related to the frequent use of multiple, overlapping stents for long-segment disease and the difficulties of treating diffuse pattern stent restenosis and in-stent total occlusions. Additionally, longer-term follow-up of SFA stents has shown a disturbing frequency of stent fracture, often with clinical sequelae.¹⁴ As a result, many centers continue to utilize balloon angioplasty as the primary intervention for SFA disease, with stents used for bail-out of suboptimal results. However, the most commonly encountered restenosis lesions for peripheral vascular interventionalists remain restenosis after SFA balloon angioplasty or stenting.

RESTENOSIS: PREVENTION VERSUS TREATMENT

A remarkable amount of research has been devoted to preventing restenosis after interventions in the SFA, yet very little research has been devoted to treatment of restenosis. In addition to the use of nitinol stents, trials are currently underway that use approaches as varied as

intravascular¹⁵ and external beam¹⁶ brachytherapy at the time of initial treatment to the use of drug-eluting nitinol stents¹⁷ using compounds that have been successfully used with coronary stents. Early results from these trials suggest that these approaches delay but do not necessarily prevent restenosis. Should either of these approaches eventually receive approval for widespread clinical use, such treatment would be expected to be unwieldy (brachytherapy) or expensive (drug-eluting stents). Thus far, no studies evaluating the use of any adjunctive medication have been shown to reduce the incidence of restenosis after SFA intervention.

Despite the plethora of published data documenting efforts to prevent restenosis in the SFA, there is little medical literature concerning interventional treatment of recurrent disease in this challenging vessel. Although brachytherapy and drug-eluting stents potentially may be helpful in this area, neither is approved for clinical use at present.

A trial comparing PTA with adjunctive endovascular brachytherapy (EBVT) versus PTA alone for restenotic lesions after PTA demonstrated an encouraging reduction in the 1-year restenosis rate after PTA of restenotic lesions with adjunctive brachytherapy (23% vs 42%; $P=.028$). Of note, the primary technical failure rate for EBVT was 14%.¹⁸

Schillinger et al¹⁹ compared PTA versus stenting for *de novo* and restenotic lesions after PTA. In this nonrandomized, retrospective study, the 12-month patency rate after PTA for restenosis was a dismal 33% compared to 61% for *de novo* lesions ($P<.0001$). The 12-month patency rate after stenting was 58% for *de novo* lesions, which was similar to the patency rate of 52% after stenting of restenotic lesions. However, the restenosis arm of this trial was relatively small: there were 99 patients treated with PTA for SFA restenosis, but only 19 patients were treated with a stent for restenosis. The unequal group sizes and lack of randomization suggest the presence of selection bias. Although the limitations of this study make it difficult to draw meaningful conclusions regarding the role of stenting for SFA restenosis, the results in the PTA arm suggest that PTA is not an optimal or even acceptable strategy.

In the absence of large-scale published trials, physicians literally are left to their own devices. In many cases, particularly in instances of stent restenosis, this results in lesions simply being redilated with balloon

angioplasty. In cases of PTA restenosis, some interventionalists will try placing a stent despite the pathophysiologic and histologic differences between *de novo* and restenotic lesions. Small trials for treatment of restenosis confirm that the results of such approaches typically yield results similar to previous experience in coronary arteries. Initial restenosis is highly predictive of an increased risk of further restenosis and target vessel failure.

The magnitude of the SFA restenosis problem is enormous. More than 150,000 SFA stent cases per year are performed, with an approximate restenosis rate of 30%, resulting in 45,000 cases of stent restenosis each year. The number of SFA balloon angioplasty procedures per year exceeds the number of stent procedures and has an even higher rate of restenosis. As a result, more than 100,000 cases per year of SFA restenosis can be expected—a problem for which there is presently no clear solution and little data to guide interventionalists regarding management.

NEW TREATMENT FOR SFA DISEASE

SilverHawk Plaque Excision

The FoxHollow SilverHawk plaque excision catheter (FoxHollow Technologies, Redwood City, CA) has been approved as of June 2003 for treating *de novo* and restenotic peripheral vascular disease. At our institution, we have successfully treated more than 50 *de novo* and restenotic focal lesions, long lesions, and total occlusions of the SFA, popliteal, and tibioperoneal vessels using the SilverHawk device since November 2003. During that time, multiple enhancements have been made to the

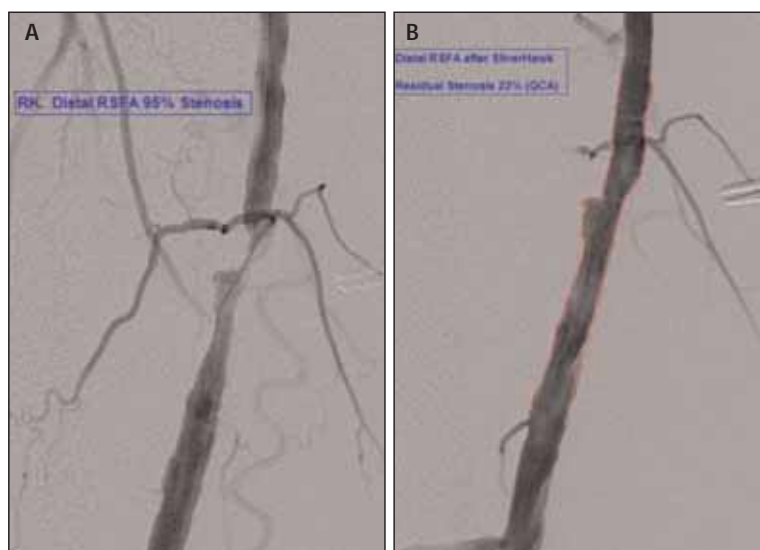


Figure 1. Distal right SFA stenosis 25 months after angioplasty (A). Distal right SFA restenosis after SilverHawk plaque excision (B).

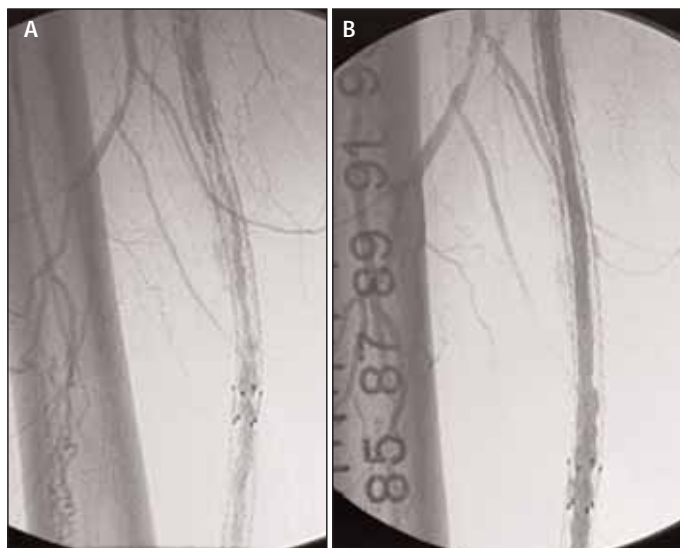


Figure 2. SFA diffuse pattern restenosis (A). Diffuse SFA stent restenosis after SilverHawk plaque excision. (Courtesy of Craig Walker, MD) (B).

SilverHawk catheter, and it is likely that an even lower residual stenosis would be obtained in this patient using the current version of the device. Because the efficiency of the device has been optimized, improved angiographic results and higher volumes of excised plaque have been observed.

Although directional atherectomy has been evaluated in the peripheral vasculature in the past, previous atherectomy devices relied on a balloon to engage the cutting blade into the plaque. Therefore, previous results were often a combination of balloon angioplasty (with resulting barotrauma) and atherectomy. The advantage of the SilverHawk device compared to earlier atherectomy devices is that all vessel barotrauma has been eliminated because the catheter does not use a balloon to oppose the directional cutting window into the plaque. Instead, activation of the cutter is associated with angulation of the device at the level of the cutting window, which displaces the cutter laterally into the plaque. The SilverHawk is easily oriented directionally under fluoroscopy. As the entire catheter is advanced forward, the excised plaque is collected in the nosecone. Because the entire catheter is advanced rather than the cutting blade moving within the confines of a small cutting window, this device is particularly well suited to treatment of long stenoses—a common challenge often encountered in the setting of diffuse pattern stent restenosis.

We have frequently used the SilverHawk to treat severe occlusive *de novo* disease extending in a diffuse pattern from the common femoral bifurcation to the

popliteal artery. The current-generation SilverHawk is highly efficient at plaque removal—as much as 500 mg of plaque is removed from a single vessel. Because the nosecone may be emptied of plaque, the catheter can be reused several times in a patient to allow large-volume plaque excision over long disease segments. Furthermore, the device is ideally suited to excising the firm, fibrous tissue typically seen in restenotic lesions and is capable of cutting all but the most highly calcified plaque.

Acute procedural results from more than 350 patients (more than 730 lesions) have been collected in TALON, a national multicenter registry. Approximately 15% of all lesions treated thus far are restenotic. As reported at the 2004 TCT meeting, the 6-month target lesion revascularization (TLR) rate in 86 patients (170 lesions) who have been followed for at least 6 months postprocedure is 11%. TLR data for the restenotic lesion subset treated by SilverHawk are forthcoming.

Several single-center registries in progress include a subset of patients with restenosis. Highly encouraging acute results are being reported, as well as lower-than-usual rates of restenosis in the SFA. Six-month angiographic SFA restenosis rates at the Cardiovascular Institute of the South (personal communication, Craig Walker, MD, September 2004) and at Arizona Heart Institute (personal communication, Venkatesh Ramaiah, MD, September 2004) are less than 10%. (These data were presented at the 2004 TCT meeting.) Although longer-term follow-up is required, these encouraging early results suggest that the SilverHawk device warrants further consideration in treating restenotic lesions that occur after balloon angioplasty and stenting of the SFA and popliteal artery. Both of these centers (as well as other institutions) have used the SilverHawk for restenosis after PTA, as well as for restenosis of a wide variety of stents in the SFA with excellent acute angiographic results (Figure 2A and B). Adjunctive PTA and stenting is typically required more commonly (35%-40%) when treating in-stent restenosis than in *de novo* or non-stent restenotic lesions in which plaque excision is almost always performed as a stand-alone procedure. Six-month angiographic restenosis data are being accumulated and should be available in 2005.

CASE STUDY

Use of the FoxHollow SilverHawk for PTA Restenosis

The patient was a 72-year-old, physically active man who had a history of myocardial infarction, coronary stenting, long-standing type II diabetes, severe dyslipi-

demia requiring multiple lipid-lowering medications, and a 100 pack-year history of smoking, which he discontinued in 1999. He underwent right SFA angioplasty in August 2002 for focal but highly symptomatic disease resulting in right lower-extremity claudication. The patient was referred in March 2004 because of recurrent claudication. His ankle-brachial index, which was normal after angioplasty, was again reduced (0.7), and duplex imaging was consistent with recurrent high-grade stenosis in the distal right SFA. The patient expressed an interest in stenting of this stenosis rather than balloon angioplasty. After discussion of his therapeutic options, he agreed to undergo treatment with the SilverHawk plaque excision device as a potentially superior alternative to repeat PTA or stenting.

Angiography revealed that there was iliac stenosis bilaterally, but maximum stenosis was only 50% to 60%, and no pressure gradient was present. The right SFA was patent with a moderately calcified, eccentric, and irregular 95% stenosis at the level of the adductor canal (Figure 1A). Three-vessel run-off was present distally. A 7-F, contralateral introducer sheath was advanced from the left femoral artery to the right femoral artery over the aortoiliac bifurcation. The patient was anticoagulated with intravenous heparin, and a .014-inch guidewire was advanced to the popliteal artery. Multiple passes across the distal SFA stenosis were performed using the LS SilverHawk plaque excision catheter. A final residual stenosis of 23% (by QCA) was achieved (Figure 1B). No adjunctive PTA or stent placement was used in an effort to avoid vessel barotrauma. At 5-month clinical follow-up, the patient remained highly active and was free of any claudication symptoms. Six-month lower-extremity duplex study will be obtained to more objectively re-evaluate the angiographic result.

CONCLUSIONS

Treating restenosis in the SFA remains a vexing problem—more challenging than primary intervention in the SFA due to low patency rates after repeat PTA and limited data with stenting for restenosis superimposed on the long-term risk of stent fracture. Drug-eluting stents or EBVT someday may represent reasonable therapeutic options. Meanwhile, interventionists will continue to struggle with this clinical dilemma.

Based on preliminary results, SilverHawk plaque excision appears to be a promising treatment for femoropopliteal and tibioperoneal disease ranging from focal stenosis to long total occlusion. Although acute results using this new device for treatment of restenosis appear excellent, long-term follow-up data are limited and there are no randomized trials underway comparing this tech-

nique to other modalities for treating SFA restenosis. However, in the absence of compelling data for use of PTA and the potential problems associated with stenting the SFA for restenosis treatment, SilverHawk plaque excision is a very reasonable alternative. Further data will be required before it can be determined with certainty if SilverHawk plaque excision will evolve into the procedure of choice for treatment of SFA restenosis. ■

Barry S. Weinstock, MD, is Director, Vascular Intervention Center, Mid-Florida Cardiology Specialists, Orlando, Florida. He has disclosed that he is a shareholder in FoxHollow Technologies. Dr. Weinstock may be reached at (407) 351-5384; heartdoc1@cfl.rr.com.

1. Karch LA, Mattos MA, Henretta JP, et al. Clinical failure after percutaneous transluminal angioplasty of the superficial femoral and popliteal arteries. *J Vasc Surg.* 2000;31:880-887.
2. Cheng SW, Ting AC, Wong J. Endovascular stenting of superficial femoral artery stenosis and occlusions: results and risk factor analysis. *Cardiovasc Surg.* 2001;9:133-140.
3. Wissgott C, Scheinert D, Rademaker J, et al. Treatment of long superficial femoral artery occlusions with excimer laser angioplasty: long-term results after 48 months. *Acta Radiol.* 2004;45:23-29.
4. Dorros G, Iyer S, Zaitoun R, et al. Acute angiographic and clinical outcome of high speed percutaneous rotational atherectomy (Rotablator). *Cathet Cardiovasc Diagn.* 1991;22:157-166.
5. Tielbeek AV, Vroegindewij D, Buth J, et al. Comparison of balloon angioplasty and Simpson atherectomy for lesions in the femoro-popliteal artery: angiographic and clinical results of a prospective randomized trial. *J Vasc Intervent Radiol.* 1996;7:837-844.
6. Vroegindewij D, Kemper FJ, Tielbeek AV, et al. Recurrence of stenoses following balloon angioplasty and Simpson atherectomy of the femoro-popliteal segment. A randomised comparative 1-year follow-up study using colour flow duplex. *Eur J Vasc Surg.* 1992;6:164-171.
7. Nelson PR, Powell RJ, Proia RR, et al. Results of endovascular superficial femoral endarterectomy. *J Vasc Surg.* 2001;34:526-531.
8. Ansel GM, Sample NS, Botti CF III Jr, et al. Cutting balloon angioplasty of the popliteal and infra-popliteal vessels for symptomatic limb ischemia. *Catheter Cardiovasc Interv.* 2004;61:1-4.
9. Mansfield RJ, Jenkins MP, Pai ML, et al. Long-term safety and efficacy of superficial femoral artery angioplasty with adjuvant photodynamic therapy to prevent restenosis. *Br J Surg.* 2002;89:1538-1539.
10. Rosenthal D, Martin JD, Schubart PJ, et al. Remote superficial femoral artery endarterectomy and distal aSpire stenting: multicenter medium-term results. *J Vasc Surg.* 2004;40:67-72.
11. Grimm J, Muller-Hulsbeck S, Jahnke T, et al. Randomized study to compare PTA alone versus PTA with Palmaz stent placement for femoro-popliteal lesions. *J Vasc Intervent Radiol.* 2001;12:935-942.
12. Lugmayr HF, Holzer H, Kastner M, et al. Treatment of complex arteriosclerotic lesions with nitinol stents in the superficial femoral and popliteal arteries: a midterm follow-up. *Radiology.* 2002;222:37-43.
13. Bray PJ, Robson WJ, Bray AE. Percutaneous treatment of long superficial femoral artery occlusive disease: efficacy of the Hemobahn stent-graft. *J Endovasc Ther.* 2003;10:619-628.
14. Allie DE, Hebert CJ, Walker CW. Nitinol stent fractures in the SFA. *Endovasc Today.* 2004;3(7):22-34.
15. Waksman R, Laird JR, Jurkovic CT, et al. Intravascular radiation therapy after balloon angioplasty of narrowed femoro-popliteal arteries to prevent restenosis: results of the PARIS feasibility clinical trial. *J Vasc Intervent Radiol.* 2001;12:915-921.
16. Fritz P, Stein U, Hasslacher C, et al. External beam radiotherapy fails to prevent restenosis after iliac or femoropopliteal percutaneous transluminal angioplasty: results of a prospective randomized double-blind study. *Int J Radiat Oncol Biol Phys.* 2004;59:815-821.
17. Duda SH, Pusich B, Richter G, et al. Sirolimus-eluting stents for the treatment of obstructive superficial femoral artery disease: six-month results. *Circulation.* 2002;106:1505-1509.
18. Zehnder T, von Briel C, Baumgartner I, et al. Endovascular brachytherapy after percutaneous transluminal angioplasty of recurrent femoropopliteal obstructions. *J Endovasc Ther.* 2003;10:304-311.
19. Schillinger M, Mlekusch W, Haumer M, et al. Angioplasty and elective stenting of de novo versus recurrent femoropopliteal lesions: 1-year follow-up. *J Endovasc Ther.* 2003;10:288-297.