

# Options for In-Stent Restenosis in 2018

Capabilities and limitations of current technologies and available data.

**BY BRIAN G. DeRUBERTIS, MD, FACS**

**P**ercutaneous treatment of femoropopliteal disease began as early as the 1960s, when Charles Dotter introduced the concept of arterial remodeling following intervention. However, the first reported peripheral angioplasty was ultimately performed in 1977 by Andreas Gruentzig. Over the next 2 decades, there was a gradual evolution of angioplasty devices and techniques, including the development of peripheral angioplasty balloons in both over-the-wire and monorail platforms on catheter lengths appropriate for the peripheral vascular beds. Although these devices allowed for restoration of flow in stenotic or occluded vessels, the problems of elastic recoil, dissection, and restenosis due to intimal hyperplasia continued to plague these interventions during follow-up.

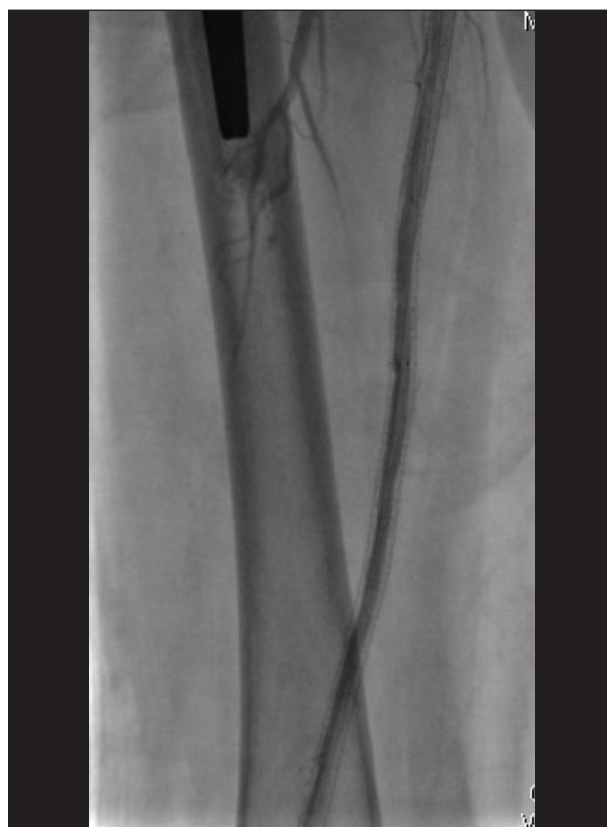Primary patency after these interventions was significantly impacted by these challenges and was considerably less than that seen with surgical bypass operations. To manage the acute issues of recoil and flow-limiting dissection, operators began using self-expanding nitinol stents designed for the biliary tree in an off-label fashion with relatively good results in the femoral and popliteal arteries. Justification for use of these devices even came in the form of randomized controlled clinical trial data, including an article in *The New England Journal of Medicine* by Schillinger and colleagues, which demonstrated improved maximal walking distance and reduced restenosis at 12 months in patients treated with primary stent implantation versus the standard strategy of balloon angioplasty with selective stent use for residual dissections or residual stenoses.<sup>1</sup>

As stent use became commonplace, multiple stents were evaluated through investigational device exemption studies that attained FDA approval for the use of these devices in the superficial femoral artery (SFA).<sup>2-4</sup> These studies uniformly showed the patency advantage of stenting compared to angioplasty alone and ushered in an era in which primary stent implantation became the standard of care for many operators, and patients

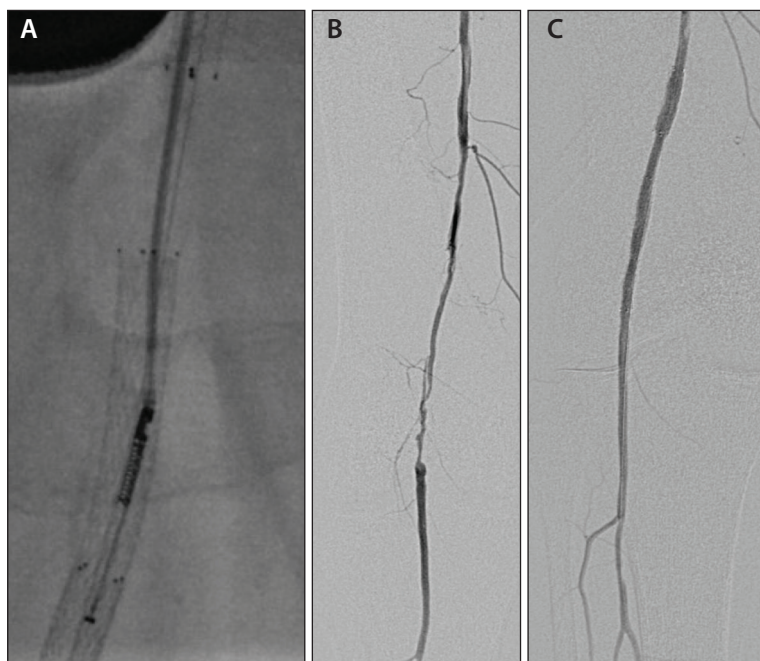
were routinely being treated with “full metal jackets” of the femoropopliteal circulation (Figure 1).

## DISADVANTAGES OF STENT IMPLANTATION IN FEMOROPOPLITEAL ARTERIES

Despite the patency advantage of stent use compared to balloon angioplasty alone, we have come to recognize important limitations of using stents, especially for long-segment femoropopliteal stenting. Due to the mechanical forces seen in the femoropopliteal segment, stent fractures of standard nitinol stents have been



**Figure 1. Full metal jacket of the SFA.**



**Figure 2.** Directional atherectomy for ISR (A), which is contraindicated according to the device instructions for use, but can be used to achieve significant lumen gain by debulking and removing large amounts of intimal hyperplastic tissue, as can be seen in the pretreatment (B) and posttreatment (C) images.

ubiquitous in clinical trials, and multiple authors have shown the deleterious impact of stent fractures on patency rates.<sup>5</sup> Even disregarding stent fractures, intimal hyperplasia development inside nitinol stents leading to restenotic lesions or occlusions has been the Achilles heel of this therapy, and operators have recognized how challenging the treatment of in-stent restenosis (ISR) can be.

Entering and crossing a completely occluded stent can be difficult due to the often convex proximal cap, which can interfere with catheter and wire access to the proximal aspect of the stent. Occluded stents often contain a large amount of friable thrombotic debris, making treatment prone to embolization issues. Finally, even the successful treatment of ISR (or occlusions) is wrought with extremely poor 12-month patency rates, with most strategies not involving antirestenotic drug therapy, and patients with ISR frequently requiring repeated interventions at short intervals.

Not only do permanent implants pose problems for retreatment of femoropopliteal arteries, but there is evidence that the chronic outward radial forces exerted by standard nitinol stents may be contributing to inflammation and serve as a trigger for restenosis. Experimental models have shown that the rate and degree of ISR are

proportional to the degree of oversizing of the stent relative to the vessel, and thus stents may be acting as causative factors in ISR.<sup>6</sup> This has led to increased interest in the use of interwoven nitinol stents due to the minimal outward radial force exerted by these devices, despite their markedly improved crush resistance.

### CAN WE AVOID STENTS IN THE “LEAVE NOTHING BEHIND” ERA?

The advent of drug-coated balloon (DCB) technology as a primary treatment for de novo femoropopliteal lesions has reinvigorated interest in treating the femoropopliteal circulation without the use of permanent implants, a strategy generally employed by proponents of atherectomy. Three DCB platforms are now available for use in the United States, and these devices have been reliably shown to outperform percutaneous transluminal angioplasty (PTA) in randomized investigational device exemption studies, with 12-month primary patency results ranging from 75% to 85%, results that are typically seen only with stent use.<sup>7-9</sup> Additionally, these results have

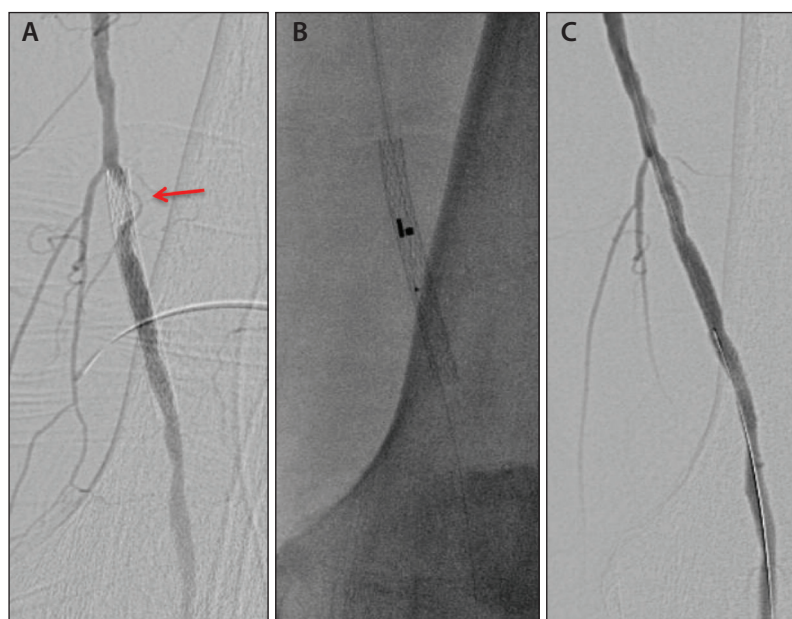
been achieved with surprisingly low bailout stent rates of 3% to 7%, suggesting that these new drug-eluting modalities may relegate stents to a treatment algorithm of the past.

However, these randomized trials have focused on highly selected lesions of low complexity, and several large registries have demonstrated that the need for stent placement remains as lesion complexity increases (ie, increasing length and degree of calcification).<sup>10,11</sup> For example, in the IN.PACT Global registry imaging cohorts, bailout stent rates as high as 47% were seen. These data suggest that permanent implants will continue to play a necessary role in the treatment of femoropopliteal disease and avoidance of stenting altogether is less ideal than judicious use of spot stenting with next-generation scaffolds, such as interwoven stents or newer drug-eluting stent technology. Although DCBs and newer scaffold designs may reduce the problem of ISR moving forward, there is little doubt that interventionalists will continue to struggle with this clinical conundrum.

### OPTIONS FOR TREATING ISR

#### PTA Alone

Prior to the availability of drug-eluting technologies, the primary treatment for ISR consisted of PTA. This strategy has long been recognized as an inadequate long-



**Figure 3.** Focal high-grade ISR (arrow) (A) treated with excimer laser atherectomy using the Turbo-Elite laser catheter with Turbo-Tandem attachment (B). Posttreatment angiogram showing resolution of the in-stent lesion (C).

term solution, as patients with extensive ISR treated with angioplasty alone have generally required frequent reinterventions for recurrent loss of patency. The reasons for this are multifactorial, but the biggest challenge is probably the fact that the intimal hyperplastic tissue is not removed but simply compressed, and this likely leads to transient displacement of extracellular water, which rapidly returns after intervention.

### Atherectomy

Considering the early lumen loss seen with PTA, a logical strategy for ISR is the use of atherectomy to debulk the intimal hyperplastic tissue and improve lumen gain compared to angioplasty alone (Figure 2).

Various devices have been utilized for this purpose, but the most rigorously studied has been laser atherectomy with the Turbo-Elite laser (Philips) (Figure 3). In the EXCITE-ISR trial, treatment of ISR or occlusions was randomized between atherectomy with the Turbo-Elite laser versus PTA alone in a multicenter fashion across the United States.<sup>12</sup> Study enrollment was stopped early at 250 patients due to a significant efficacy advantage at 6 months in the laser atherectomy arm, with freedom from target lesion revascularization (TLR) of 73.5% compared to 51.8% for angioplasty alone ( $P < .005$ ), representing a 52% reduction in TLR. Despite this advantage of laser atherectomy compared to PTA, primary patency rates at 12 months remained suboptimal in both arms based on Kaplan-Meier patency curves, which suggested primary patency rates of approximately 40%

versus 20% for atherectomy and angioplasty, respectively, although the actual values are not reported in the article.

### Combination Therapy With Atherectomy and DCBs

A limitation of atherectomy for ISR is that its use in isolation fails to appreciate the biologic basis of ISR or employ current devices specifically designed to address this biologic etiology. Vessels with ISR have demonstrated an aggressive biologic response to the implant, and several platforms for antirestenotic drug therapy are now available for use in these vessels. The potential advantage of adding antirestenotic therapy to debulking with laser atherectomy was demonstrated in a small single-center randomized trial of

**TABLE 1. RANDOMIZED TRIALS OF DCBs VERSUS PTA FOR THE TREATMENT OF ISR**

Trial	Year	DCB (Manufacturer)	N		Lesion Length (cm)		Patency (Freedom From ISR)		Freedom From TLR	
			DCB	PTA	DCB	PTA	DCB	PTA	DCB	PTA
PACUBA <sup>14</sup>	2016	Freeway (Eurocor GmbH)	35	38	17.3	18.4	33.3%	10.4%	49.0%	22.1%
DEBATE-ISR <sup>15</sup>	2016	In.Pact Admiral (Medtronic)	44	42	13.2	13.7	80.5%	28.2%	86.4%	69.0%
FAIR <sup>16</sup>	2015	In.Pact Admiral (Medtronic)	62	57	8.2	8.1	70.5%	37.5%	90.8%	52.6%

Abbreviations: DCB, drug-coated balloon; ISR, in-stent restenosis; PTA, percutaneous transluminal angioplasty; TLR, target lesion revascularization.

48 patients with in-stent occlusions who were assigned to either laser atherectomy plus Freeway DCB (Eurocor GmbH) or Freeway DCB alone.<sup>13</sup> This small trial demonstrated a 12-month primary patency advantage with the combination therapy compared to DCB angioplasty alone, with rates of 66.7% and 37.5%, respectively.

### DCBs as Stand-Alone Therapy

Despite the intuitively advantageous strategy of combining the debulking properties of atherectomy catheters with the antirestenotic effects of DCBs, perhaps the best results thus far for ISR have been achieved with modern-generation DCBs by themselves. There is a reasonable collection of data to support this practice, as several DCB platforms have been evaluated for use in ISR in randomized trials and well-conducted clinical registries (Table 1).<sup>14-16</sup>

The PACUBA trial involving the Freeway DCB by no means showed exceptional results in terms of 12-month primary patency (in this 73-patient trial, primary patency was only 33.3% for the DCB arm vs 10.4% for the plain balloon arm), but there was nevertheless an advantage for the DCB.<sup>14</sup> More promising results were seen in the DEBATE-ISR trial and the FAIR trial, two studies using the In.Pact Admiral DCB (Medtronic). The DEBATE-ISR trial randomized 86 patients with ISR to DCB angioplasty or PTA and found a dramatic improvement in patency for those treated with the drug-coated technology, with 12-month primary patency rates of 80.5% and 28.2%, respectively.<sup>15</sup> Similarly, the FAIR trial randomized 119 patients to DCB versus PTA and found superior primary patency at 12 months in the DCB group, with rates of 70.5% versus 37.5%, respectively.<sup>16</sup> The 12-month patency rates in the DCB arms in each of these trials far exceed those seen in the EXCITE-ISR trial or rates historically seen with the use of angioplasty for this difficult problem.

Further evidence on the benefit of DCB technology for the treatment of ISR comes from the IN.PACT Global registry ISR cohort, which had trial rigor comparable to the IN.PACT SFA randomized trial and included core lab adjudication of clinically relevant endpoints, including duplex-determined primary patency and freedom from TLR at 12 months.<sup>17</sup> A total of 131 patients with de novo ISR were treated with the In.Pact Admiral DCB, with a mean lesion length of 17.2 cm and 34% incidence of total occlusion. Primary patency at 12 months was an impressive 88.7%, with a clinically driven TLR rate of only 7.3%.

### Covered Stents

Another strategy for the treatment of ISR is to prevent repeated ingrowth of intimal hyperplastic tissue into the

stent through the use of long, self-expanding covered stent grafts. These grafts have an occlusive polytetrafluoroethylene membrane that fully excludes components of the vessel wall, including smooth muscle cells and other restenotic agents, from entering the newly restored lumen. Several studies suggest that stent grafts may perform well in long lesions, as patency rates are relatively independent of lesion length. The RELINE trial evaluated covered stents specifically for use in ISR.<sup>18</sup> In this multicenter study, 83 patients with Rutherford class 2 to 5 ischemia and ISR were randomized to treatment with the heparin-bonded Viabahn endoprosthesis (Gore & Associates) or standard balloon angioplasty. The covered stent group fared better than those treated with balloon angioplasty alone, with 12-month primary patency rates of 74.8% for the Viabahn group and 28% for the angioplasty group ( $P < .001$ ).

Recognized limitations of using covered stents for arterial occlusive disease include the loss of collaterals and potential for acute ischemia upon stent graft thrombosis and the fact that although the graft material prevents tissue ingrowth throughout the body of the stent graft, "edge" stenosis can still occur at the interface between the stent graft and nondiseased vessel.

### Drug-Eluting Stents

Prior to the widespread adoption of DCBs for de novo and restenotic lesions of the femoropopliteal circulation, some have utilized the antirestenotic properties of paclitaxel-coated stents. Zeller and colleagues reported on a prospective series of 108 patients enrolled in the Zilver PTX single-arm study in which Zilver PTX stents (Cook Medical) were used to treat ISR within bare-metal stents.<sup>19</sup> Mean lesion length was 13.3 cm, 31% were total occlusions, and an average of 2.1 stents were placed per lesion. Primary patency at 12 months was 78.8%, and freedom from TLR at 12 and 24 months was 81% and 60.8%, respectively. There was a relatively low stent fracture rate of 1.2%. Although the drug delivery from a paclitaxel-coated stent is likely advantageous in this restenotic setting, most operators would likely agree that antirestenosis treatment with similar efficacy is now feasible with the use of contemporary DCBs without the need for additional permanent implants.

### MANAGING STENT FRACTURES

One of the recognized limitations of standard laser-cut nitinol stents is the propensity of these devices to develop stent fractures. These stents are manufactured by a process in which the stent structure is laser cut from a nitinol tube, and these stents tend to assume this straight tubular structure once deployed. This results

in a relative inability to deal with the forces of torsion, kinking and axial elongation/compression seen in the femoropopliteal circulation, especially at the region of Hunter's canal, and the net result of these forces is a tendency to develop fractures at these locations.

Multiple authors have documented the almost ubiquitous loss of patency of these stents once fractured, likely as a result of encroachment on the lumen by stent fragments or inflammation occurring at these disrupted areas. There is no simple solution, but many operators favor an attempt at repeat stenting to stabilize the fragments and restore lumen. One stent that is particularly well-suited to the forces that are exerted in the distal SFA and proximal popliteal artery is the Supera stent (Abbott Vascular), which has a series of interwoven nitinol wires that are only connected at the ends of the stent. As a result, the stent has significantly improved flexibility and kink resistance, while maintaining a compression resistance that is fourfold greater than standard laser-cut nitinol stents. The effect of these properties was seen in the SUPERB trial, in which there was a 0.3% stent fracture rate at 3 years, as well as numerous other studies that have shown this stent to be impressively fracture resistant.<sup>20</sup> Because of this device's compression resistance and flexibility, it is a logical choice for repeat stenting in the setting of stent fractures and has been routinely used by the author for this purpose. A requirement for successful deployment of the Supera stent within an existing stent is aggressive predilatation (with a short focal balloon that is 1 mm larger than intended Supera's outer diameter) to prevent elongation of the Supera stent.

## CONCLUSION

The use of laser-cut nitinol stents originally designed for the biliary tree has been accepted standard practice until recent years, and this practice was due to the inherent advantages of these stents over PTA alone for femoropopliteal lesions. However, once ISR develops in these implants, retreatment becomes increasingly difficult, and results of intervention for ISR have traditionally been poor. Although the advent of DCBs has increasingly moved operators toward a "leave nothing behind" approach to treating femoropopliteal arteries, highly complex lesions, including those with heavy calcification and longer lengths, will still require scaffolds for optimal outcomes. Hence, there has been a shift toward more focal spot stenting and judicious use of implants when necessary, as well as adoption of more advanced means for treating ISR.

Some of the more advantageous devices for treating ISR include atherectomy and DCB technology, each of which has level 1 evidence to support their use over PTA

alone. The problem of restenosis due to stent fractures is especially difficult to manage and may be best salvaged with repeat stenting with properly deployed interwoven nitinol stents, although data on the results of this technique are lacking. ■

- Schillinger M, Sabeti S, Loewe C, et al. Balloon angioplasty versus implantation of nitinol stents in the superficial femoral artery. *N Engl J Med*. 2006;354:1879-1888.
- Matsumura JS, Yamanouchi D, Goldstein JA, et al. The United States study for evaluating endovascular treatments of lesions in the superficial femoral artery and proximal popliteal by using the Protégé EverFlex nitinol stent system II (DURABILITY II). *J Vasc Surg*. 2013;58:73-83.e1.
- Laird JR, Katzen BT, Scheinert D, et al. Nitinol stent implantation versus balloon angioplasty for lesions in the superficial femoral artery and proximal popliteal artery: twelve-month results from the RESILIENT randomized trial. *Circ Cardiovasc Interv*. 2010;3:267-276.
- Dake MD, Ansel GM, Jaff MR, et al. Durable clinical effectiveness with paclitaxel-eluting stents in the femoropopliteal artery: 5-year results of the Zilver PTX randomized trial. *Circulation*. 2016;133:1472-1483.
- Scheinert D, Scheinert S, Sax J, et al. Prevalence and clinical impact of stent fractures after femoropopliteal stenting. *J Am Coll Cardiol*. 2005;45:312-315.
- Zhao HQ, Nikanorov A, Virmani R, et al. Late stent expansion and neointimal proliferation of oversized nitinol stents in peripheral arteries. *Cardiovasc Intervent Radiol*. 2009;32:720-726.
- Rosenfield K, Jaff MR, White CJ, et al. Trial of a paclitaxel-coated balloon for femoropopliteal artery disease. *N Engl J Med*. 2015;373:145-153.
- Laird JR, Schneider PA, Tepe G, et al. Durability of treatment effect using a drug-coated balloon for femoropopliteal lesions: 24-month results of IN.PACT SFA. *J Am Coll Cardiol*. 2015;66:2329-2338.
- Krishnan P, Faries P, Niazi K, et al. Stellarex drug-coated balloon for treatment of femoropopliteal disease: twelve-month outcomes from the randomized ILLUMINATE pivotal and pharmacokinetic studies. *Circulation*. 2017;136:1102-1113.
- Tepe G. Results of the IN.PACT Global CTO imaging cohort. Presented at Charing Cross 2016; April 26-29, 2016; London, United Kingdom.
- Scheinert D. 12-month results from the IN.PACT Global long lesion cohort. Presented at EuroPCR 2015; May 19-22, 2015; Paris, France.
- Dippel EJ, Makam P, Kovach R, et al. Randomized controlled study of excimer laser atherectomy for treatment of femoropopliteal in-stent restenosis: initial results from the EXCITE ISR trial (Excimer Laser Randomized Controlled Study for Treatment of Femoropopliteal In-Stent Restenosis). *JACC Cardiovasc Interv*. 2015;8(1 pt A):92-101.
- Gandini R, Del Giudice C, Merolla S, et al. Treatment of chronic SFA in-stent occlusion with combined laser atherectomy and drug-eluting balloon angioplasty in patients with critical limb ischemia: a single-center, prospective, randomized study. *J Endovasc Ther*. 2013;20:805-814.
- Kinstner CM, Lammer J, Willfort-Ehringer A, et al. Paclitaxel-eluting balloon versus standard balloon angioplasty in in-stent restenosis of the superficial femoral and proximal popliteal artery: 1-year results of the PACUBA trial. *JACC Cardiovasc Interv*. 2016;9:1386-1392.
- Grotti S, Liistro F, Angioli P, et al. Paclitaxel-eluting balloon vs standard angioplasty to reduce restenosis in diabetic patients with in-stent restenosis of the superficial femoral and proximal popliteal arteries: three-year results of the DEBATE-ISR study. *J Endovasc Ther*. 2016;23:52-57.
- Krankenbreg H, Tübler T, Ingwersen M, et al. Drug-coated balloon versus standard balloon for superficial femoral artery in-stent restenosis: the randomized Femoral Artery In-stent Restenosis (FAIR) trial. *Circulation*. 2015;132:2230-2236.
- Brodmann M, Keirse K, Scheinert D, et al. Drug-coated balloon treatment for femoropopliteal artery disease: the IN.PACT Global study de novo in-stent restenosis imaging cohort. *JACC Cardiovasc Interv*. 2017;10:2113-2123.
- Bosiers M, Deloose K, Callaert J, et al. Superiority of stent-grafts for in-stent restenosis in the superficial femoral artery: twelve-month results from a multicenter randomized trial. *J Endovasc Ther*. 2015;22:1-10.
- Zeller T, Dake MD, Tepe G, et al. Treatment of femoropopliteal in-stent restenosis with paclitaxel-eluting stents. *JACC Cardiovasc Interv*. 2013;6:274-281.
- Garcia LA, Rosenfield KR, Metzger CD, et al. SUPERB final 3-year outcomes using interwoven nitinol biomimetic Supera stent. *Catheter Cardiovasc Interv*. 2017;89:1259-1267.

## Brian G. DeRubertis, MD, FACS

Associate Professor of Surgery  
Division of Vascular Surgery  
David Geffen School of Medicine at UCLA  
Ronald Reagan UCLA Medical Center  
Los Angeles, California  
bderubertis@mednet.ucla.edu

*Disclosures: Compensated speaker, consultant, proctor, and/or advisory board member for Abbott Vascular, Boston Scientific Corporation, Cook Medical, and Medtronic.*