

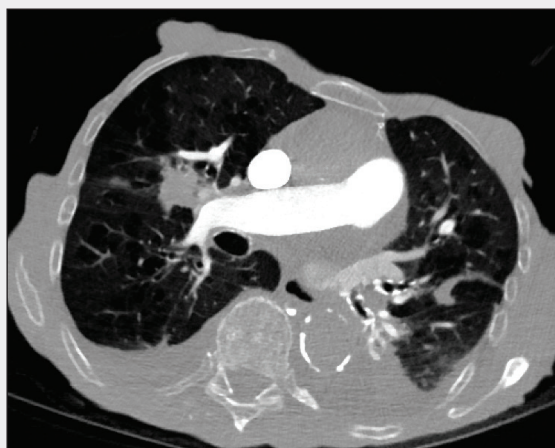

# Lung Ablation

**MODERATORS: DAVID M. LIU, MD, FRCPC, FSIR, AND RIPAL GANDHI, MD, FSVM**

**PANELISTS: KAMRAN AHRAR, MD, MBA; SHARJEEL H. SABIR, MD; ALDA L. TAM, MD; ROBERT SUH, MD; PETER J. LITTRUP, MD; AND DAMIAN E. DUPUY, MD, FACR**

## LESION ADJACENT TO THE PULMONARY ARTERY



**A 64-year-old woman who was a smoker on supplemental oxygen and had chronic obstructive pulmonary disease and pulmonary hypertension presented with a 3.2-cm lesion within the lateral segment of the right middle lobe of the lung. A biopsy confirmed cervical cancer with a metastatic lesion.**

### Would you treat this patient?

**Dr. Suh:** This case should be discussed at the multidisciplinary level and/or by a tumor board. Considerations should include control of the primary disease, length of disease-free interval and indolent tumor progression, extent of intra- and extrathoracic involvement, level of confidence that the proposed therapy can control the disease, and the patient's anticipated ability to tolerate the therapy and other potential treatment options, especially with the given comorbidities. Specific to this case, I would consider this patient for treatment if her cervical carcinoma at the original site of disease were controlled, a reasonable disease-free interval had elapsed, this site had demonstrated slow growth, and no other sites of disease were seen out-

side of the right middle lobe or in extrathoracic locations. However, I am not confident that a percutaneous form of local therapy could be given at the central location of the tumor due to emphysema, pulmonary hypertension, and the unlikelihood of being able to control this tumor.

#### MD Anderson group (Drs. Ahrar, Sabir, and Tam):

We do not think this patient is a good candidate for ablation based on the evidence of compromised pulmonary reserve combined with the size and central location of this mass. The close proximity of the mass to fairly large-sized bronchi and blood vessels would put this patient at risk for serious adverse events, such as bleeding and bronchopleural fistula.

**Dr. Littrup:** For this patient, I wouldn't want to treat with percutaneous ablation due to the patient's poor health status and higher potential for complications. Comorbidities aside, this case has some good teaching points, if we were to consider central ablation in a patient with better health status. First, I would look carefully through the results of imaging to identify any major abutting bronchus. If seen, bronchoscopy could then exclude transmural tumor penetration. If this was clear, then I would favor cryoablation for its relative preservation of collagenous architecture, thereby hopefully preserving the bronchial integrity to avoid a bronchopleural fistula. However, the location of this mass abutting the main pulmonary artery requires sufficient ablation probe density to deliver cytotoxic thermal temperatures. This also applies to microwave ablation (MWA), if no bronchus is nearby, by making sure MWA applicators are placed closer to the vessel.

For cryoablation, it is important to choose the largest probe size in order to deliver the greatest cooling capacity to surrounding tissues, which is directly proportional to the cryoprobe diameter (ie, a 2.1-mm probe has 40% greater surface area than a 1.5-mm probe, assuming similar freeze power of approximately 25 watts each, but this is likely less for smaller probes, too). Thereby, we always

add at least an additional cryoprobe when using smaller gauges (eg, 1.5/1.7 mm, depending on the manufacturer). Hence, for this 3.2-cm lesion, I would use three 2.1/2.4-mm cryoprobes or four 1.5/1.7-mm cryoprobes.

**Dr. Dupuy:** I would not treat this patient for several reasons. First, the patient's comorbidities of pulmonary hypertension and oxygen dependence makes meaningful survival likely < 1 year. Also, the contiguity to the pulmonary artery makes it unlikely that the entire tumor would be completely destroyed. However, stereotactic body radiation treatment (SBRT) might be a consideration in a palliative setting.

### What preprocedural planning would have to be taken into consideration to treat this lesion?

**MD Anderson group:** If you were to consider treating this patient, pulmonary function tests would be helpful to further assess her risk profile.

**Dr. Suh:** You would need to evaluate the rest of the body to exclude other sites of metastases with whole-body CT or CT/positron emission tomography (PET). The chest should be scanned with contrast in no thicker than 3-mm sections. Sagittal and coronal images must be included as part of the chest CT. This preplanning chest CT should ideally inform the operator as to the full extent of the targeted tumor, as well as the location of large arteries, veins, bronchi, other regional anatomy, and hopefully potential sites to place applicators to access the tumor through a percutaneous route.

**Dr. Littrup:** This patient likely has poor pulmonary function that would go below our 30:30 minimal safety limits for diffusing capacity of the lungs for carbon monoxide (DLCO) and fraction of inspired oxygen (FIO<sub>2</sub>). Our pulmonologists have suggested that these patients may never get off of the ventilator if either general anesthesia is chosen or subsequent intubation is needed. Moreover, any pneumothorax or reactive effusion may further compromise the patient's tenuous pulmonary status. As also noted, excluding transmural tumor penetration bronchoscopy has prevented significant bronchopleural fistula in our experience, even when cryoablating near major bronchi.

### What ablation modality would you use to treat this patient?

**Dr. Suh:** I would not favor thermal ablation in this case given the relatively large tumor size (> 3 cm); its

locoregional anatomic involvement of the superior pulmonary veins, segmental and larger arteries, and bronchi; and overall close proximity and possible extension into the right interlobar nodal space and into the right upper and right lower lobes given its contact with both right minor and major fissures. These considerations reduce the likelihood for complete treatment. I am not confident that I could find a safe access for applicators to avoid vital anatomic structures and to place applicators in strategic points to create a continuous ablation zone to encapsulate the targeted tumor.

**MD Anderson group:** We would recommend a consult with radiation oncology for potential radiation treatment.

**Dr. Littrup:** I think SBRT would be possible for this patient or cryoablation for a similar anatomic case with better health status, as noted.

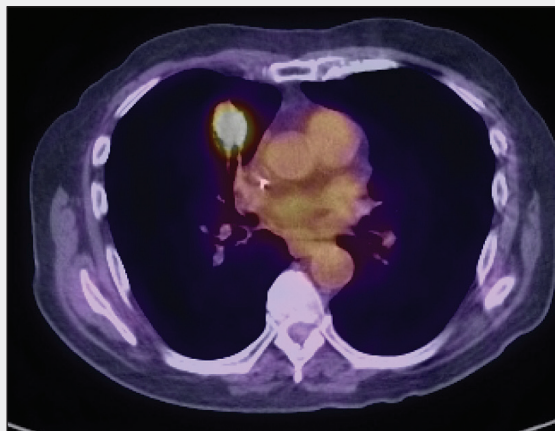
### Would there be any special considerations during the course of the procedure?

**Dr. Littrup:** For lung cryoablation, we always use a triple freeze technique, which may be particularly effective near major vessels, as the purpose of any refreeze is to further reduce the probability of residual neoplasm that may have survived. Prior in vitro tests on freeze microscopes have nicely demonstrated that two freezes to -10° C are comparable to a single freeze to -40° C. Even if the standard cytotoxic temperature of < -20° C is not fully reached throughout the tumor, the two additional freezes will likely achieve this. As noted from animal work, the first short 2- to 3-minute freeze changes the peritumoral air to fluid (eg, edema/blood) for better thermal conductivity, whereas the two longer following freezes deliver the lethal temperatures throughout the tumor. This also does not increase overall procedure time when using three freeze:thaw cycles of 3:2 minutes, sculpting to tumor size for 5–10:4–6 minutes, and then a short final freeze of usually 4 to 7 minutes.

**Dr. Suh:** If a percutaneous approach was used, both the risk of pneumothorax and hemorrhage into emphysematous lung, especially with pulmonary hypertension, would be leading concerns. Given the risks, some operators may favor general anesthesia.

**MD Anderson group:** We typically perform lung ablations under general anesthesia, and a double-lumen endotracheal tube may be of benefit in this case. If there is significant bleeding, the double-lumen tube provides the opportunity to protect the left lung.

## LESION NEAR THE PERICARDIUM



**This axial fusion PET/CT scan demonstrates a 3.5-cm lesion in the medial segment of the right middle lobe, adjacent to the pericardium and the hilar structures.**

### What ablation modality would you use and why?

**Dr. Suh:** This is a difficult question to answer on the basis of a single axial image. If bronchovascular planes were cephalad and caudad to this image, and applicator tips could be placed deep to the central margin of the tumor in its long axis, cryoablation might be feasible by placing three large cryoprobes (one lateral to the midsection of the tumor at this level and the other two immediately superior and inferior to the tumor shading medially). MWA could be considered if an applicator could be placed along the long axis of the tumor and its tip and live shaft away from the segmental arteries and bronchi by approximately 1 cm. This would allow one to heat the margins of these critical structures without placing the antenna directly onto these structures.

**Dr. Littrup:** Cryoablation would be an excellent choice because the lesion also appears to be near bronchus leading up to the PET-positive mass. The “stick” function of cryoablation allows a manual retractor-like ability to easily move the mass away from the heart surface. That may not be necessary in this case; even cryoprobes bracketing the mass near its medial edge would likely have little irritative effect upon the pericardium (transmural freezing of the left atrium is now being successfully pursued with new endovascular cryotechnology for treatment of atrial fibrillation). Cryoablation is generally very safe near the heart and myocardium, but we use the retractor-like function to avoid the large heat sink

of the beating heart, when safely possible, to ensure the most thorough lung mass ablations.

**MD Anderson group:** We would use cryoablation given the proximity of the mass to the bronchus.

**Dr. Dupuy:** I would treat this lesion with a combination of ablation plus radiotherapy. I would prefer heat-based modalities such as MWA.

### What approach would you use, and would you use any adjunctive measures to protect the pericardium?

**MD Anderson group:** We would take an anterior approach to the mass, place the probes, and then create a pneumothorax to move the lung away from the pericardium to minimize the risk of injury to the phrenic nerve.

**Dr. Suh:** All applicators would be placed along the long axis of the tumor to best conform ablation geometries to the tumor shape, thereby effectively reducing the needed total diameter of ablation. For the most part, the applicator should be placed 10 mm away from the pericardium. If necessary, cryoprobes can be used to “stick” the tumor and lever it away from the pericardium if anticipated ablation geometry predicted significant ice formation inside the pericardium. With MWA, the bulk (longer ablation time) of the ablation should be performed above, lateral, and below the tumor. In order to provide a medial margin, the antenna can be placed medially with a significantly shorter ablation time.

**Dr. Littrup:** This 3.5-cm mass would likely benefit from four 2.1/2.4-mm cryoprobes, bracketing the upper and lower aspects of the mass using our “1-2 rule” (ie, cryoprobes spaced no more than 1 cm from tumor margins and < 2 cm apart). Again, we generally try to use the most powerful cryoprobes and have not seen any greater pneumothorax or complication rate compared with the 1.5/1.7-mm cryoprobes. If those smaller probes are preferred (we add cryoprobe[s] to ensure thorough cell death), it doesn’t take much more time when all are rapidly deployed in parallel. For this case, an anterior approach also takes advantage of the long axis of the tumor. Finally, we would likely use some mild retraction with the stuck cryoprobes upon initiation of the freeze to mainly avoid the heat sink, as previously noted.

**Dr. Dupuy:** I would not worry about the heart, as the lesion is not close enough to be of concern.

## What technique do you use to induce an iatrogenic pneumothorax?

**MD Anderson group:** We would use a 18-gauge Hawkins needle (comes with both a sharp and blunt stylet) to enter the pleural space and deliver carbon dioxide.

**Dr. Suh:** If needed, a Veress needle (a spring-loaded needle to create pneumothorax or pneumoperitoneum during laparoscopy) can be ideally used. Once close to the pleural space, a small amount of air or fluid can be injected. After CT confirmation, a three-way stopcock connected to the access needle, air or fluid source, and a syringe of reasonable size can be used to expand the pleural space and to displace the lung accordingly. The

access needle can be exchanged for a small-bore catheter if potential thermal conduction exists.

**Dr. Littrup:** We use plenty of lidocaine right at the pleural surface, which helps create a fluid space within the lung. A 5-F, straight, multiholed catheter (eg, Yueh [Cook Medical]) then slides in nicely within the pleural space.

**Dr. Dupuy:** If I needed to perform iatrogenic pneumothorax, I would use the technique that we have previously described<sup>1</sup> with a spring-loaded needle, thoracocentesis set, and a 6-F drainage catheter to introduce air. ■

1. Solomon SB, Thornton RH, Dupuy DE, Downey RJ. Protection of the mediastinum and chest wall with an artificial pneumothorax during lung ablations. *J Vasc Interv Radiol.* 2008;19:610-615.

### MODERATORS:

#### David M. Liu, MD, FRCPC, FSIR

Vancouver Imaging  
Clinical Associate Professor  
Faculty of Medicine  
University of British Columbia  
Vancouver, British Columbia, Canada  
*Disclosures:* Consultant to Sirtex Medical and BTG.

#### Ripal Gandhi, MD, FSVM

Miami Cardiac and Vascular Institute  
Associate Clinical Professor  
FIU Herbert Wertheim College of Medicine  
Miami, Florida  
*Disclosures:* None.

### PANELISTS:

#### Kamran Ahrar, MD, MBA

Professor  
Department of Interventional Radiology  
MD Anderson Cancer Center  
Houston, Texas  
*Disclosures:* None.

#### Sharjeel H. Sabir, MD

Assistant Professor  
Department of Interventional Radiology  
MD Anderson Cancer Center  
Houston, Texas  
*Disclosures:* Received compensation for travel to educational courses, Neuwave Medical and Boston Scientific.

#### Alda L. Tam, MD

Associate Professor  
Department of Interventional Radiology  
MD Anderson Cancer Center  
Houston, Texas  
*Disclosures:* Research grant from AngioDynamics, Inc.; medical monitor for Galil Medical.

#### Robert Suh, MD

Clinical Professor, Radiological Sciences  
David Geffen School of Medicine at UCLA  
Director, Thoracic Interventional Services  
Ronald Reagan UCLA Medical Center  
Los Angeles, California  
*Disclosures:* Contracted research, Galil Medical and Healthtronics; research grant, Healthtronics; cryoablation training course, Healthtronics; consultant, Neuwave Medical.

#### Peter J. Littrup, MD

Professor, Diagnostic Imaging  
Rhode Island Hospital  
Department of Diagnostic Imaging  
The Warren Alpert Medical School of Brown University  
Providence, Rhode Island  
*Disclosures:* Research grants, Galil Medical and Healthtronics/Endocare.

#### Damian E. Dupuy, MD, FACR

Director, Tumor Ablation  
Rhode Island Hospital  
Professor Diagnostic Imaging  
The Warren Alpert Medical School of Brown University  
Providence, Rhode Island  
*Disclosures:* Board of Directors for Perseon Medical; grant support from Galil Medical, Neuwave Medical, Medtronic; royalties from UptoDate, Springer Verlag.