

# Endovascular Management of Traumatic Vertebral Artery Dissections

Treatment options in cases when anticoagulation is not a good solution and the risk of stroke is high.

BY JOSÉ E. COHEN, MD; SHIFRA FRAIFELD, MBA; AND EYAL ITSHAYEK, MD

**T**raumatic vertebral artery (VA) dissection is a relatively uncommon but well-recognized sequelae of cervical trauma, with potentially life-threatening implications. VA dissection can occur as a result of different trauma types that cause excessive cervical rotation, distraction, or flexion-extension injuries. Extracranial components of the VAs have a higher likelihood of dissecting; however, up to 10% of extracranial VA dissections extend intracranially. Intracranial dissections can complicate with subarachnoid hemorrhage and present a poorer outcome.<sup>1,2</sup>

Early and accurate diagnosis of traumatic VA dissections, before stroke occurs, is essential to starting the most appropriate treatment. The widespread use of CT angiography (CTA) in trauma patient screening has improved our ability to detect VA injuries;<sup>3,4</sup> however, an early and precise clinical and radiological diagnosis of VA dissection can still be challenging in trauma patients, mainly due to confounding clinical factors and technical limitations.

To date, there are very few reports on endovascular repair of VA dissections, suggesting that medical therapy is the most commonly indicated therapy and that the endovascular approach is generally either not required or is underused. There are no guidelines for the selection of patients who will benefit most from this procedure. This article focuses on our institutional indications for endo-

---

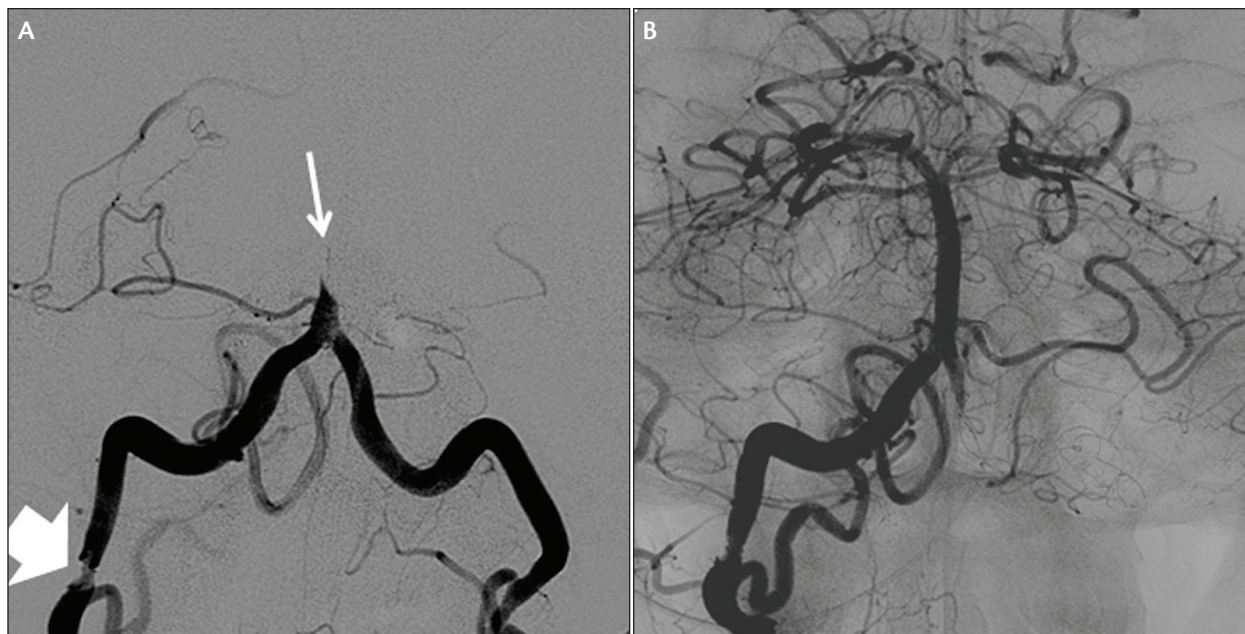
Early and accurate diagnosis of traumatic VA dissections, before stroke occurs, is essential to starting the most appropriate treatment. The widespread use of CT angiography in trauma patient screening has improved our ability to detect VA injuries.

---

vascular management of traumatic VA dissections and the considerations for choosing different endovascular strategies.

## LIMITATIONS TO ANTICOAGULATION

Approaches to the management of traumatic VA dissection have developed based on clinical experience with internal carotid artery (ICA) dissections. In cases of spontaneous ICA dissection, anticoagulant treatment is usually recommended to prevent thromboembolic stroke originating from the injured vessel wall<sup>5,6</sup>; however, anticoagulation is not innocuous and may be contraindicated, especially in patients with multiple traumatic injuries.



**Figure 1.** A middle-aged man was involved in a car accident and sustained cervical trauma, thoracic injuries, and fracture of multiple limbs. Upon arrival at the emergency department, he developed quadriplegia and coma. He was urgently intubated. Head CTA reconstruction revealed bilateral distal VA dissections and basilar artery occlusion, requiring an emergent intracranial revascularization procedure (A). Selective right VA angiogram confirmed a V3 dissection (thick arrow) with basilar artery occlusion (thin arrow). Stent-based thrombectomy allowed complete recanalization of the basilar artery (B). A balloon-expandable stent was immediately placed at the complex V3 dissection. The patient regained consciousness after the endovascular procedure and recovered motor strength of all four limbs. After 6 months, the patient achieved complete neurological recovery.

Furthermore, anticoagulation and antiplatelet therapy do not improve compromised perfusion, which may develop secondary to arterial narrowing and lead to hemodynamic insufficiency, or cases complicated with major acute life-threatening injury or embolic events.<sup>7,8</sup> Thus, in selected patients with traumatic supra-aortic dissections, endovascular approaches are considered a valuable management option. Stenting allows immediate VA revascularization, reducing the incidence of embolic and hemodynamic stroke without the need for full anticoagulation, and may be combined with other endovascular procedures (eg, thrombectomy, angioplasty, deliberate arterial occlusion, infusion of different agents) based on a specific patient's requirements.

#### ANGIOGRAPHIC ASSESSMENT AND PATIENT SELECTION FOR ENDOVASCULAR THERAPY

Patients admitted to the emergency department for head, neck, or multiple traumatic injuries are primarily evaluated with noncontrast head and neck CT, based on our institutional protocols and in accordance with accepted screening guidelines. CTA is routinely performed in patients with suspected neurovascular injury,

including all patients with cervical spine injuries. Catheter-based contrast angiography of the cervical and cerebral vessels is performed in cases of penetrating neck injuries or in situations in which neurovascular injury is suspected or proven on CTA; in cases of acute focal neurological signs that are in apparent contradiction to presentation on posttrauma CT, including cases of normal CTA; and in patients presenting with lower cranial nerve neuropathy or Horner's syndrome. When there is no contraindication, anticoagulation is administered to all patients with traumatic ICA or VA dissection.

The clinical and radiographic criteria used in recently published studies<sup>7,8</sup> to determine whether VA dissection patients were candidates for endovascular management include:

(1) Major contraindication for anticoagulation, usually due to the presence of traumatic intracranial hemorrhagic lesions, a large brain infarction, multisystemic hemorrhagic injuries, or the need for surgical or invasive procedures.

(2) Impending risk of stroke based on analysis of dissection severity, type, and location, as well as evaluation of both vertebral arteries and assessment of the presence

and collateral blood flow via the posterior communicating arteries (PComAs). At the high end of the risk continuum would be a patient presenting with a hemodynamically significant dissection, string sign, or acute occlusion in a dominant or sole VA, without PComAs, especially in the presence of fluctuating neurological status. Patients at high risk of stroke should be considered for urgent endovascular reconstruction.

(3) Clinical failure of anticoagulation. Patients who continue to suffer from repetitive transient ischemic attack (TIA), neurological instability, and/or neurological deterioration despite anticoagulation are regarded as nonresponders who are at high risk for stroke.

(4) Ischemic stroke secondary to VA dissection with indication for emergent intracranial revascularization procedure. Patients who are candidates for emergent intracranial revascularization procedures are considered for combined intra- and extracranial revascularization (Figure 1).

### PREPROCEDURAL CLINICAL ASSESSMENT

Routine trauma evaluations, full evaluation to rule out or identify hemorrhagic injuries, and assessment of the cervical spine are mandatory. VA dissections occur most frequently at the V2 segment but may also occur in other locations or extend to more than one segment. They may occur in a dominant or hypoplastic artery, in patients with or without a complete circle of Willis, and in patients with or without rich collaterals. Evaluation of the vascular status and potential collateral supply (and thus the vascular reserve) is of paramount importance to guide therapeutic options and define procedural risks.

Due to the many confounding variables that affect the neurological status of patients with traumatic injuries, stroke evaluation with traditional scales is usually inaccurate. A posterior circulation ischemic event may present with a wide variety of syndromes. Neurological dysfunction may include hemi- or quadriparesis, deficits in cranial nerves III to XII, respiratory difficulty, altered sensorium, vertigo, and/or ataxia. Multiple cranial nerve signs indicate involvement of more than one brainstem level. Patients may present with only hemiparesis, but this may progress rapidly to quadriparesis or a locked-in syndrome.

Clinical suspicion associated with a CTA diagnosis of VA dissection and the detection of a corresponding ischemic lesion on advanced brain imaging (diffusion MR studies) have been the diagnostic basis for therapy. Therapeutic strategies include anticoagulation, revascularization techniques (stent-assisted arterial reconstruction), and endovascular permanent arterial occlusion. When endovascular approaches are indicated, we prefer to use revascularization techniques, especially when dealing

with dominant arteries or patients with limited collateral status. Permanent arterial occlusion was considered only in the case of severely injured hypoplastic vessels, where injuries did not involve the PICA origin, and in patients with an absolute contraindication for antiaggregation therapy.

### ENDOVASCULAR PROCEDURE AND TECHNICAL CONSIDERATIONS

Every patient with a suspected diagnosis of VA dissection based on CTA findings is taken to the endovascular suite for diagnostic cervical and cerebral angiography and eventual endovascular treatment when warranted. Local anesthesia, conscious sedation, or general anesthesia may be used depending on the patient's clinical status and level of cooperation. A 4-F introducer sheath is placed in the right femoral artery, and a selective bilateral subclavian-VA artery, common carotid artery, ICA, and external carotid artery angiographic study—including extracranial and intracranial circulation—is performed. Every lesion is analyzed in multiple angiographic positions and graded based on the aforementioned criteria. Potential working positions are identified in the preliminary diagnostic study. If a VA endovascular procedure is planned, the 4-F femoral introducer sheath is exchanged for a 6-F introducer sheath. Following our protocol, diagnostic angiography is performed under a low dose of heparin (bolus of 1,000 units IV). In cases in which the need for endovascular revascularization is confirmed, the patient receives an additional heparin bolus (70 units/kg) to achieve an intraprocedural activated clotting time of 250 to 270 seconds before the therapeutic procedure commences. Moderate levels of anticoagulation are maintained for the duration of the procedure, and then heparin is discontinued.

A 6-F guiding catheter is placed at the subclavian artery in cases of proximal VA dissection or at the proximal VA when the VA dissection is more distal, and selective angiography is performed. The dissected segment is characterized. Normal arterial diameters, lesion extension, severity of stenosis, and associated lesions are measured with the guiding catheter used as a reference diameter, and an appropriate stent for implantation is selected if stenting was indicated. Severity of stenosis is calculated using the North American Symptomatic Carotid Endarterectomy Trial (NASCET) method.<sup>9</sup> Unsubtracted images are often very useful at this stage to provide bone references for more precise stent deployment.

The narrowed arterial segment is crossed under road mapping with a 2.3-F microcatheter over a 0.014-inch, 300-cm-long exchange microguidewire. When the microcatheter has fully crossed the dissected segment, adequate positioning of the microcatheter in the true

lumen is confirmed with a 1-mL contrast injection. The microcatheter is then exchanged for the stent delivery catheter, and one or more stents are deployed to fully cover the VA dissection.

Only premounted balloon-expandable stents (Promus coronary stent, Boston Scientific; Codman system, Codman Neuro) are used for dissections localized to the V1 segment, while either self-expanding microstents (Wingspan, Stryker Neurovascular; Leo stent, Balt Therapeutics; Solitaire AB, Covidien) or balloon-expandable stents are used in the V2 and V3 segments, based on the neurointerventionist's preference. The aim of stenting is to cover the injured arterial segment and improve the arterial diameter. Poststenting residual arterial stenosis of < 30% is considered a good result. Immediately after stenting, heparin is discontinued, and patients receive a loading dose of 300 mg aspirin and 300 mg clopidogrel orally or per nasogastric tube. Oral clopidogrel (75 mg) and aspirin (100 mg) are prescribed once a day for 4 to 6 weeks; aspirin is continued indefinitely. Patients who undergo implantation of regular neurostents, those considered at high risk for hemorrhage, and those who must undergo a surgical procedure receive aspirin with or without a reduced course of clopidogrel.

Low-porosity stents or flow diverters, such as the Pipeline embolization device (PED, Covidien), are used in cases with high embolic potential or in cases with associated pseudoaneurysm. Due to the increased risk of stent thrombosis, PED implantation is always preceded by administration of antiplatelet agents, and the antiplatelet effect is evaluated. These patients are premedicated with a loading dose of 300 to 600 mg of clopidogrel (based on the duration of the premedication; the shorter the premedication period, the higher the loading dose), followed by 75 mg daily. In addition, all patients receive 300 mg of aspirin daily. Thrombocyte inhibition levels are confirmed with the VerifyNow P2Y12 assay (Accriva Diagnostics, representing ITC and Accumetrics) and a standard thrombocyte aggregation test. Patients are treated only if the thrombocyte inhibition level is > 30%; if the response is lower and without resistance, additional loading doses or increased daily doses (eg, 150 mg daily) are administered. If clopidogrel resistance is detected, clopidogrel is discontinued, and ticlopidine is administered at a dose of 600 mg twice daily.

Antiplatelet medications are transiently discontinued when indicated for mandatory surgical or other invasive procedures. Neurological and neuroradiological examinations are performed at discharge and at 1-, 3-, and 12-month follow-up. Stent patency is assessed by CT angiography or formal angiography at 3 and 12 months.

---

Anticoagulation is the most commonly used therapy for VA dissection. It is generally accepted that anticoagulation is effective in preventing stroke and presents an acceptable safety profile in patients without increased risk of hemorrhage.

---

### THE HADASSAH EXPERIENCE

We present our indications for angiographic evaluation of trauma patients with suspected supra-aortic trunk traumatic injuries, and criteria for identifying patients who are candidates for endovascular management of traumatic VA dissections based on our experience and the scarce reports available in the literature. In addition, we present the preprocedural work-up and steps of the endovascular procedure in our center.

Anticoagulation is the most commonly used therapy for VA dissection. It is generally accepted that anticoagulation is effective in preventing stroke and presents an acceptable safety profile in patients without increased risk of hemorrhage. However, the indications for anticoagulation in a multitrauma patient can be complex, and treatment should never be taken without balancing risks. Existing evidence on the optimal treatment of traumatic VA dissections is limited and can only guide the general practice to identify patients who are candidates for anticoagulation with acceptable risks for hemorrhagic complications, or who could be managed with alternative antithrombotic prophylaxis if formal anticoagulation is contraindicated. Although it is difficult to prove, antiplatelets alone are considered less effective but are thought to be generally safer in terms of hemorrhagic complications, in comparison with anticoagulation. The logic behind endovascular revascularization is to reduce the risk of ischemic stroke while gaining the more acceptable risk profile for hemorrhage and the contraindications associated with antiplatelets.

From 2004 to 2014, out of a series of 46 patients with traumatic VA dissection, 18 patients presenting with 24 traumatic VA dissections met inclusion criteria for endovascular therapy. A total of 19 dissections were managed with VA stenting as the primary treatment modality, including stent-assisted reconstruction or diverter implantation. Three dissections were treated with deliberate arterial occlusion using detachable coils, two patients required

emergent intracranial revascularization procedures, and one required endovascular embolization of an associated vertebral arteriovenous fistula. We have found this management approach to be safe and not associated with an increased rate of complications. In general, our experience coincides with most reports that stenting extracranial dissections is safe, and associated with a stable or improved neurological outcome.

In 2011, Pham et al<sup>10</sup> published a thorough review of the recent literature on endovascular management of carotid and VA dissections. They assessed eight reports describing the management of 10 patients and 12 dissected vessels. Etiology of the dissections was traumatic (60%, 6/10), spontaneous (20%, 2/10), and iatrogenic (20%, 2/10). There was a 100% technical success rate. The mean angiographic follow-up period was 7.5 months (range, 2–12 months). No new neurological events were reported during a mean clinical follow-up period of 26.4 months (range, 3–55 months).

It is our impression that stenting supra-aortic dissections has become a routine procedure in most neurocatheterization laboratories, and we were surprised by the small number of patients that this complete review gathered, considering the fact that advanced vertebral stenting has been performed for more than a decade.

## NEW PERSPECTIVES

In the coming years, it will be crucial for us to define appropriate therapy for traumatic vertebral artery dissections: which patients should receive anticoagulation, who should receive antiplatelet therapy and for how long, who should be stented, and which stents should be used. Therapy will have to effectively prevent stroke with minimal additional morbidity in patients who may be suffering from traumatic injuries, and it will have to allow immediate additional surgical or invasive procedures with minimal restraints when required. Advances in endovascular therapies have led us to consider the endovascular alternative for patients who meet specific criteria of increased risk for stroke. This approach has allowed controlled and predictable restoration of the distorted, damaged anatomy in patients with VA dissection, reducing the early risk of stroke and allowing us to continue with surgical plans with acceptable limitations. We have also been able to eliminate long-term anticoagulation, with its limitations and undesired risk of hemorrhagic complications. Based on our experience, we are convinced that stenting is a continuously evolving field with a definite place in the management of supra-aortic dissections. Prospective randomized trials compared with medical management are needed to further elucidate the role of endovascular revascularization. ■

*José E. Cohen, MD, is Professor of Neurosurgery and Chief, Division of Endovascular Neurosurgery, Hadassah–Hebrew University Medical Center, Jerusalem, Israel. He stated that he has no financial interests related to this article. Dr. Cohen may be reached at +972-2-677-7091; jcohen@yahoo.com.*

*Shifra Fraifeld, MBA, is a senior medical writer and research associate, Hadassah–Hebrew University Medical Center, Jerusalem, Israel. She stated that she has no financial interests related to this article.*

*Eyal Itshayek, MD, is a senior neurosurgeon, Department of Neurosurgery, Hadassah–Hebrew University Medical Center, Jerusalem, Israel. He has disclosed that he is the recipient of research support from MFast, an Israeli distributor of a wide variety of medical devices.*

1. Schievink WI, Mokri B, O'Fallon WM. Recurrent spontaneous cervical-artery dissection. *N Engl J Med*. 1994;330:393–397.
2. Metso TM, Metso AJ, Helenius J, et al. Prognosis and safety of anticoagulation in intracranial artery dissections in adults. *Stroke*. 2007;38:1837–1842.
3. Fleck SK, Langner S, Baldauf J, et al. Blunt craniocervical artery injury in cervical spine lesions: the value of CT angiography. *Acta Neurochir (Wien)*. 2010;152:1679–1686.
4. Lum C, Chakraborty S, Schlossmacher M, et al. Vertebral artery dissection with a normal-appearing lumen at multisection CT angiography: the importance of identifying wall hematoma. *AJNR Am J Neuroradiol*. 2009;30:787–792.
5. Lucas C, Moulin T, Deplanque D, et al. Stroke patterns of internal carotid artery dissection in 40 patients. *Stroke*. 1998;29:2646–2648.
6. Schievink WI. Spontaneous dissection of the carotid and vertebral arteries. *N Engl J Med*. 2001;344:898–906.
7. Cohen JE, Leker RR, Gotkine M, et al. Emergent stenting to treat patients with carotid artery dissection: clinically and radiologically directed therapeutic decision making. *Stroke*. 2003;34:e254–257.
8. Cohen JE, Ben-Hur T, Rajz G, et al. Endovascular stent-assisted angioplasty in the management of traumatic internal carotid artery dissections. *Stroke*. 2005;36:e45–47.
9. Fox AJ. How to measure carotid stenosis. *Radiology*. 1993;186:316–318.
10. Pham MH, Rahme RJ, Amaout O, et al. Endovascular stenting of extracranial carotid and vertebral artery dissections: a systematic review of the literature. *Neurosurgery*. 2011;68:856–866.