

Sponsored by Endologix, Inc.

Bringing PEVAR Into Mainstream Aortic Aneurysm Repair

Critical factors for success: the importance of device attributes and physician experience.

BY NIKHAL KANSAL, MD, FACS, AND ZVONIMIR KRAJCIER, MD, FACC

AUTHORS



Nikhal Kansal, MD, FACS, is Chief of Vascular and Endovascular Surgery, St. Elizabeth's Medical Center in Boston, Massachusetts, and Director, Vascular Surgery Services, Steward Health Care System. He has disclosed that he is a paid speaker for Endologix, Inc.



Zvonimir Krajci, MD, FACC, is Director, Peripheral Intervention, St. Luke's Episcopal Hospital Texas Heart Institute in Houston, Texas. He has disclosed that he is a paid speaker for Endologix, Inc. and Abbott Vascular.

"Maintaining the minimal invasiveness of the percutaneous approach to aortic endografting reduces patient discomfort and permits earlier ambulation and hospital discharge. Initial success seems to be maintained at 1 month; however, longer follow-up will be required ..."

Haas PC et al.¹

Such were the conclusions of the first report to describe an initial experience with percutaneous endovascular aneurysm repair (PEVAR), facilitated with an adjunctive preclose technique, which was published 14 years ago.¹ Since then, there have been close to 50 peer-reviewed publications showing improved success rates over time, ranging from 46% in the early experience to 98% in recent years.^{2,3} Clinical outcomes of interest have evolved from pure feasibility to quantifying specific attributes—procedure time,^{4,5} anesthesia time,⁶ length of hospital stay,⁷ and patient-specific outcomes, including blood loss,⁸ time to ambulation,⁹ and post-

operative pain. All of this led to increased physician adoption.

To further validate these important trends, we participated in the first—and so far, the only—prospective, multicenter, randomized controlled trial comparing PEVAR to traditional surgical endovascular aneurysm repair sponsored by Endologix, Inc. (Irvine, CA) with collaboration from Abbott Vascular (Santa Clara, CA). Results from the randomized trial are in the process of being published, whereas data from the roll-in phase of this trial were previously published¹⁰ and demonstrated a 97% technical success rate with the preclose procedure. All endovascular repairs were successful, and no mortality or major adverse events occurred. On the basis of the PEVAR trial, the US Food and Drug Administration granted expanded labeling for the Endologix endograft system, with specific indications for PEVAR use (including a bilateral percutaneous approach), and for the Perclose ProGlide® Suture-Mediated Closure System (Abbott Vascular) for closure of access sites using 5- to 21-F sheaths.

As with all clinical evidence, it is important to discuss the generalizability of these findings to broad clinical practice, particularly in regard to the EVAR device selection and patient selection. The PEVAR trial was conducted with a single endograft system with a 19-F ipsilateral introducer sheath, currently reduced to 17 F with the AFX® Endovascular AAA System (Endologix, Inc.). Unique to commercially available endografts, the AFX bifurcated components feature a precannulated contralateral limb, eliminating the need for additional contralateral components and associated gate cannulation in the vast majority of the cases. The delivery of the AFX system is supported by a 9-F contralateral sheath, as compared to 14- to 22-F contralateral arteriotomies customary with traditional modular devices (Figure 1).

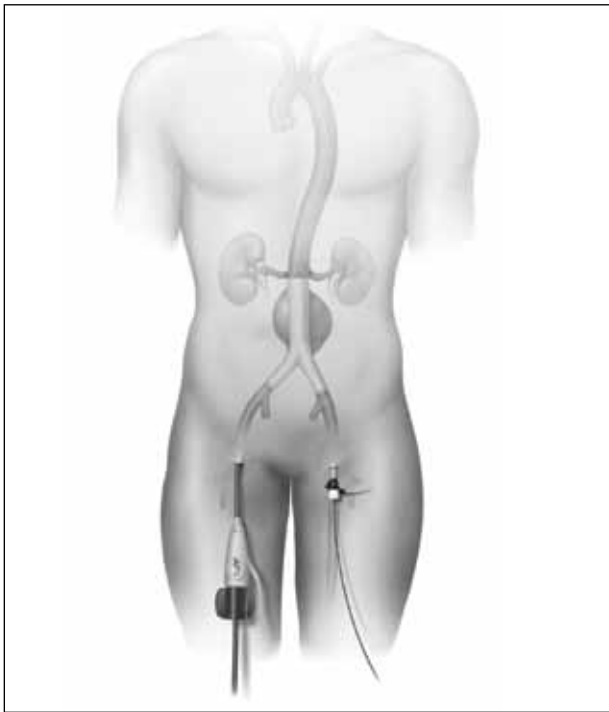


Figure 1. PEVAR with a 17-F AFX® ipsilateral and 9-F contralateral sheath.

The sheath-based design avoids multiple exchanges directly across the femoral artery with a lower-profile access, which is important for achieving technical success in PEVAR procedures; this has been described before and is fully supported by our own clinical experiences.¹¹ There are a number of technical options for closure of the arterial puncture from the 9-F sheath, and the AFX instructions for use are open in that regard.

Finally, the ability of the AFX device to preserve the native bifurcation to enable “up-and-over” procedures for post-EVAR peripheral interventions is well documented. In the context of PEVAR, the ability to access the contralateral iliac and femoral arteries for angiography or balloon occlusion, when necessary, is very useful (Figure 2).

PATIENT SELECTION FOR PEVAR

Beyond device selection, patient eligibility for PEVAR is of major clinical importance. The patient’s degree of common femoral artery calcification (Figure 3), obesity, and female gender have been reported as common risk factors for PEVAR failure. Appropriate femoral artery anatomy, including adequate vessel size for access, is important and, in the case of smaller access vessels, cannot be offset by reducing the access profile.¹¹

... the learning curve can be significantly shortened with focused training instruction and support from the EVAR and suture-mediated closure device manufacturers.

But overall, with dedicated training in proper patient selection and careful application of specific access and closure techniques, the benefits of PEVAR can likely be extended to the majority of abdominal aortic aneurysm (AAA) patients undergoing endovascular repair.

PEER-TO-PEER PEVAR TRAINING

As with all other surgical and interventional techniques, PEVAR is associated with potential clinical complications, ranging from local hematomas to retroperitoneal bleeding to distal thrombosis. The learning curve in PEVAR is directly associated with effective use of the suture-mediated closure device in a preclose technique. Recently published studies have highlighted the relationship between physician experience and PEVAR outcomes, such as increased rates of technical success¹² and a reduced rate of conversion to surgical cutdown.¹³ A learning curve of as many as 30 cases has been suggested as a requirement to achieve 90% technical success,¹² given that until recently, no formal training in PEVAR has been performed due to the “off-label” nature of the procedures.

The authors have been performing PEVAR procedures for many years and believe that the learning curve can be significantly shortened with focused training instruction and support from the EVAR and suture-mediated closure device manufacturers.

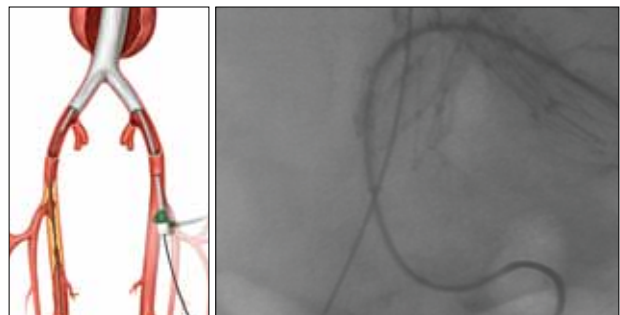


Figure 2. Up-and-over access across a native bifurcation.

Sponsored by Endologix, Inc.

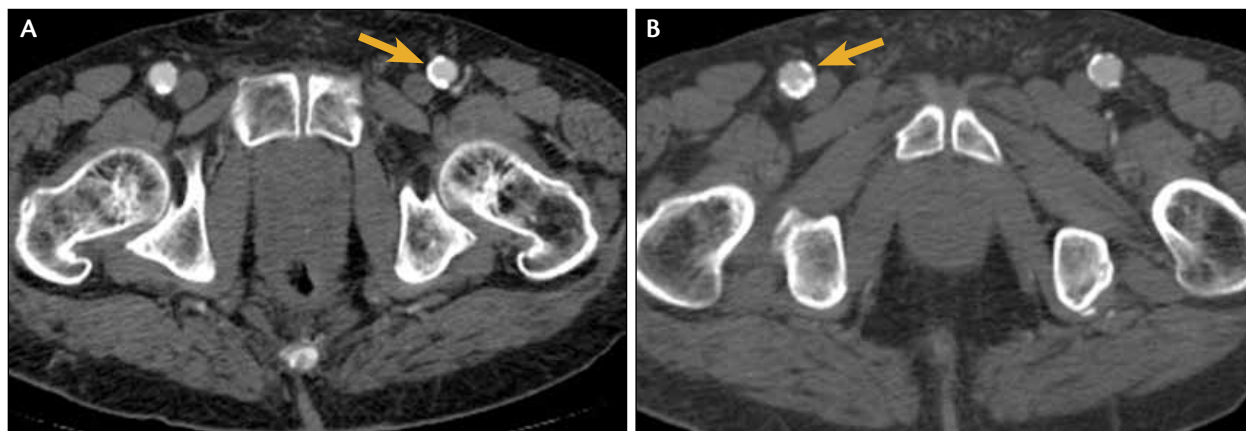


Figure 3. Preoperative CT imaging is useful to assess the location and degree of common femoral artery calcification.

With specific PEVAR labeling granted to its endograft platform, Endologix supports on-label, physician-proctored PEVAR training at approximately 20 certified centers across the United States. Such training is essential to properly introduce and adopt this new technique into daily clinical practice (see the *Benefits of the PEVAR Physician's Education Course* sidebar).

As part of the faculty, we recommend this level of instruction and interaction to endovascular practitioners interested in incorporating percutaneous access and closure into their existing EVAR practice, so that they may understand the technique, see it in action during case observations, and work on simulated devices to become familiar with the technique before they incorporate it into their routine clinical practice. Furthermore, these courses emphasize the opportunity for multispecialty collaboration among surgeons and interventionists new to PEVAR to leverage expertise and resources across an institution.

BENEFITS OF THE PEVAR PHYSICIAN'S EDUCATION COURSE

- Interactive learning with renowned, certified faculty
- Didactic training, including patient selection and manufacturers' instructions for use
- Hands-on experience with the AFX® Endovascular AAA System and Perclose ProGlide® Suture-Mediated Closure Device
- Best practices and troubleshooting techniques
- Live case observation

For more information on PEVAR training courses, visit www.PEVARphysicians.com.

CONCLUSION

At the present time, less than half of EVAR cases are performed percutaneously for a variety of reasons, such as past uncertainty over outcomes, patient eligibility, lack of formal training with the technique, and liability concerns on the part of physicians with off-label procedures. With the availability of the specific approved labeling for the AFX and ProGlide devices and the coordinated training program based on the PEVAR trial now in place, those concerns are being alleviated. Endovascular specialists will be well advised to assess their practice and to consider extending the benefits of PEVAR to all eligible AAA patients in their practice. ■

1. Haas PC, Krajcer Z, Diethrich EB. Closure of large percutaneous access sites using the Prostar XL percutaneous vascular surgery device. *J Endovasc Surg.* 1999;6:168-170.
2. Traul DK, Clair DG, Gray B, et al. Percutaneous endovascular repair of infrarenal abdominal aortic aneurysms: a feasibility study. *J Vasc Surg.* 2000;32:770-776.
3. Krajcer Z, Gregoric I. Totally percutaneous aortic aneurysm repair: methods and outcomes using the fully integrated IntuiTrak endovascular system. *J Cardiovasc Surg (Torino).* 2010;51:493-501.
4. Lee WA, Brown MP, Nelson PR, Huber TS. Total percutaneous access for endovascular aortic aneurysm repair ("Preclose" technique). *J Vasc Surg.* 2007;45:1095-1101.
5. Bensley RP, Hurks R, Huang Z, et al. Ultrasound-guided percutaneous endovascular aneurysm repair success is predicted by access vessel diameter. *J Vasc Surg.* 2012;55:1554-1561.
6. Morasch MD, Kibbe MR, Evans ME, et al. Percutaneous repair of abdominal aortic aneurysm. *J Vasc Surg.* 2004;40:12-16.
7. Grenon SM, Gagnon J, Hsiang YN, Chen JC. Canadian experience with percutaneous endovascular aneurysm repair: short-term outcomes. *Can J Surg.* 2009;52:E156-160.
8. Torsello GB, Kasprzak B, Klenk E, et al. Endovascular suture versus cutdown for endovascular aneurysm repair: a prospective randomized pilot study. *J Vasc Surg.* 2003;38:78-82.
9. Haulon S, Hassen Khodja R, Proudfoot CW, Samuels E. A systematic literature review of the efficacy and safety of the Prostar XL device for the closure of large femoral arterial access sites in patients undergoing percutaneous endovascular aortic procedures. *Eur J Vasc Endovasc Surg.* 2011;41:201-213.
10. Krajcer Z, Nelson P, Bianchi C, et al. Percutaneous endovascular abdominal aortic aneurysm repair: methods and initial outcomes from the first prospective, multicenter trial. *J Cardiovasc Surg (Torino).* 2011;52:651-659.
11. Georgiadis GS, Antoniou GA, Papaioakim M, et al. A meta-analysis of outcome after percutaneous endovascular aortic aneurysm repair using different size sheaths or endograft delivery systems. *J Endovasc Ther.* 2011;18:445-459.
12. Mousa AY, Campbell JE, Broce M, et al. Predictors of percutaneous access failure requiring open femoral surgical conversion during endovascular aortic aneurysm repair. *J Vasc Surg.* In press.
13. Bechara CF, Barshes NR, Pisisimis G, et al. Predicting the learning curve and failures of total percutaneous endovascular aortic aneurysm repair. *J Vasc Surg.* 2013;57:72-76.