

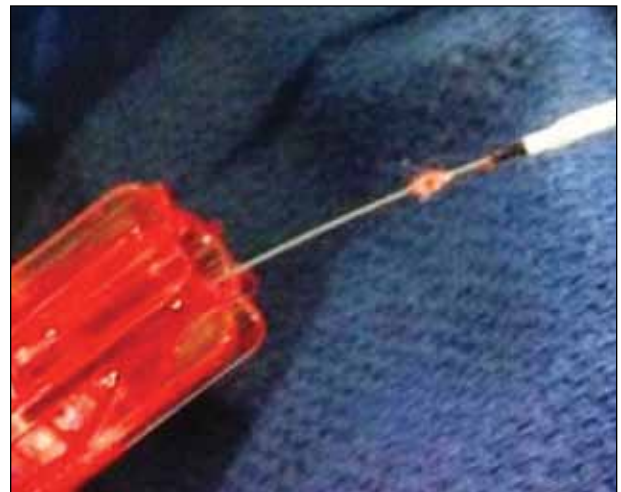Foreign Body Contamination During Interventional Procedures

An underrecognized factor that can cause catastrophic complications.

BY JOHN R. LAIRD, MD; NICK CAVROS, MD, FACC; ROBERT GALLINO, MD; DANIEL McCORMICK, DO, FACC, FSCAI; KELLY W. ELLIOTT, RN, MS; AND MARSHA HOLTON, CCRN, RCIS, FSICP

Foreign body contamination is an underappreciated cause of complications during interventional procedures. Defined as the introduction of materials not intended to enter the body, foreign body contamination can result in benign changes, severe complications, and, in some circumstances, even death.¹⁻⁴ These materials, ranging from microscopic ($< 100 \mu\text{m}$) to visible ($> 100 \mu\text{m}$) particles and fibers, can originate from fabrics or materials commonly used during interventional procedures. Published light microscopy bench studies, postmortem histological analyses, preclinical studies, and clinical case reviews have demonstrated the prevalence of these foreign bodies and the potential effect of foreign body contamination on clinical outcomes.

A common material used in the sterile field during diagnostic and interventional procedures, and a documented source of foreign body contamination, is cotton. Gauze-based pads, sponges, nonadherent pads, surgical towels, and drapes are examples of medical supplies that are composed of cotton. Gauze is a light, thin, loosely woven fabric commonly made of cotton or a synthetic fiber and has been used as a medical fabric for more than 95 years.⁵ Gauze is highly absorbent, making it an ideal material for absorbing bodily fluids or applying ointments or medications to wounds. Gauze 4- X 4-inch sponges are the most commonly employed product in the cardiac catheterization laboratory for wiping catheters and guidewires and for absorbing blood. Unfortunately, the loosely woven



(courtesy of Nick Cavros, MD)

Figure 1. Cotton gauze fibers adhered to a guidewire between the tip of a balloon catheter and the Tuohy-Borst valve.

structure of gauze combined with cotton's fibrous nature makes it susceptible to fiber shedding and/or separation of the woven structure.

Mechanical operations, such as cleaning or wiping of a catheter or guidewire, may further disrupt the fiber structure and shed particulate or cotton fiber. This interaction can result in the transfer of particulate debris to these devices and then into the patient. Figure 1 shows

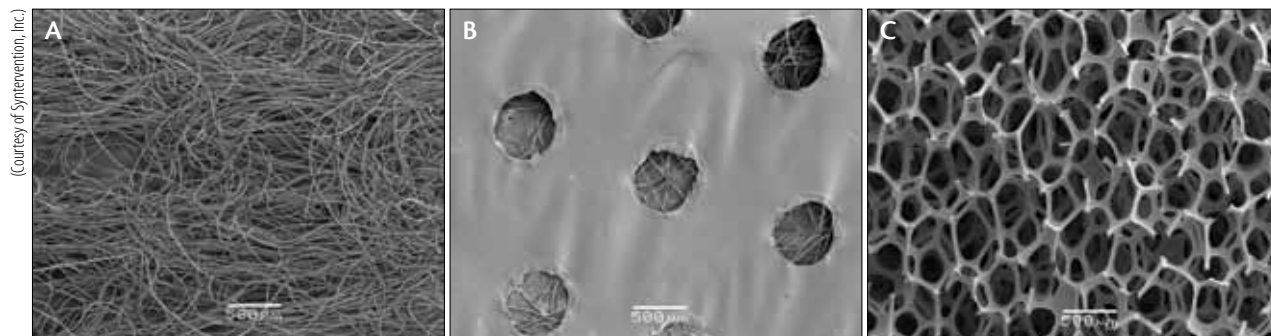


Figure 2. Electron microscope magnification of gauze (A), Telfa (B), and the Swiper (C) at 30 times their size.

a commonly observed occurrence of a guidewire contaminated with cotton fibers. Because these fibers are typically small, detection is difficult, and in many cases, the risk of inadvertently introducing them into the patient is high. This may be an even more common problem with the use of hydrophilic guidewires during peripheral vascular interventions. When hydrophilic guidewires dry out, they become especially tacky and are susceptible to the accumulation of adherent cotton fibers.

Due to concerns of fiber shedding during interventional procedures, many interventional labs have transitioned to using nonadherent pads (eg, Telfa pads) to wipe down medical devices during the procedure. A nonadherent pad is a gauze pad covered with a perforated plastic membrane (Figure 2). The original intent of the plastic membrane was to prevent the pad from sticking to wounds; however, it has been proposed that this structure may limit particulate shedding on devices during procedures.⁶ The hypothesis is not supported by the particulate test results that will be discussed later in this review.

Nonadherent pads are not sealed within the membrane, containing both perforations and unsealed edges where particulates and fibers from the gauze can escape. Furthermore, the absorption and cleaning proper-

ties of the nonadherent pad are greatly reduced due to the fact that the primary surface contacting the medical instrument is a nonabsorbent plastic membrane.

FOREIGN BODY REACTIONS

The most commonly reported reaction to cotton fibers is the granulomatous reaction.⁷⁻¹⁵ An early example of a granulomatous reaction after foreign body contamination was reported by Heath et al after a lung tissue and pulmonary artery biopsy.⁹ At the time of repair of a patent ductus arteriosus in a 49-year-old woman, abnormal tissue was noted in the lung and the pulmonary artery. The authors reported that, most likely, cotton and wool fibers were inadvertently injected into the patient's circulation during previous diagnostic cardiac procedures. The granulomatous reaction diagnosed on biopsy examination led to a change in practice regarding how the institution stored catheters used for angiographic procedures.

Another consequence of foreign body contamination is thrombus formation.^{1-4,10,16} Cotton fibers can cause local hypercoagulability. In an experimental model to assess coagulation in a setting relevant to angiographic procedures, Bookstein et al found that after wiping a guidewire and finding gauze powder or gauze lint, there was a marked acceleration of clotting within the catheter as measured by the activated clotting time.¹⁷ Fischl et al reported a case of a patient who experienced chest pain after a diagnostic catheterization and procedure to assess fractional flow reserve in the left anterior descending (LAD) artery.² The result of the fractional flow reserve study was negative; however, after leaving the cardiac catheterization lab, the patient developed refractory chest pain and returned to the lab for further assessment. A filling defect was noted in the LAD, and aspiration thrombectomy was performed. The aspirate contained a thrombotic cotton gauze fragment measuring approximately 1.5 cm in length. The authors report that the gauze fragment was inad-

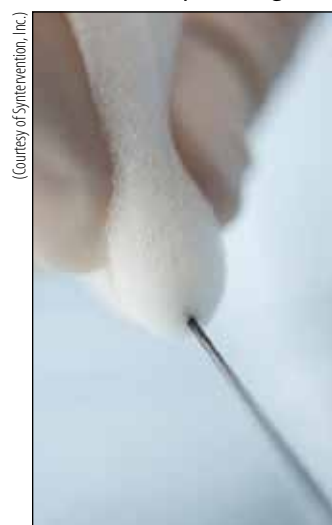

Figure 3. The Swiper in use shown wiping a guidewire. Note that this is used the same way as the currently used materials in the interventional lab (eg, gauze and nonadherent dressings).

TABLE 1. PARTICLE COUNTS FOR GAUZE, TELFA, AND THE SWIPER

Average Particle Count per 80 mL Fluid Volume				
Product	≥ 10 µm	≥ 25 µm	≥ 50 µm	≥ 100 µm
Gauze (n = 5)	29,809 ^a	937 ^a	8	0
Telfa (n = 5)	27,884 ^a	2,401 ^a	111 ^a	15 ^a
Swiper (n = 5)	6,692	70	2	0

^aDenotes particle count significantly greater than the Swiper.

vertently injected during the diagnostic catheterization, and it migrated to the mid-LAD. The cause of this incident was identified as the use of the same sterile saline receptacle to both hydrate gauze sponges and for a saline flush injection into the patient. Presumably, a gauze fragment released from the gauze pad during hydration was inadvertently drawn into a syringe and injected into the patient's coronary circulation during the procedure. Based on this experience, the authors strongly recommended that the saline flush solution be kept in a separate receptacle to avoid contamination from gauze fragments.

Furthermore, Shannon et al reported the prevalence of cotton fiber embolization during cerebral angiography.⁴ A 5-year retrospective study was performed on all available postmortem cases to systematically assess the prevalence of embolization of particulates in patients who suffered from arteriovenous malformations. Particulate embolization, which was primarily cotton fiber, was present in 25% of the cases. The cotton fiber emboli were found to be mixed with thrombus. In a few instances, the foreign particulate emboli produced catastrophic results.

An additional possible complication that can arise from foreign body contamination is a pyrogenic reaction.^{18,19} A pyrogenic reaction can take place due to the particulate's propensity to attract bacteria from the air. The particulate then adheres to the medical device, and subsequently, the bacteria can be introduced into the patient. In addition to the foreign bodies carrying bacteria and being the possible source of a pyrogenic reaction, Elek et al described how the presence of foreign particles in and of themselves reduces resistance to infection.¹⁸

OPPORTUNITIES FOR IMPROVEMENT

Technical fabrics and materials designed for cleaning critical surfaces and devices have been around since the 1960s in the electronic, medical device manufacturing, and pharmaceutical industries. There is a wide variety

available depending on the application, including woven and nonwoven fabrics made from cotton and synthetic materials, as well as absorbent foam—typically urethane and polyvinyl alcohol.²⁰ These products undergo special laundry processes to remove lint, fiber, and particulate and must meet strict specifications for particulate and residue levels and absorbency. The Swiper foam wiper (Syntervention, Inc., Rocky Mount, NC) is one of the first of these products that is provided in sterile form for medical procedures. The Swiper is a sterile, biocompatible, fiber-free foam wiper designed for the removal of blood, contrast, and other contaminants from sterile instruments and medical devices (Figure 3).

PARTICULATE COUNT TESTING: A COMPARISON OF THREE MATERIALS

Light obscuration particle testing was performed to better understand the prevalence of particulate shedding resulting from products commonly used for cleaning medical devices during percutaneous procedures compared with the Swiper.²¹ Products tested included gauze 4- X 4-inch sponges, Telfa nonadherent pads, and the Swiper (Figure 2).

Testing Methodology

An independent microbiology testing laboratory (Nelson Laboratories, Salt Lake City, UT) conducted the testing. In a controlled environment, using clean gloves and clean technique, each product underwent testing using the following methodology. Individual samples were hydrated separately in filtered water (80 mL) and squeezed under water three times. The product remained in the water for 2 minutes, the absorbed water was squeezed back into a bowl, and the product was discarded. A sample of the water was aspirated and injected into a light obscuration particulate counter. Particles measuring ≥ 10, 25, 50, and 100 µm in size were counted for each of the product brands and for each of the individual samples.

Results

The average particle count was lower for the Swiper in all categories (Table 1). Differences were statistically significant ($P < .05$) in the ≥ 10 - and 25- μm size ranges for gauze and Telfa and the ≥ 50 - and 100- μm size ranges for the Telfa, compared to the Swiper. No particles $> 100 \mu\text{m}$ were seen with the Swiper or gauze; however, Telfa averaged 15 particles per 80-mL fluid volume.

Limitations

This study is limited by the relatively small number of devices tested and the inherent shortcomings of this in vitro model. Nevertheless, it highlights the potential for gauze to shed particulate debris and the surprising lack of benefit of Telfa relative to gauze.

DISCUSSION

Medical device manufacturers are required to follow strict quality system regulations as mandated by the US Food and Drug Administration.²² Once sterile medical devices are opened for use in the sterile field, they are exposed to a number of elements during a procedure. The requirements met to market the device no longer benefit the patient when the device is exposed to foreign body contaminants in the operating room or interventional lab. Cotton fiber can be inadvertently introduced into a patient's vasculature and may cause serious clinical complications such as pyrogenic reactions, granulomatous reactions, particulate deposition, thrombosis, and thromboembolization. Fiber-free materials are an important and desirable advance that offers the promise of reduced microscopic foreign body contamination during interventional procedures. ■

John R. Laird, MD, is Professor of Medicine and Medical Director, UC Davis Vascular Center in Davis, California. He has disclosed that he is a member of the Medical Advisory Board for Syntervention, Inc. Dr. Laird may be reached at (916) 734-2028; john.laird@ucdmc.ucdavis.edu.

Nick Cavros, MD, FACC, is with Cardiovascular Institute of the South, and is Co-Director, Cardiac Catheterization Laboratories, Lafayette General Medical Center in Lafayette, Louisiana. He has disclosed that he is a member of the Medical Advisory Board for Syntervention, Inc. Dr. Cavros may be reached at (337) 289-8429; ncavros@gmail.com.

Robert Gallino, MD, is Director of Peripheral Vascular Interventions, Medstar Montgomery Medical Center in Olney, Maryland. He has disclosed that he is a member of the Medical Advisory Board for Syntervention, Inc. Dr. Gallino may be reached at (301) 774-1323; robgallino@gmail.com.

Daniel McCormick, DO, FACC, FSCAI is Director, Cardiovascular Interventional Therapy, Pennsylvania

Hospital, University of Pennsylvania Healthcare System in Philadelphia, Pennsylvania. He has disclosed that he is a member of the Medical Advisory Board for Syntervention, Inc. Dr. McCormick may be reached at (215) 762-7776; dandoc49@aol.com.

Kelly W. Elliott, RN, MS, is President and CEO, Eminence Clinical Research, Inc., in Monument, Colorado. She has disclosed that she is a member of the Medical Advisory Board for Syntervention, Inc. Ms. Elliott may be reached at (720) 425-0528; kelliott@eminenceclinicalresearch.com.

Marsha Holton, CCRN, RCIS, FSICP, is President and Founder, Cardiovascular Orientation Programs in Indian Head, Maryland. She has disclosed that she is a member of the Medical Advisory Board for Syntervention, Inc. Ms. Holton may be reached at (301) 643-4427; marshasicp@aol.com.

1. Dimmick JE, Bove KE, McAdams AJ, Benzing III G. Fiber embolization—a hazard of cardiac surgery and catheterization. *Med Intel.* 1975;292:685-687.
2. Fischl M, Narins CR. Coronary embolization of a gauze fragment: a cautionary case report. *Catheter Cardio Interv.* 2005;66:570-572.
3. Silberman J, Cravioto H, Feigin I. Foreign body emboli following cerebral angiography. *Arch Neurol-Chicago.* 1960;3:119-126.
4. Shannon P, Billbao JM, Marotta T, Terbrugge K. Inadvertent foreign body embolization in diagnostic and therapeutic cerebral angiography. *Am J Neuroradiol.* 2006;27:278-282.
5. Our timeline. Johnson & Johnson website. <http://www.jnj.com/connect/about-jnj/company-history>. Accessed June 30, 2012.
6. Zimmerli W, Low DP, Waldvogel FA. Pathogenesis of foreign body infection: evidence for a local granulocyte defect. *J Clin Invest.* 1984;73:1191-1200.
7. Von Gahn WC, Hall JW, Sun S. Arteritis in guinea pigs, produced by emboli of cotton, resembling the arteritis of hypersensitivity. *Am J Pathol.* 1954;30:1129-1139.
8. Cayton HR, Furness G, Jackson DS, Maitland HB. Studies on cotton dust in relation to byssinosis. *Brit J Ind Med.* 1952;9:303-308.
9. Heath D, Mackinnon J. Case reports: cotton-wool granuloma of pulmonary artery. *Brit Heart J.* 1962;24:518-520.
10. Walley VM, Stinson WA, Upton RT, et al. Foreign materials found in the cardiovascular system after instrumentation or surgery (including a guide to their light microscopic identification). *Cardiovasc Pathol.* 1993;2:157-185.
11. Ramot Y, Amir G, Willenz EP, Nyska A. Foreign body granulomas within intramyocardial arteries in a transcatheter safety assessment in pigs. *Toxicol Pathol.* 2008;36:385-387.
12. Janoff K, Wayne R, Huntwork B, et al. Foreign body reactions secondary to cellulose lint fibers. *Am J Surg.* 1984;147:598-600.
13. Sturdy JH, Baird RM, Gerein AN. Surgical sponges: a cause of granuloma and adhesion formation. *Ann Surg.* 1967;165:128-134.
14. Tinker MA, Teicher I, Burdman D. Cellulose granulomas and their relationship to intestinal obstruction. *Am J Surg.* 1977;133:134-139.
15. Morimoto M, Takahashi M, Sato N, et al. Expansively hemorrhagic foreign body granuloma at the pelvis caused by microscopic materials. *Open J Orthopedics.* 2012;2:1-5.
16. Whelan DM, van Beusekom HMM, van der Giessen WJ. Foreign body contamination during stent implantation. *Catheter Cardio Diag.* 1997;40:328-332.
17. Bookstein JJ, Arun K. Experimental investigation of hypercoagulant conditions associated with angiography. *J Vasc Interv Radiol.* 1995;6:197-204.
18. Elek SD, Conen PE. The virulence of staphylococcus pyogenes for man. A study of the problems of wound infection. *Brit J Exp Pathol.* 1957;38:573-586.
19. Glasgow D, Sommers J. Lint shedding cannot be overlooked. *Clin Services J.* 2003;28-30.
20. Wiper cleanliness chart. Texwipe website. http://www.texwipe.com/files/pdfs/training_materials/wiper-chart0407.pdf. Accessed June 30, 2012.
21. Holton M, Elliott K, Cavros N, et al. Microscopic foreign body contamination. Abstract presented at: New Cardiovascular Horizons 2012; June 9, 2012; New Orleans, LA.
22. US Department of Health & Human Services. CFR - Code of Federal Regulations Title 21. <http://www.access-data.fda.gov/scripts/cdrh/cdof/cfcr/cfsearch.cfm?CFRPart=21CFR820>. Accessed June 24, 2012.