

# Ruptured Descending Aortic Dissection

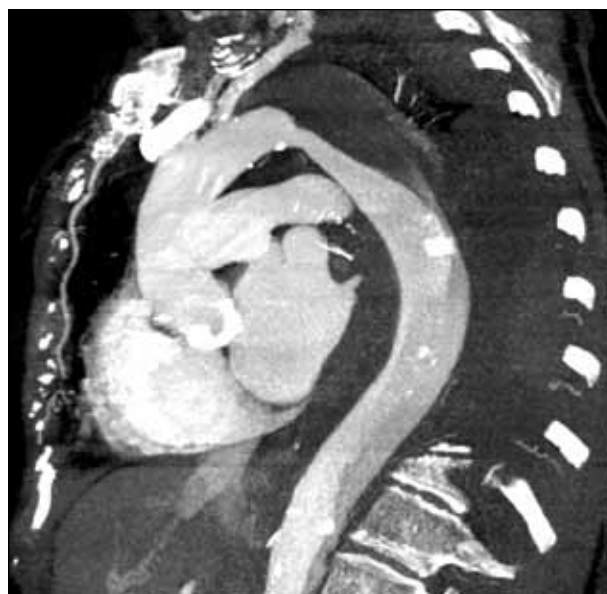An innovative endovascular solution using the chimney TEVAR technique.

**BY FELIX J. V. SCHLÖSSER, MD, PhD; HAMID R. MOJIBIAN, MD;  
AND BART E. MUHS, MD, PhD**

**D**espite its relatively low incidence, aortic dissection is the most frequent cause of acute aortic syndrome and is responsible for a higher annual mortality rate than ruptured abdominal aortic aneurysms.<sup>1</sup> The introduction of thoracic endografts 2 decades ago has dramatically changed the clinical management of patients with descending thoracic aortic disease.<sup>2</sup> The emerging techniques of thoracic endovascular aortic repair (TEVAR) have resulted in less-invasive therapies that provide a safer alternative to the maximally invasive open surgical approach.<sup>3</sup> Clinical evidence and follow-up data have rapidly accumulated in recent years.<sup>4,5</sup>

Increasingly, TEVAR is considered the preferential treatment for patients with complicated type B aortic dissections, including rupture, malperfusion, or acute diameter expansion. Several anatomical characteristics must be met to fulfill strict criteria with the currently available endovascular grafts. To further expand the applicability of endovascular repair, custom-made fenestrated or branched endografts have been applied. These procedures are relatively complex and are only performed in limited centers with such experience. Another limitation is that the custom-made process often takes more than 6 weeks and prevents emergent use of these devices.

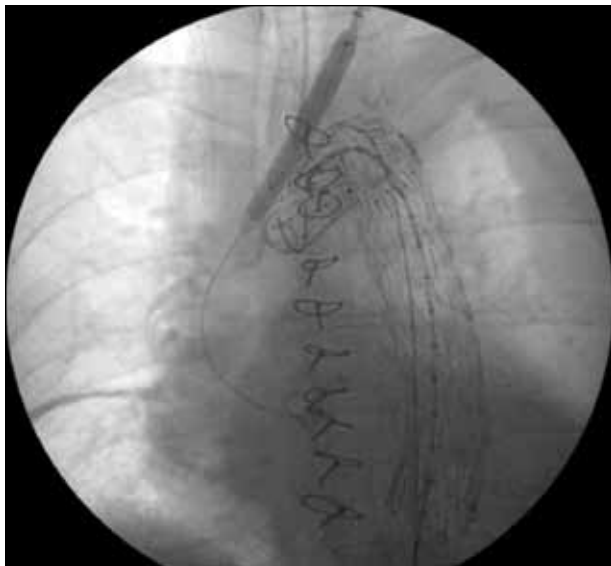An alternative is the “chimney graft” technique, which involves placement of adjunctive stents in side branches of the aorta alongside the main endovascular stent graft.<sup>6,7</sup> In this article, we describe the successful endovascular treatment of a ruptured acute descending aortic dissection with the chimney TEVAR technique.



**Figure 1.** CTA of the chest showing a ruptured type B aortic dissection.

## CASE REPORT

An 85-year-old woman presented with severe back pain. She had a history of hypertension, type 2 diabetes mellitus, atrial fibrillation, deep venous thrombosis, gastrointestinal bleeding, gallstone pancreatitis (treated with cholecystectomy), and severe aortic stenosis (treated with prosthetic aortic valve replacement); she was hemodynamically stable. Shortly after hospital admission, a significant decrease in her hematocrit level was noted. Computed tomographic angiography (CTA) revealed a



**Figure 2.** Intraoperative fluoroscopy shows deployment of a balloon-expandable iCast stent across the ostium of the left common carotid artery and parallel to the Zenith TX2 endoprosthesis.

ruptured Stanford type B aortic dissection with a left-sided hemothorax (Figure 1). Because of her age and comorbidities, she was not an appropriate candidate for open therapy. She was emergently planned for endovascular repair in the operating room.

Shortly after arrival in the operating room, the patient became hypotensive. No spinal drain was placed, as to prevent a delay in the endovascular treatment. The left common femoral artery was surgically exposed for access, and the right common femoral artery was percutaneously accessed. Aortic arch angiography showed the aortic arch and side branches. The proximal neck was very short, and the left common carotid artery and left subclavian artery would need to be covered to achieve an adequate proximal seal. Therefore, the left common carotid artery was accessed percutaneously. A tapered 34- to 30-mm Zenith TX2 endoprosthesis (Cook Medical, Bloomington, IN) was deployed proximally. A second Zenith TX2 endoprosthesis (30 mm in diameter) was deployed distally with adequate overlap between the two aortic endoprostheses. The bottom of the second graft was just above the celiac axis.

To enable adequate blood flow into the left common carotid artery, an 8- X 59-mm balloon-expandable iCast stent (Atrium Medical Corporation, Hudson, NH) was prepositioned over the left common carotid artery guidewire and was deployed simultaneously across the ostium of the left common carotid artery using

the chimney technique (Figure 2). The left common carotid artery stent extended more proximal into the aorta than the proximal Zenith TX2 endoprosthesis. Completion angiography demonstrated successful repair of the ruptured type B aortic dissection. There were no endoleaks, and good anterior flow was noted into the innominate artery and the left common carotid artery. A left chest tube was placed, and the arterial access sites were closed. The patient tolerated the procedure quite well and without any complications. She was brought to the intensive care unit for recovery.

During the subsequent days, she remained hemodynamically stable, gradually improved, and was discharged on postoperative day 6. Six months of follow-up have been completed without any complications (Figures 3 through 5).

## DISCUSSION

This case report describes a patient with a ruptured descending aortic dissection that was successfully treated with the chimney TEVAR procedure. The chimney TEVAR technique was required to create a good proximal seal, which required coverage of the left common carotid artery and left subclavian artery by the aortic stent graft. This chimney TEVAR technique allows exclusion of challenging aortic pathology from blood flow and continued adequate blood flow into the side branches of the aorta that are covered by the aortic endograft. Other advantages are that readily available stents can be used and that the technique provides an

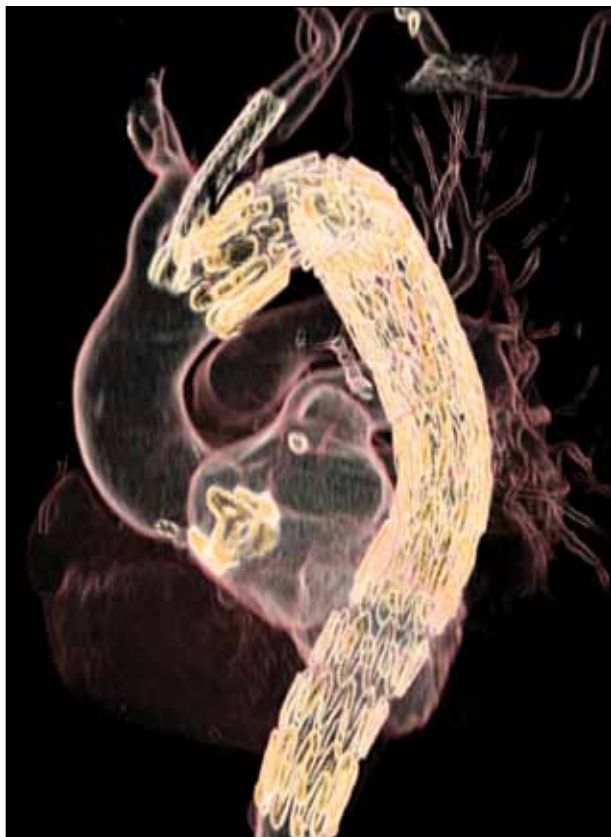


**Figure 3.** Postoperative computed tomography maximum-intensity projection image shows the correct position of the iCast stent in the left common carotid artery and the Zenith TX2 aortic endoprostheses.

alternative for patients who are not appropriate candidates for open surgical repair.<sup>7</sup> The chimney procedure can also be used as a bailout technique when an aortic side branch is inadvertently covered.

Clinical evidence and follow-up data are currently limited to case reports, case series, and small cohort studies. It seems counterintuitive that the chimney grafts can accomplish a good proximal seal because of the potential “gutters” between the stent grafts and the aortic wall. However, a recent meta-analysis by Moulakakis et al described that type Ia endoleaks occurred in 14% of patients, and the majority sealed spontaneously.<sup>8</sup> This may be the result of low flow in the outer layer of blood, clot formation, low outflow, and good conformability of the aortic wall. Increased length of coverage of the proximal landing zone has been suggested to further reduce the risk of type Ia endoleak.<sup>7</sup>

The currently available stent grafts have several limitations. In the described case, it would have been preferential to use a branched device that allows continued perfusion of the left common carotid artery and left



**Figure 4.** Reformatted three-dimensional ECG-gated CTA image shows the aortic arch anatomy, prosthetic aortic valve, left common carotid artery iCast stent, and proximal and distal Zenith TX2 aortic endoprostheses.

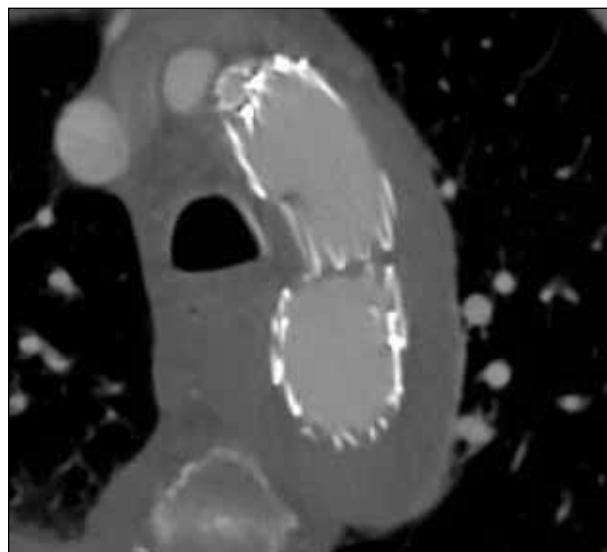
---

## Development of branched technologies and wider implementation of these technologies represent the next step in the evolution of TEVAR.

---

subclavian artery while completely preventing type II endoleak from these side branches. This could potentially improve the patient's prognosis by causing complete thrombosis of the false lumen, possibly resulting in a lower risk of future complications.<sup>9</sup> Development of branched technologies and wider implementation of these technologies represent the next step in the evolution of TEVAR. It is expected that multiple devices will become available in the near future. To allow application of these branched devices in the emergency setting, the stent grafts should allow flexibility for variation in patient anatomy.

Another limitation of currently available endografts is the poor conformability of devices to the native aortic arch anatomy. Resultant “bird beaking” may even lead to endograft collapse after TEVAR. Excessive oversizing, distal aortic diameter, minimum intragraft aortic diameter, and a small radius of curvature of the aortic arch have also been reported as important causes of endograft collapse.<sup>10,11</sup> Recent improvements in device design and future iterations are likely to improve stent graft performance and prevent this complication.



**Figure 5.** An axial CTA image at the level of the chimney and TEVAR graft.

Considering the anatomical challenges of the thoracic aorta, the chimney graft technique can provide an emergent endovascular solution for ruptured descending aortic dissection.

Currently available devices have been designed and are US Food and Drug Administration approved for treatment of descending thoracic aortic aneurysms. The availability of endovascular stent grafts that are specifically designed for aortic dissection will likely further improve the prognosis of these patients. These aortic dissection-specific devices are likely to become available in the US in the near future and will hopefully allow coverage of the entry tear, stabilization of the dissection flap, and re-expansion of the true lumen while allowing for variations in patient anatomy.

Although outcome-specific data regarding the use of self-expanding versus balloon-expandable stents with the chimney technique are very limited, there are several possible advantages to using balloon-expandable stents. These include less recoil, absence of continued expanding force, and better deployment accuracy.<sup>7</sup> Accurate length of the branch stent graft is important to ensure extension proximal to the aortic graft to allow for continued perfusion. Additionally, accurate diameter sizing is required to prevent kinking, endoleak, or other complications due to over- or undersizing.

Planning of the endovascular procedure therefore requires additional radiologic imaging compared with open surgical repair. Our group has proposed the use of electrocardiography (ECG)-gated CTA for simultaneous preoperative sizing and cardiac risk stratification.<sup>12</sup> In patients with suspected aortic dissection specifically, ECG-gated CTA lowers the false-positive rate of diagnosis by reducing motion artifact due to the aortic pulsatility. This will also improve our understanding of the native aortic environment in which the TEVAR stent graft is placed and may help to improve device selection and sizing.

## CONCLUSION

Considering the anatomical challenges of the thoracic aorta, the chimney graft technique can provide an emergent endovascular solution for ruptured descend-

ing aortic dissection. Long-term data are needed to provide more information regarding safety and durability. Future devices are likely to include branched stent grafts, improved conformability, designs that are more specific for the patient's pathology, and hopefully allow more flexibility for variation in anatomy and use in emergency situations. It is clear that more patients are currently being treated with endovascular solutions than ever before, and with ongoing developments in device design and stent graft availability, even more patients are likely to benefit from these improvements in the future. ■

*Felix J. V. Schlösser, MD, PhD, is with the Section of Vascular Surgery, Department of Surgery at Yale University School of Medicine in New Haven, Connecticut. He has disclosed that he has no financial interests related to this article. Dr. Schlösser may be reached at (203) 785-2564; felix.schlösser@yale.edu.*

*Hamid R. Mojibian, MD, is with the Section of Interventional Radiology, Yale University School of Medicine in New Haven, Connecticut. He has disclosed that he has no financial interests related to this article. Dr. Mojibian may be reached at (203) 785-7026; hamid.mojibian@yale.edu.*

*Bart E. Muhs, MD, PhD, is with the Section of Vascular Surgery, Department of Surgery and Department of Radiology at Yale University School of Medicine in New Haven, Connecticut. He has disclosed that he is a consultant to and receives research support from Cook Medical. Dr. Muhs may be reached at (203) 785-2564; bart.muhs@yale.edu.*

1. Svensson LG, Kouchoukos NT, Miller DC, et al; for the Society of Thoracic Surgeons Endovascular Surgery Task Force. Expert consensus document on the treatment of descending thoracic aortic disease using endovascular stent-grafts. *Ann Thorac Surg.* 2008;85(1 suppl):S1-41.
2. Dake MD, Miller DC, Semba CP, et al. Transluminal placement of endovascular stent-grafts for the treatment of descending thoracic aortic aneurysms. *N Engl J Med.* 1994;331:1729-1734.
3. O'Donnell S, Geotches A, Beavers F, et al. Endovascular management of acute aortic dissections. *J Vasc Surg.* 2011;54:1283-1289.
4. Jonker FH, Trimarchi S, Verhagen HJ, et al. Meta-analysis of open versus endovascular repair for ruptured descending thoracic aortic aneurysm. *J Vasc Surg.* 2010;51:1026-1032.
5. Lee WA, Daniels MJ, Beaver TM, et al. Late outcomes of a single-center experience of 400 consecutive thoracic endovascular aortic repairs. *Circulation.* 2011;123:2938-2945.
6. Schlösser FJ, Muhs BE. Commentary: the chimney and periscope graft technique: emergent endovascular solutions for rupture of the visceral abdominal aorta. *J Endovasc Ther.* 2012;19:563-564.
7. Schlösser FJ, Aruny JE, Freiburg CB, et al. The chimney procedure is an emergently available endovascular solution for visceral aortic aneurysm rupture. *J Vasc Surg.* 2011;53:1386-1390.
8. Moulakakis KG, Mylonas SN, Avgerinos E, et al. The chimney graft technique for preserving visceral vessels during endovascular treatment of aortic pathologies. *J Vasc Surg.* 2012;55:1497-1503.
9. Qin YL, Deng G, Li TX, et al. Risk factors of incomplete thrombosis in the false lumen after endovascular treatment of extensive acute type B aortic dissection. *J Vasc Surg.* In press.
10. Jonker FH, Schlösser FJ, Geirsson A, et al. Endograft collapse after thoracic endovascular aortic repair. *J Endovasc Ther.* 2010;17:725-734.
11. Muhs BE, Balm R, White GH, et al. Anatomic factors associated with acute endograft collapse after Gore TAG treatment of thoracic aortic dissection or traumatic rupture. *J Vasc Surg.* 2007;45:655-661.
12. Schlösser FJ, Mojibian HR, Dardik A, et al. Simultaneous sizing and preoperative risk stratification for thoracic endovascular aneurysm repair: role of gated computed tomography. *J Vasc Surg.* 2008;48:561-570.