

## WHAT WOULD YOU DO?

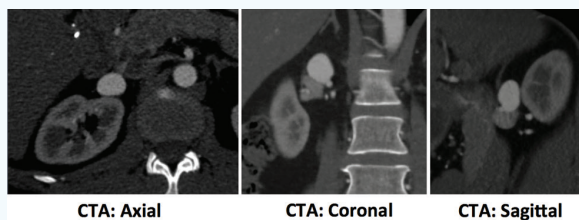
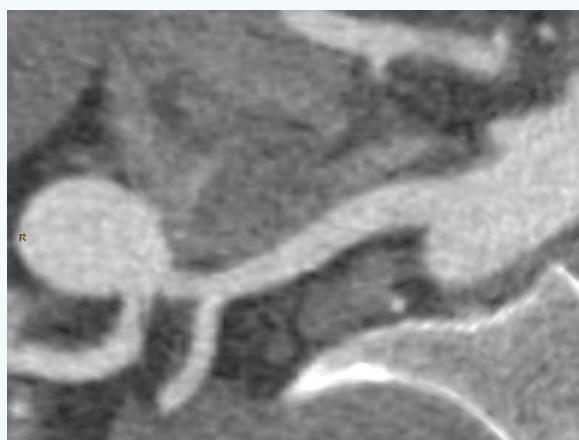
# Growing Right Renal Artery Aneurysm

**MODERATOR: PARAG J. PATEL, MD, MS, FSIR****PANEL: MAUREEN P. KOHI, MD, FSIR; RAHUL S. PATEL, MD; AND SAHER SABRI, MD, FSIR****CASE PRESENTATION**

A 49-year-old woman with a known 2.1-cm right renal artery aneurysm that is now growing (it was 1.5 cm 1 year ago) presents with right flank pain for 4 months that comes and goes and is unrelated to activity. She reports no pain on the left side. She has a family history of ruptured visceral artery aneurysms in her mother, grandmother, and cousin. Multiple relatives have had cerebral aneurysms, but she has been evaluated and results have been normal. She quit smoking 11 years ago.

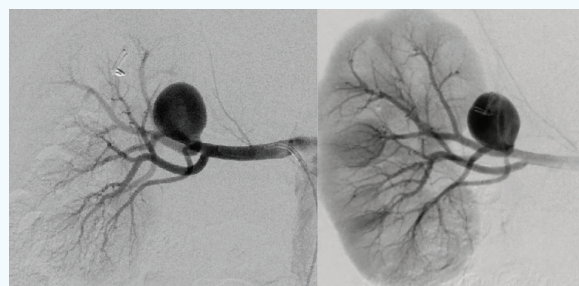
Although observation is a common recommendation for an aneurysm of this size, a decision is made to proceed to endovascular treatment due to the patient's flank pain and strong family history of ruptured visceral artery aneurysms.

CTA is performed (Figure 1), and multiplanar CTA reformatting shows the main renal artery, early branching of the lower pole, and a saccular renal artery aneurysm (Figure 2). Selective digital subtraction angiography of the right renal artery is performed (Figure 3).

**Figure 1****Figure 2**

**What are your size criteria for treating visceral artery aneurysms (eg, renal, mesenteric, celiac, splenic, pancreaticoduodenal arcade)?**

**Dr. Kohi:** My criteria for treating patients with visceral artery aneurysms include aneurysm size ( $> 2$  cm), symptoms attributed to the aneurysm (eg, pain), and findings that increase the chance of rupture such as rapid interval growth or female sex (particularly women of childbearing age or pregnant women in whom the aneurysm can rapidly grow and potentially rupture). It should be noted that visceral artery pseudoaneurysms require treatment regardless of size or symptoms due to the increased risk of impending rupture and bleeding.

**Figure 3**

**Dr. Rahul Patel:** The size criteria for treatment of visceral aneurysms really stem from the treatment of splenic aneurysms. A few good studies have shown that an asymptomatic splenic artery aneurysm should typically be treated if > 2 cm in size. Of course, this excludes women who are of childbearing age and, in our practice, patients with splenomegaly and/or portal hypertension; in these patients, our treatment threshold is lower. This criterion has been carried over to other visceral aneurysms, including renal artery, superior mesenteric artery, and celiac artery aneurysms. However, I would argue that each of these represents a different risk profile of rupture, treatment, and possible symptomatology; our treatment size cutoff is much more dependent on the patient's underlying history as well as presumed risks associated with treatment.

The one area where our size criterion is lower is for the pancreaticoduodenal arcade, where we have seen ruptured aneurysms at a much smaller size (as small as 1 cm). As such, we tend to treat these aneurysms if they are 2.5 times larger than the normal inferior pancreaticoduodenal artery, as opposed to an absolute size cutoff.

**Dr. Sabri:** The size criterion I use for treating visceral aneurysms is 25 mm or larger. I also treat symptomatic aneurysms regardless of size. An example would be thrombus-filled aneurysms that cause distal emboli and infarction. It is important to differentiate true aneurysms from pseudoaneurysms. Regardless of size, all pseudoaneurysms need to be treated due to higher risk of rupture.

A specific category of aneurysms involves the pancreaticoduodenal arcade in patients with median arcuate compression of the celiac artery. The mechanism of aneurysm formation is related to high flow in the collateral circulation. When treating such aneurysms with endovascular embolization, attention should be given to preserving collateral flow to the hepatic artery through the pancreaticoduodenal arcade or considering surgical median arcuate ligament release.



**Would you treat this patient? If so, what type of treatment would you choose (endovascular or surgery)? If choosing endovascular, what is your approach (eg, primary coil, inflow/outflow, aneurysm packing, stent-assisted coil, stent graft)?**

**Dr. Sabri:** I would treat this patient, because the aneurysm is likely responsible for her symptoms and also due to the family history of aneurysms. I would attempt an endovascular approach. For the location of the aneurysm, coiling the inflow and outflow branches will result in infarction of a large portion of the kidney, so I would make every effort to

preserve these arteries. The arteries are too small for current stent graft technology, which would have been a preferred option for arteries > 4 mm. Off-label use of flow-diverting stents might be considered here.

My preferred approach is to perform stent-assisted coiling of the aneurysm, which can be done in one of two ways: (1) by placing a bare-metal stent across the neck of the aneurysm and then trying to access the aneurysm through the interstices of the stent, followed by coiling of the aneurysm; or (2) by gaining dual arterial access and accessing the aneurysm sac first and then placing the stent through the other access before coiling the aneurysm sac. This second approach provides the advantage of not being "jailed out" if access in the sac through the stent interstices is unsuccessful. Coiling without stent assistance is also a valid option. However, I think I would achieve a more compact coil pack with stent assistance, and I feel safer with the stent being there to prevent herniation into the feeding artery. Detachable soft coils would be preferred, starting with framing coils and then filling the entire aneurysm sac with soft coils.

**Dr. Kohi:** I would treat this patient because the aneurysm measures > 2 cm, has grown rapidly in the last year, and because she complains of pain, which is likely due to her aneurysm. For treatment, I would take an endovascular approach. I would coil the aneurysm sac using detachable coils, making sure that the coils are densely packed to decrease the chance of coil compaction and recanalization. Although I would consider use of a stent graft, the presence of the early branching lower pole artery makes me favor coil embolization of the aneurysm sac. I would not coil the inflow or outflow branches in this case, because of end-organ injury to the kidney.

**Dr. Rahul Patel:** In our practice, this patient would be treated for an aneurysm of this size (2.1 cm) for a few reasons. First, the patient is symptomatic with right flank pain. I still don't wholly understand why unruptured renal aneurysms cause pain, but over the years, we have seen pain resolve for many patients once their aneurysms are treated. The second reason is the growth over a relatively short period of time (1.5 cm to 2.1 cm in 1 year). In my opinion, this portends a bad indicator for potential rupture. I don't have a specific threshold for treatment, but 40% would seem bad and I would be worried about rupture occurring sooner rather than later. A third reason for treatment is the patient's very strong family history of aneurysm rupture.

Given the favorable anatomy for this aneurysm (single inflow and outflow with a relatively narrow neck), I would attempt primary coiling without stent assistance. I would

try to spare as much renal parenchyma as possible, so coiling the inflow and outflow branches would not be a good approach. Use of a stent graft is possible; however, the main concern is that the artery is small and the only approved stent grafts in the United States would not be of an appropriate size. There is a humanitarian device exemption for a coronary artery perforation device (Graftmaster RX, Abbott Vascular), which would potentially work in this situation, but frankly, it's a lot of paperwork.

My approach to treatment would be a transradial approach to start to build my embolization platform. I would place a 6-F Glidesheath Slender sheath (Terumo Interventional Systems) in the left wrist, through which I would place a 6-F JR4 guide catheter into the right renal artery. Next, I would place a microcatheter into the renal aneurysm. My choice of microcatheter would depend on which coil I was going to use. This is where packing density and cost come into consideration. To have a durable result without compaction or recanalization, a packing density of > 24% should be achieved. All five of the most common detachable peripheral coils (Concerto, Medtronic; Interlock-18, Boston Scientific Corporation; Ruby, Penumbra, Inc.; Azur CX, Terumo Interventional Systems; and 0.035-inch Retractable, Cook Medical) will work to achieve this packing density. The required number of coils would vary, and thus, the cost to complete the case would change depending on which coil is chosen and the institutional cost of the coils. Depending on the coil system chosen, I would use either a 150-cm, 2.4-F microcatheter for Concerto, Azur CX, or Interlock-18 coils or a 150-cm, 2.8-F microcatheter for the Ruby coil.



#### How would you have treated this patient 5 or 10 years ago?

**Dr. Kohi:** I would have treated the patient with an endovascular approach 5 years ago. However, at that time, detachable coils were not readily available, and I would have used pushable coils, paying close attention to scaffolding the sac and then densely packing it. These patients likely underwent open surgery as opposed to endovascular repair 10 years ago. If endovascular therapy was attempted, pushable coils would have been used. Additionally, guidewires may have been used for coil embolization of large aneurysm sacs in the past.

**Dr. Rahul Patel:** Ten years ago, we didn't really have detachable coils in the peripheral space. We could use some of the neurovascular detachable coils, but these are very cost prohibitive in the peripheral space. Detachable coils allowed us to place many coils of longer lengths into aneurysms more precisely and with less risk of catheter

kickout. Five years ago, our understanding of packing density, as it pertained to peripheral aneurysms, wasn't well understood. We had patients that looked "good" on completion angiograms, yet still came back at follow-up with compaction of the coil mass and needed reintervention.

**Dr. Sabri:** I would have treated this patient in a similar fashion as I previously mentioned. However, we had a limited supply of detachable and framing coils for peripheral application, so neurovascular detachable coils would have to be used.



#### What are the greatest advancements in embolization technology in the last 5 to 10 years that have helped you? What do we still need?

**Dr. Rahul Patel:** In the last 5 to 10 years, the biggest advancement for peripheral coil embolization for me has been the addition of detachable coils that are cost-effective for the peripheral space. This has really taken some of the apprehension out of coiling aneurysms or even vessel sacrifice. The risk of losing access to the target or of a coil flying has greatly decreased. However, there is room for improvement. As detachable coils came from our neurovascular colleagues, they now have newer devices for embolizing aneurysms that are more of a single-device solution, as opposed to a multiple coil option. This will help constrain the cost of treating larger aneurysms.

Another issue is the significant metal artifact that occurs from the coil pack, which necessitates the use of MRI to follow up on these patients. This isn't a huge deal, but the costs of these yearly MRIs add up quickly. There are new technologies in development that may help mitigate this artifact and the need for follow-up MRIs.

**Dr. Sabri:** Many advancements have been made, including more options for detachable coils for peripheral applications, detachable microplugs, and smaller and better-calibrated embolization beads. I would like to see coiling material that is less radiopaque to improve postembolization imaging. Liquid embolic materials that are packaged and priced for peripheral applications would be a welcome addition.

**Dr. Kohi:** A number of technologic advancements have been helpful for embolization. These include numerous detachable coils and plugs that allow for a more controlled detachment and scaffolding of the aneurysm sac, greater availability of covered stents in various sizes, readily available liquid embolic agents such as n-butyl cyanoacrylate and ethylene-vinyl alcohol copolymer, and the



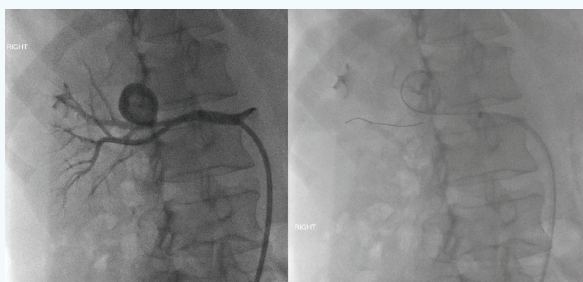


Figure 4.

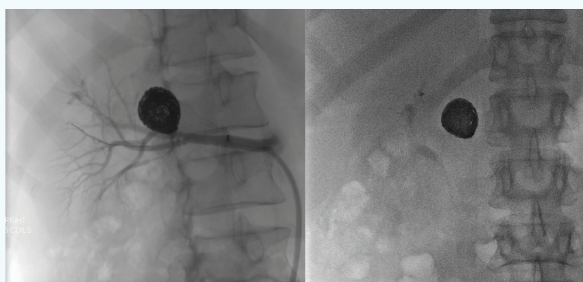


Figure 5.

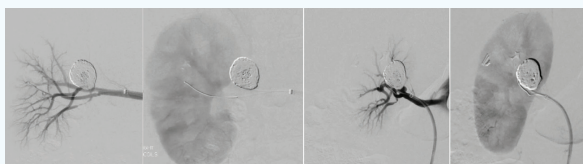


Figure 6.

use of stent-assisted or balloon-assisted coil technology to protect the parent artery. In addition, the availability of cone-beam CT in the angiography suite has allowed for direct puncture of aneurysms and embolization when endovascular access cannot be obtained.

Despite these technical advancements, we lack readily available detachable plugs that can embolize extremely large aneurysms. Although some plugs (eg, the Amplatzer Vascular Plug 4, Abbott Vascular, formerly St. Jude Medical) allow for deployment in large aneurysms and can be used as scaffolding for coils or liquid embolic agents, large embolization coils that can be delivered through a 5-F system or even a microcatheter are lacking. Additionally, we continue to struggle with stent grafts that cannot be deployed along a tortuous artery with precision. With continual innovation, these needs will likely be met in the near future.

### CASE CONTINUED

A Flexor Ansel guiding sheath (Cook Medical) is placed in the main renal artery, and a 0.014-inch buddy wire is maneuvered down the main renal artery. The microcatheter is coiled within the aneurysm sac. Five 16-mm X 50-cm, four 20-mm X 60-cm, and one 12-mm X 40-cm soft Ruby

coils are deployed. After deployment of the coil pack, the aneurysm sac is reevaluated. Postembolization digital subtraction angiograms in two projections shows exclusion of the aneurysm, and a complete nephrogram shows maintained patency of the renal artery branches (Figures 4–6).

### FOLLOW-UP

Since being discharged home, the patient reports no abdominal or flank pain. She is no longer taking pain medications. Initial follow-up imaging with right renal artery duplex ultrasound at 2 months postprocedure demonstrates normal main renal artery flow as well as throughout the renal parenchyma. CT follow-up shows successful exclusion of the right renal artery aneurysm at 2 years. ■

#### Parag J. Patel, MD, MS, FSIR

Associate Professor of Radiology  
Division of Vascular & Interventional Radiology  
Medical College of Wisconsin  
Milwaukee, Wisconsin  
papatel@mcw.edu

*Disclosures:* Consultant to Bard Peripheral Vascular; speaker for Abbott Vascular, Boston Scientific Corporation, and Penumbra, Inc.

#### Maureen P. Kohi, MD, FSIR

Associate Professor of Clinical Radiology  
Division of Vascular and Interventional Radiology  
Department of Radiology and Biomedical Imaging  
University of California, San Francisco  
San Francisco, California  
maureen.kohi@ucsf.edu  
*Disclosures:* None.

#### Rahul S. Patel, MD

Assistant Professor of Radiology and Surgery  
Division of Interventional Radiology  
Mount Sinai School of Medicine  
New York, New York  
rahul.patel@mountsinai.org  
*Disclosures:* Consultant to Medtronic; speaker for Penumbra, Inc. and Terumo Medical.

#### Saher Sabri, MD, FSIR

Associate Professor of Radiology  
Division of Interventional Radiology  
Medstar Washington Hospital Center  
Washington, DC  
sahers.sabri@medstar.net  
*Disclosures:* Speaker for Gore & Associates.