

Intravascular Robotics: Ready for Prime Time

Endovascular procedures are growing rapidly, but challenges remain.

BY JOSEPH J. RICOTTA II, MD, MS, FACS

Over the past 2 decades, a paradigm shift has occurred in the treatment of vascular disease, with dramatic growth in the use of endovascular techniques. Today, approximately two-thirds of abdominal aortic aneurysm repairs are performed via the endovascular approach, and catheter-based techniques are rapidly growing for the treatment of lower extremity peripheral artery disease. These trends have been driven by patient demand for procedures that are less invasive and involve fewer complications and faster recovery, but it is also aided by rapid and continuous innovation in endovascular access and therapeutic devices.

Despite this growth and innovation, limitations remain in terms of what can be achieved via an endovascular approach. Using traditional guidewire and catheter technologies, physicians are, at times, unable to reach, cross, or effectively treat a patient's disease. Vascular tortuosity, lesion morphology and location, and operator technique can all contribute to variability in procedural outcomes. The result is that many patients who might benefit from a minimally invasive, endovascular procedure must undergo open surgery or may not receive treatment at all. In addition, image-guided procedures expose interventionists to significant occupational hazards, including the cumulative and permanent effects of long-term exposure to low-dose, ionizing radiation and musculoskeletal hazards stemming from use of personal protection equipment, such as lead aprons, etc.

ROBOTIC CATHETERIZATION SYSTEMS

Robotic systems offer the potential to address many of the aforementioned limitations, with the goal of bringing greater

precision, efficiency, and predictability to endovascular procedures. The Sensei® X Robotic System (Hansen Medical, Inc.) was developed for remote, robotic catheter control in electrophysiology procedures in the cardiovascular system. The Magellan™ Robotic System,

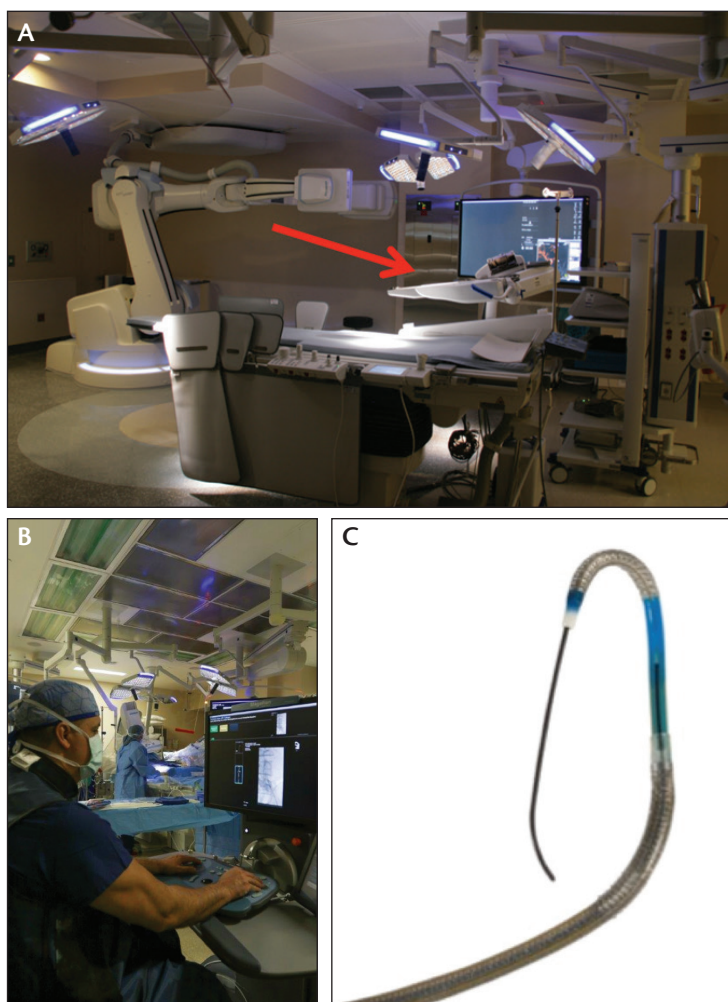


Figure 1. The Magellan Robotic System. The Magellan robotic arm connected to the procedure table (A). Control of the robotic system from a remote workstation (B). The Magellan 9-F robotic catheter (C).

Sponsored by Hansen Medical, Inc.

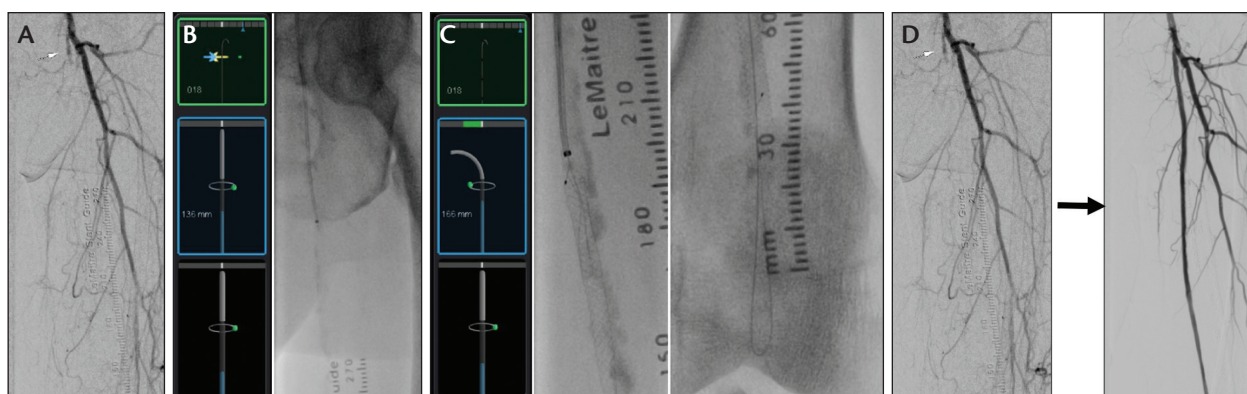


Figure 2. Use of the Magellan system to cross a 45-cm-long CTO of the superficial femoral and popliteal arteries. Complete superficial femoral artery occlusion (A), wire rotation (B), steering the inner robotic leader catheter into the lumen (C), and before and after imaging of the treated area (D).

which is the company's second-generation robotic catheterization system, received US Food and Drug Administration 510(k) clearance in 2012 for the navigation of guidewires and robotic catheters in the peripheral blood vessels.

The Magellan system consists of three main components: (1) a robotic arm that is fixed to the patient table and controls off-the-shelf guidewires and robotic catheters; (2) a physician workstation, which integrates conventional imaging views and enables remote, robotic control of the system, removed from the radiation source; and (3) Magellan robotic catheters (Figure 1). Magellan robotic catheters range in outer diameter from 6 to 10 F and range in inner diameter from 3 to 7 F. The company continues to develop both smaller and larger catheters. The Magellan™ Transport System is available separately and allows the robotic arm to be placed on and off the patient table easily. If the Magellan™ Mobility option is purchased, the arm may be shared between two procedure rooms.

Unlike traditional, preshaped catheters, robotic catheters have steerable tips and enable physicians to change the shape and stiffness profile of the catheter within the blood vessels. Robotic catheters can bend up to 180° and rotate a full 360° at the distal end, without torque or rotation of the proximal section. The result is that robotic catheters are steered to the targeted site within the vasculature, which is in contrast to the manual technique that involves deflecting off of vessel walls to direct preshaped catheters to specific locations.

The robotic catheter allows operators to work in three dimensions and stay within the center of the vessel lumen, thereby limiting the number of catheter touches against the vessel wall and minimizing vessel

trauma.¹ Additionally, there is literature demonstrating that the Magellan Robotic System reduces operator radiation exposure by up to 95% during endovascular procedures when compared against a control measurement at the bedside.²

CLINICAL APPLICATION

In our practice, we perform a high volume of complex endovascular procedures, including fenestrated and branched endografting, which can lead to long procedural times and the associated potential maladies (ie, musculoskeletal hazards from the use of personal protection equipment and increased radiation exposure to the operator, patient, and ancillary staff). The ability to have precise catheter and wire control and work in three dimensions to simplify navigation through complex vascular anatomy, as well as the potential for significantly reduced radiation exposure and shortened procedure times, particularly when performing fenestrated endovascular aneurysm repair (FEVAR),³ is what initially drew my interest to the Magellan Robotic System.

In October 2014, we performed the first endovascular robotic procedure in Georgia, in which I used the Magellan system to cross a 45-cm-long chronic total occlusion (CTO) of the superficial femoral and popliteal arteries (Figure 2). The interesting point about this case is that I had attempted to manually cross this patient's CTO approximately 4 weeks earlier and was able to recanalize approximately 80% of the lesion, but I could not get through the distal cap. I brought the patient back 1 month later, after the robotic system had arrived, and attempted the procedure again. With this system, I was able to keep the wire, catheter, and

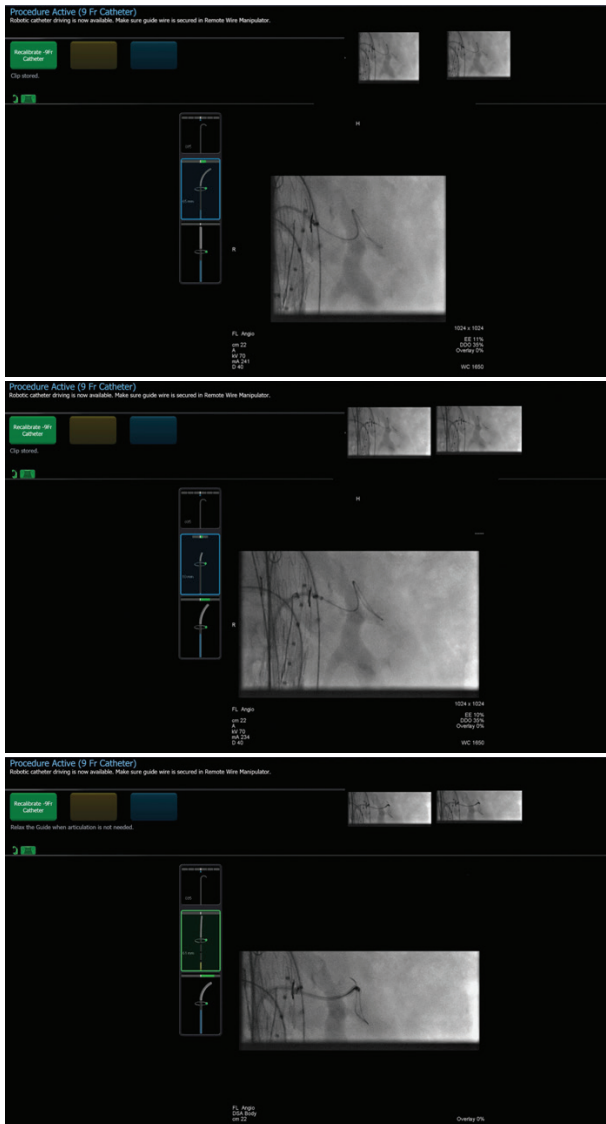


Figure 3. During FEVAR, the Magellan system was used to navigate through fenestration into a downward-oriented left renal artery arising from a large aneurysm from the femoral approach. This was accomplished with no wire, catheter, or sheath exchanges.

sheath in the center of the lumen, and using a telescoping technique, crossed the entire lesion in approximately 60 seconds. I was quite surprised by the excellent pushability and trackability of the system. After this initial case with Magellan, I quickly understood that this system could be used for more than just FEVAR.

Since that first case, we have performed more than 50 cases with the Magellan system, consisting of FEVAR, EVAR, CTO/lower extremity interventions, carotid

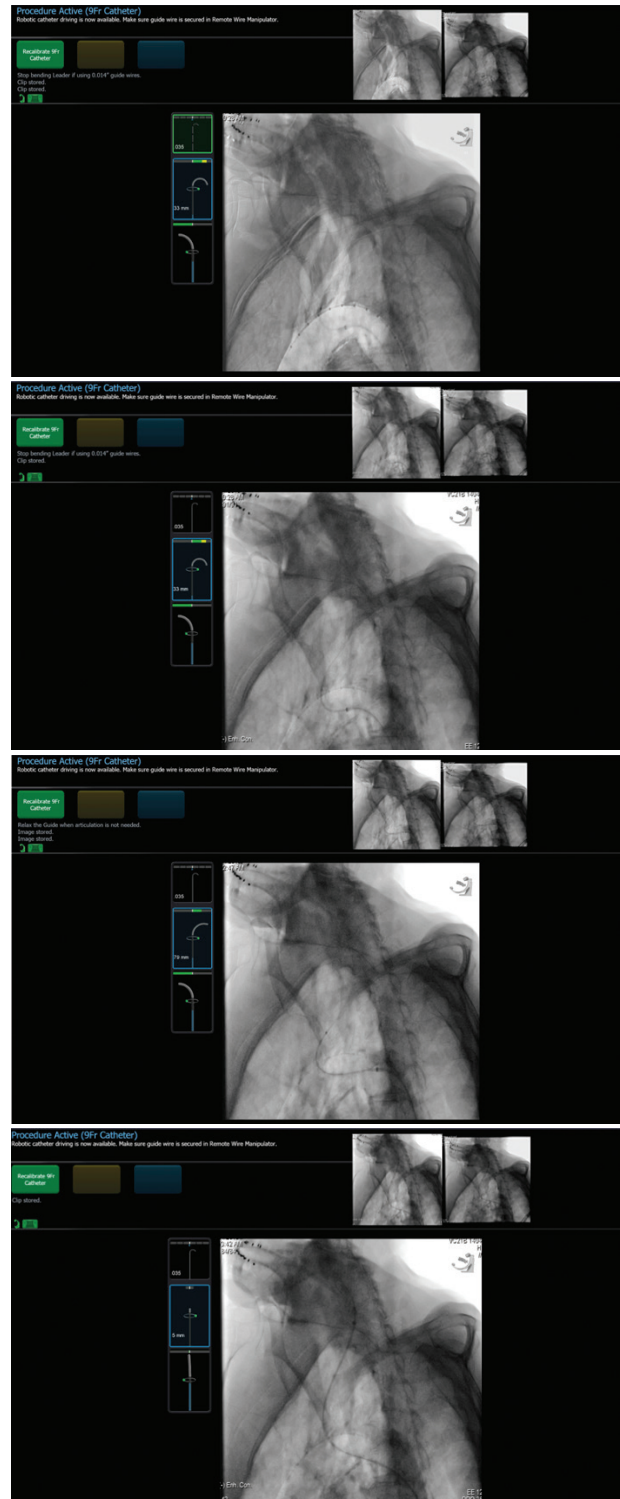


Figure 4. Use of the Magellan system to cannulate a tortuous carotid artery arising from a severely angulated type III aortic arch.

Sponsored by Hansen Medical, Inc.

interventions, renal and mesenteric stenting, arterial and venous embolization, and inferior vena cava filter removal. The operator and staff learning curve for the system is a rapid one. There is a thorough training program developed by the manufacturer for both the operator and the technical staff, which includes a fundamental understanding of how to prepare the device, as well as operating the system. The system itself is very intuitive, and the technical staff and I adapted to it immediately.

Setup of the robot for the inaugural case took approximately 15 to 20 minutes. After about seven to 10 cases, we had the setup time down to 2 to 3 minutes. The robotic arm does add some weight to the table (approximately 80 lb), but is fixed at the end of the table, so it does not interfere with the procedure when not in use. In addition, it is possible to remove the robot from the table after a procedure is completed and place it on a transport system that the manufacturer provides. Using this Magellan Mobility option, the robot can also be transferred to and used in another endovascular suite, provided there are the appropriate connections in the new suite.

As previously mentioned, it is possible to use the Magellan Robotic System for a large variety of endovascular procedures. The procedures in which I have found it to be most useful are lower extremity cases with CTO or acute angle aortic bifurcations (including those that have had previous bifurcated aortic bypass grafting or endografting), FEVAR interventions with angulated aortic arches, embolization through tortuous vessels, and renal/mesenteric intervention via the femoral approach for downward-oriented vessels. I have used the Magellan system in several FEVAR cases and find it particularly useful in navigating through fenestrations and into the mesenteric arteries or angulated renal arteries (Figure 3) from the femoral approach. In addition, we have seen a precipitous drop in our branch vessel cannulation time and overall procedural times, as well as a significant reduction in fluoroscopy time and radiation use, confirming the report by Riga and colleagues.³ When combining the robot with three-dimensional fusion imaging technology, we can now perform four-vessel FEVAR with very little radiation and contrast use, which has the potential to significantly improve patient safety and quality of care.

Interventions with severely angulated aortic arches and tortuous arteries can be quite challenging using traditional manual catheter manipulation and may pose an increased risk of atheroembolization, particularly from

The system itself is very intuitive,
and the technical staff and I
adapted to it immediately.

catheter manipulation in the arch. In addition, many times, several different types and shapes of catheters are used when attempting to navigate this challenging anatomy, adding to the overall cost of the procedure. With the Magellan Robotic System, you are able to keep the catheters and wires in the center of the vessel lumen and avoid contact with and trauma to the sidewalls of the aortic arch. Only one catheter is required, and it can be shaped and rotated into whatever conformation is desired. I have found this to be very useful in type III aortic arches (Figure 4), and it has reduced my catheterization time from sometimes minutes using different shapes of catheters, support sheaths, and buddy wires, etc. to a matter of seconds with the Magellan system.

CONCLUSION

In summary, the potential benefits of the Magellan Robotic System include more predictable navigation through tortuous anatomy, reduced vessel wall interaction during navigation, increased stability during delivery of therapeutic devices, fewer catheter and guidewire exchanges, reduced radiation exposure for the operator and the patient, and shortened procedure times during complex cases. All of these provide the potential to greatly improve safety, efficacy, quality, and efficiency. ■

Joseph J. Ricotta II, MD, MS, FACS, is Associate Professor of Surgery at GRU/University of Georgia School of Medicine and practices vascular surgery in Atlanta, Georgia. He has stated that he has no financial interests related to this article. Dr. Ricotta may be reached at (404) 293-2929; jricotta@gru.edu.

1. Riga CV, Bicknell CD, Hamady M, Cheshire N. Tortuous iliac systems—a significant burden to conventional cannulation in the visceral segment: is there a role for robotic catheter technology? *J Vasc Interv Radiol.* 2012;23:1369-1375.

2. Rao S. Robot-assisted transarterial chemoembolization for hepatocellular carcinoma: initial evaluation of safety, feasibility, success and outcomes using the Magellan system. *J Vasc Interv Radiol.* 2015;26:S12.

3. Riga C, Bicknell C, Rolls A, et al. Robot-assisted fenestrated endovascular aneurysm repair (FEVAR) using the Magellan system. *J Vasc Interv Radiol.* 2013;24:191-196.