

Techniques for Cerebral Aneurysm Treatment

Current research aims to expand the tools available for endovascular treatment of this challenging disease.

BY KYLE M. FARGEN, MD, MPH; BRIAN L. HOH, MD; AND J MOCCO, MD, MS

Subarachnoid hemorrhage secondary to ruptured intracranial aneurysms remains one of the most challenging disease processes in medicine. Even with recent advances in neurocritical care and interventional techniques, the morbidity and mortality rates associated with aneurysm rupture are substantial. Since the development and implementation of the detachable coil for intracranial aneurysms by Guglielmi in 1991, interventionists (with the support of industry) have continued to push the envelope in device design. With each passing year, the armamentarium of the endovascular specialist continues to diversify. Recent additions include new balloon catheters for balloon-assisted coil embolization, flow-diversion devices,¹⁻⁷ new open- and closed-cell stent designs,⁸⁻¹³ and novel coil¹⁴⁻²⁰ and embolic materials.²¹⁻²³

In addition, research into the biochemical derangements after subarachnoid hemorrhage has guided our understanding and treatment of posthemorrhage vasospasm.²⁴⁻³⁰ New three-dimensional (3D) morphological analyses and flow algorithms have improved our understanding of the hemodynamic factors leading to rupture, which may help identify aneurysms that are at highest risk.³¹⁻³⁵ This article aims to highlight some of the recent research pertaining to the endovascular treatment of aneurysms that will likely guide the future management and treatment of patients with this challenging disease.

FLOW-DIVERSION DEVICES

The necessity of total aneurysm occlusion via embolization has been challenged recently by stent devices that target parent vessel reconstruction (rather than embolization of the aneurysm sac) and promote aneurysm thrombosis by diversion of flow through the parent vessel lumen (Figure 1). Such devices were developed for fusiform aneurysms or other difficult-to-embolize, wide-necked lesions.

One such device is the Pipeline embolization device (ev3 Inc., Plymouth, MN), a bimetalllic braided stent designed to provide the necessary surface coverage to divert flow from the aneurysm while preserving flow into perforators or branch vessels. In the initial rabbit model, 88% of aneurysms treated showed complete or near-complete occlusion at follow-up ranging from 1 to 6 months.¹

The largest series published to date in humans, consisting of 63 wide-necked or fusiform aneurysms, showed a complete occlusion rate of 95% at 12 months with a low complication rate.² Similarly, 17 of 18 aneurysms treated with the Pipeline device were completely occluded at 6 months in a separate cohort.³ The majority of cases in the largest study were treated successfully with one device; however, multiple patients required the deployment of two or three overlapping Pipeline devices to achieve acceptable results.² The need for multiple overlapping stents to obtain a favorable angiographic outcome is well documented.^{2-5,36} This fact is

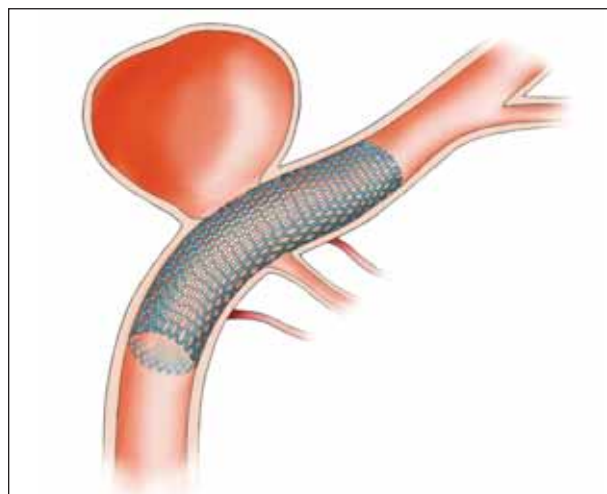


Figure 1. A flow-diversion stent preserving flow into perforators while diverting flow from the aneurysm.

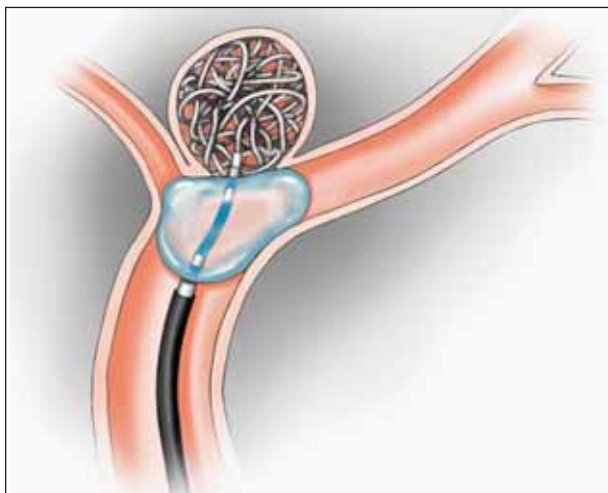


Figure 2. A double-lumen balloon catheter.

of particular interest given the concerns for perforator occlusion and iatrogenic infarction secondary to telescoped devices.³⁶ The Pipeline device is currently under investigation for US Food and Drug Administration (FDA) approval.

A second flow-diverting device, the Silk stent (Balt Extrusion, Montmorency, France), has been successful in a number of case reports,⁶⁷ although one death from post-treatment aneurysm rupture has already been reported.³⁷

Asymmetric vascular stents containing low-porosity patches have similarly produced promising results in animal models.^{8,9} These devices consist of stents with varied porosity so that the area of low porosity can be positioned over the aneurysm neck while only the high-porosity regions of the stent cover the associated side branches and perforators. Human trials with these devices have yet to be completed.

Other techniques, such as the use of multiple stents to reproduce a flow-diversion device, are currently being researched. In addition, research is underway to evaluate stent porosity to determine the ideal pore size to optimize perforator preservation while promoting aneurysm thrombosis through flow diversion.³⁸⁻⁴¹ Should these devices continue to achieve good results with a low complication profile, practicing interventionists will have new, easy-to-deploy tools for treating some of our previously most challenging aneurysms.

ASSISTED COIL EMBOLIZATION

Although they are by no means new to endovascular therapies, the techniques of balloon- and stent-assisted coil embolization continue to be the subject of important research. Both techniques allow for higher packing density by preventing coil herniation into the vessel lumen in wide-necked or complex aneurysms.⁴² New balloon catheters

(Figure 2), such as the Ascent double-lumen catheter (Micrus Endovascular Corporation, San Jose, CA), which is compatible with 0.014-inch guidewires, have been developed to improve balloon-assisted coil embolization by reducing the need for additional catheters.

Stent technology has progressed markedly during the last decade, and numerous different open- and closed-cell self-expanding stent designs are now available for use. With improvements in design and a versatile group of devices to choose from, interventionists are finding unique ways to treat aneurysms that were previously considered “uncoilable.” Additionally, the advent of catheter-based delivery of aneurysm embolization-assisting stents, first made prevalent by the Enterprise vascular reconstruction device (Codman Neurovascular, Codman, a Johnson & Johnson Company, Ratham, MA), has substantially improved stent navigability. With the newly FDA-approved Neuroform EZ stent (Boston Scientific Corporation, Natick, MA), this trend toward easier deliverability continues to progress.

Several large series have indicated excellent midterm or long-term results with stent-assisted coiling.¹⁰⁻¹² Of concern is the risk of in-stent stenosis or thrombosis, which occurs in approximately 3% to 6% of cases after deployment of previous Neuroform iterations (Boston Scientific Corporation)¹³ or Enterprise stents (unpublished data, 2010) for treating intracranial aneurysms. Given this concern, placement of an intracranial stent usually necessitates dual-antiplatelet therapy. There is current research being done to evaluate the risk of in-stent stenosis or thrombosis in patients undergoing stent-assisted coiling as well as the optimal length of time needed for dual-antiplatelet therapy. In addition, novel stent delivery systems and designs are currently being evaluated.

THERAPIES TO PREVENT RECANALIZATION AFTER EMBOLIZATION

Of significant concern to practicing interventionists is the considerable risk of aneurysm recanalization after coil embolization, which has been estimated to occur in anywhere from 5% to 38% of coiled aneurysms.⁴³⁻⁴⁵ The first detachable coils developed for deployment within cerebral aneurysms were composed of bare platinum. To improve recanalization rates, research has shifted toward the use of other compounds to produce a more robust inflammatory reaction that will enable early fibrosis of the aneurysm sac and therefore result in improved recanalization rates.

The most prominent developments in this arena are the use of bioactive and hydrogel coils, which are platinum coils variously constructed with either a bioabsorbable polymeric or a hydrogel that expands on contact with blood. Early data on the HydroCoil (MicroVention, Inc., Tustin, CA), a platinum-based coil coated with hydrogel, suggest

decreased recanalization rates with comparable complication rates compared to bare-platinum coils.^{14,15} Bioactive coils, the most prominent of which is Cerecyte (polyglycol acid-loaded coils) (Micrus Endovascular Corporation), have shown similar results.¹⁶⁻¹⁸ However, recent data presented at the American Society of Neuroradiology 2010 annual meeting from the Cerecyte coil trial, a randomized trial of 500 patients comparing bare-platinum and Cerecyte coils, indicate excellent aneurysm occlusion rates of approximately 85% in both groups and therefore little superiority to Cerecyte over bare platinum.

Focus has also shifted toward the testing of coils with complex designs instead of standard helical coils. New data have suggested that complex-shaped coils may reduce recanalization rates by allowing improved packing density,¹⁹ and testing of these coils has demonstrated satisfactory midterm occlusion results.²⁰

However, long-term success rates with both novel coil materials and coil designs are currently unavailable. Unfortunately, comparative studies between such coils have not yet provided the necessary evidence to show superiority among any of these products.⁴⁶ Cerebrovascular interventionists eagerly await the results of trials underway that will hopefully provide these much-needed answers.

Finally, active research is also exploring alternative avenues to prevent delayed recanalization after embolization. Onyx HD-500 (ev3 Inc.), a liquid embolic agent, has been used to treat intracranial aneurysms since obtaining FDA approval in 2007. Several large series (> 70 aneurysms) have shown 80% to 90% occlusion rates at 12 to 18 months and comparable complication rates to coil embolization.²¹⁻²³ Other liquid agents are currently being evaluated in animals for feasibility and efficacy,⁴⁷ which may translate to human trials should continued success be achieved. Novel endovascular therapies that use radiofrequency ablation and in situ radiation are currently being pursued and have shown efficacy in nonhuman models; however, their effectiveness in human subjects has yet to be elucidated.⁴⁸⁻⁵⁰

ANEURYSM MORPHOLOGY AND HEMODYNAMICS

Although somewhat antiquated, most interventionists and neurosurgeons currently use size and location as the primary determinants of whether to treat unruptured intracranial aneurysms. Unfortunately, findings from the International Study of Unruptured Intracranial Aneurysms stating that small (< 7 mm) aneurysms have a near-zero risk of hemorrhage annually do not correlate with other studies suggesting many ruptured intracranial aneurysms are, in fact, small. In addition, certain aneurysm locations (anterior communicating artery) harbor a disproportionately high number of ruptured small aneurysms compared to other

sites. These contradictions have led to a push by researchers to investigate other factors, aside from merely the largest diameter and the location, which may better explain an individual aneurysm's risk of rupture.

Recent improvements in 3D and volumetric imaging analysis, as well as blood flow algorithms, have advanced our understanding of aneurysm morphology and hemodynamics and have provided the means to reproduce and test these factors. Focal regions of low wall-shear stress on the inner-aneurysm wall, focused flow impingement zones, complex flow, and multiple vortices have been identified as potentially hazardous flow characteristics that are more commonly associated with ruptured aneurysms compared to those that are unruptured.^{31,32} Elevated aneurysm-to-parent vessel size ratio has recently been associated with ruptured aneurysms in several studies^{33,34} because such anatomy may be responsible for generating dangerous flow patterns.³⁵ Work is currently underway in numerous centers to further explore the relationships of blood flow and aneurysm morphology with the ultimate goal of providing a calculated risk prediction for any given unruptured aneurysm. Interventionists readily await a large-scale trial to provide this necessary information and to finally quiet the questions generated by the International Study of Unruptured Intracranial Aneurysms trial data.

THERAPIES TO PREVENT AND TREAT VASOSPASM AFTER SUBARACHNOID HEMORRHAGE

Vasospasm remains a significant cause of morbidity and mortality after subarachnoid hemorrhage. Radiographic vasospasm occurs in roughly 30% to 70% of patients whereas symptomatic vasospasm occurs in approximately 20% to 30% of patients.⁵¹ In most centers, patients with perfusion deficits, neurologic deficits, angiographically narrowed vessels on imaging, or high flow on transcranial Doppler are usually initiated on "triple H" therapy (hypervolemia, hemodilution, and hypertension) and/or treated with intra-arterial angioplasty or verapamil to temporarily relieve arterial spasm.

Methods to prevent and treat vasospasm have been a major focus of research lately, particularly in the study of the role of biochemical factors in inducing arterial spasm and in therapies for relieving vasospasm in animal models. Thus far, vasospasm prevention research has been disappointing, especially with the failure of tirilazad mesylate to show any benefit in clinical outcome over calcium channel blockers.^{24,25} Novel therapies are currently being tested in human subjects, such as intraventricular tissue plasminogen activator with lumbar drainage, which in one series reduced the need for intra-arterial intervention as well as the need for shunting.²⁶ A randomized trial evaluating the effect of intra-

venous human albumin after subarachnoid hemorrhage has also begun enrolling patients.²⁷ The use of other intra-arterial antispasmodic agents, such as milrinone, has also been evaluated and has been met with initial success.²⁸

However, the most promising endothelial receptor antagonist at this time is clazosentan, which showed a trend in reducing vasospasm-associated mortality and significantly reduced radiographic vasospasm in the phase II CONSCIOUS-1 trial.³⁰ The CONSCIOUS-2 trial, a phase III trial evaluating clazosentan in patients undergoing surgical clipping,²⁹ has completed enrollment. The CONSCIOUS-3 trial, evaluating patients undergoing coil embolization, is still in the enrollment phase. Given the enormous investment of both dollars and researchers into reducing the morbidity associated with vasospasm, we hope to see significant advancements in the prevention and treatment of arterial spasm after subarachnoid hemorrhage soon.

CONCLUSIONS

With each passing year, the armamentarium of the endovascular specialist continues to diversify. Current research in the endovascular treatment of aneurysms is focused on new flow-diversion devices that may be of inte-

gral importance in treating wide-necked or fusiform aneurysms. Furthermore, improvements in stent-assisted coiling techniques and devices have made this technique commonplace. New coil materials and designs are currently being tested to evaluate for improved occlusion and recanalization. Improvements in vasospasm prevention and treatment are actively being sought across the world. The development of complex fluid dynamic models and volumetric imaging is allowing the determination of high-risk predictive factors. The ability to provide accurate predictions of rupture risk for each individual aneurysm based on morphological and hemodynamic testing is within our reach. It is truly an exciting time to practice in this challenging field of medicine. ■

The University of Florida receives an educational grant and consulting fees from Codman Neurovascular.

Kyle M. Fargen, MD, MPH, is a resident with the Department of Neurosurgery, University of Florida College of Medicine in Gainesville, Florida. He has disclosed that he holds no financial interest in any product or manufacturer mentioned herein.

Indications for Use

The Medtronic Vascular Complete SE Vascular Stent System is indicated for improving luminal diameter in patients with iliac stenosis in previously unstented lesions with vessel reference diameters between 4.5 mm and 9.5 mm and lesion lengths up to 90 mm. The stent is intended as a permanent implant.

Contraindications

There are no known contraindications.

Warnings/Precautions

The Complete SE Vascular Stent System is provided sterile for one procedure only. Do not re-sterilize. Use prior to the "Use By" date noted on the package • Use of the Complete SE Vascular Stent System requires advanced iliac angioplasty technical skills. The following instructions provide technical guidance but do not obviate the need for adequate training prior to use of the device • Do not use if the temperature indicator found on the inner pouch is changed from a gray square to a black square as this indicates the unconstrained stent diameter and stent release may be compromised • Persons with known hypersensitivities to nitinol and/or its components (e.g. nickel, titanium) may suffer an allergic reaction to the Complete SE Vascular Stent • Maintain the delivery system parallel to the patient and as straight as possible during the procedure to prevent delivery system catheter kinking • Do not deploy the stent if it is not optimal or appropriate for the vessel. The stent cannot be repositioned once deployed • Care should be taken when stenting near a bifurcation, aneurysm or bypass graft • Prior to stent deployment, utilize fluoroscopy to verify the stent has not been damaged or dislodged during positioning • If unable to initiate stent release, remove the entire system from the patient and advance a new, previously unopened stent delivery system • Once deployment is initiated, the stent cannot be recovered by the sheath. In the event of partial delivery of the stent, remove the entire delivery system from the patient. This may result in damage to the vessel wall requiring surgical intervention • Prior to completion of the procedure, utilize fluoroscopy to ensure proper positioning of the deployed stent. If the target lesion is not completely stented, use additional Complete SE Vascular Stents as necessary to adequately treat the lesion • The Complete SE Vascular Stent System is intended for use by physicians familiar with iliac stenting techniques and the risks associated with stenting • Thrombogenicity evaluations were conducted using a heparinized model. If your patient cannot be adequately anticoagulated, it is unknown whether thrombus formation may occur with this product • The use of overlapping stents with the Complete SE Vascular Stent System has not been formally evaluated in a clinical trial • Caution must be taken when crossing the stented area with ancillary equipment to avoid dislodgment of the stent.

Potential Adverse Events

The following complications may be associated with the use of iliac stenting devices or iliac angioplasty: abrupt stent closure; allergic reaction (contrast medium, drug, stent or filter

material); amputation/limb loss; aneurysm or pseudoaneurysm in vessel or at vascular access site; angina/ coronary ischemia; arrhythmia (including premature beats, bradycardia, atrial and/or ventricular tachycardia, atrial and/or ventricular fibrillation [VF]); asystole or bradycardia requiring placement of a temporary pacemaker; arteriovenous fistula; bleeding complications from anticoagulant or antiplatelet medication requiring transfusion or surgical intervention; death; detachment and/or implantation of a component of the system; emboli, distal (air, tissue, plaque, thrombotic material, stent); fever; hematoma at vascular access site, with or without surgical repair; hemorrhagic event, with or without transfusion; hypotension/hypertension; infection, local or systemic including bacteremia or septicemia; ischemia requiring intervention (bypass or amputation of toe, foot, or leg); myocardial infarction; pain (leg/foot); pain at catheter insertion site; pulmonary embolism; renal failure/ insufficiency secondary to contrast medium; stent malposition/ migration; stent strut fracture; stroke; vascular thrombosis/ occlusion at puncture site, treatment site, or remote site; vessel dissection, perforation or rupture; vessel spasm or recoil; worsened claudication/rest pain

Please reference appropriate product *Instructions for Use* for a more detailed list of indications, warnings, precautions and potential adverse events.

CAUTION: Federal (USA) law restricts this device to sale by or on the order of a physician.

For further information, please call Medtronic at 888.283.7868 and/or consult Medtronic's website at www.medtronic.com.

For distribution in the USA only. © 2010 Medtronic, Inc. All rights reserved. Printed in USA. UC201100435EN 6/10

www.medtronic.com
www.medtronicstents.com

Medtronic CardioVascular
3576 Unocal Place
Santa Rosa, CA 95403
USA
Tel: 707.525.0111

**CardioVascular LifeLine
Customer Support**
Tel: 877.526.7890
Tel: 763.526.7890

Product Services
Tel: 888.283.7868
Fax: 800.838.3103



Brian L. Hoh, MD, is Assistant Professor with the Department of Neurosurgery, University of Florida College of Medicine in Gainesville, Florida. He has disclosed that he receives honoraria from Codman Neurovascular and Actelion Inc., as well as nonfinancial research support from Micrus Endovascular.

J Mocco, MD, MS, is Assistant Professor with the Department of Neurosurgery, University of Florida College of Medicine in Gainesville, Florida. He has disclosed that he serves on the Clinical Events Committee Adjudication Board for the CONSCIOUS-2 and CONSCIOUS-3 International Studies (Actelion, Inc.). He is a consultant for Nfocus and Lazarus Effect and has received honoraria from Edge Therapeutics. Dr. Mocco may be reached at j.mocco@neurosurgery.ufl.edu.

- Kallmes DF, Ding YH, Dai D, et al. A new endoluminal, flow-disrupting device for treatment of saccular aneurysms. *Stroke*. 2007;38:2346-2352.
- Lylyk P, Miranda C, Ceratto R, et al. Curative endovascular reconstruction of cerebral aneurysms with the pipeline embolization device: the Buenos Aires experience. *Neurosurgery*. 2009;64:632-642; discussion 642-633; quiz N636.
- Szikora I, Berentei Z, Kulcsar Z, et al. Treatment of intracranial aneurysms by functional reconstruction of the parent artery: the Budapest experience with the pipeline embolization device. *AJNR Am J Neuroradiol*. 2010;31:1139-1147.
- Fiorella D, Woo HH, Albuquerque FC, et al. Definitive reconstruction of circumferential, fusiform intracranial aneurysms with the pipeline embolization device. *Neurosurgery*. 2008;62:1115-1120; discussion 1120-1111.
- Fiorella D, Kelly ME, Albuquerque FC, et al. Curative reconstruction of a giant midbasilar trunk aneurysm with the pipeline embolization device. *Neurosurgery*. 2009;64:212-217; discussion 217.
- Leonardi M, Dall'olio M, Princiotta C, et al. Treatment of carotid siphon aneurysms with a microcell stent. A case report. *Interv Neuroradiol*. 2008;14:429-434.
- Appelboom G, Kadri K, Hassan F, et al. Infectious aneurysm of the cavernous carotid artery in a child treated with a new-generation of flow-diverting stent graft: case report. *Neurosurgery*. 2010;66:E623-624; discussion E624.
- Ionita CN, Paciorek AM, Dohatcu A, et al. The asymmetric vascular stent: efficacy in a rabbit aneurysm model. *Stroke*. 2009;40:959-965.
- Ionita CN, Paciorek AM, Hoffmann KR, et al. Asymmetric vascular stent: feasibility study of a new low-porosity patch-containing stent. *Stroke*. 2008;39:2105-2113.
- Biondi A, Janardhan V, Katz JM, et al. Neuroform stent-assisted coil embolization of wide-neck intracranial aneurysms: strategies in stent deployment and midterm follow-up. *Neurosurgery*. 2007;61:460-468; discussion 468-469.
- Liang G, Gao X, Li Z, et al. Neuroform stent-assisted coiling of intracranial aneurysms: a 5 year single-center experience and follow-up [published online ahead of print August 5, 2009]. *Neurol Res*. doi: 10.1179/016164109X12445616596409.
- Lubicz B, Bandeira A, Bruneau M, et al. Stenting is improving and stabilizing anatomical results of coiled intracranial aneurysms. *Neuroradiology*. 2009;51:419-425.
- Fiorella D, Albuquerque FC, Woo H, et al. Neuroform in-stent stenosis: incidence, natural history, and treatment strategies. *Neurosurgery*. 2006;59:34-42; discussion 34-42.
- Gunnarsson T, Tong FC, Klurfan P, et al. Angiographic and clinical outcomes in 200 consecutive patients with cerebral aneurysm treated with hydrogel-coated coils. *AJNR Am J Neuroradiol*. 2009;30:1657-1664.
- Gaba RC, Ansari SA, Roy SS, et al. Embolization of intracranial aneurysms with hydrogel-coated coils versus inert platinum coils: effects on packing density, coil length and quantity, procedure performance, cost, length of hospital stay, and durability of therapy. *Stroke*. 2006;37:1443-1450.
- Geyik S, Ertugrul O, Yavuz K, et al. Comparison of bioactive coils and bare platinum coils for treatment of intracranial aneurysms: a matched-pair analysis. *J Neurosurg*. 2010;112:709-713.
- Bendszus M, Bartsch AJ, Solymosi L. Endovascular occlusion of aneurysms using a new bioactive coil: a matched pair analysis with bare platinum coils. *Stroke*. 2007;38:2855-2857.
- Veznedaroglu E, Koebe CJ, Siddiqui A, et al. Initial experience with bioactive cerecyte detachable coils: impact on reducing recurrence rates. *Neurosurgery*. 2008;62:799-805; discussion 805-796.
- Wakhloo AK, Gounis MJ, Sandhu JS, et al. Complex-shaped platinum coils for brain aneurysms: higher packing density, improved biomechanical stability, and midterm angiographic outcome. *AJNR Am J Neuroradiol*. 2007;28:1395-1400.
- Hirsch JA, Bendok BR, Paulsen RD, et al. Midterm clinical experience with a complex-shaped detachable platinum coil system for the treatment of cerebral aneurysms: Trufill DCS Orbit detachable coil system registry interim results. *J Vasc Interv Radiol*. 2007;18:1487-1494.
- Piske RL, Kanashiro LH, Paschoal E, et al. Evaluation of Onyx HD-500 embolic system in the treatment of 84 wide-neck intracranial aneurysms. *Neurosurgery*. 2009;64:E865-875; discussion E875.
- Molyneux AJ, Cekirge S, Saatci I, et al. Cerebral Aneurysm Multicenter European Onyx (CAMEO) trial: results of a prospective observational study in 20 European centers. *AJNR Am J Neuroradiol*. 2004;25:39-51.
- Cekirge HS, Saatci I, Ozturk MH, et al. Late angiographic and clinical follow-up results of 100 consecutive aneurysms treated with Onyx reconstruction: largest single-center experience. *Neuroradiology*. 2006;48:113-126.
- Zhang S, Wang L, Liu M, et al. Tirilazad for aneurysmal subarachnoid hemorrhage. *Cochrane Database Syst Rev*. 2:CD006778.
- Jang YG, Ilodigwe D, Macdonald RL. Meta-analysis of tirilazad mesylate in patients with aneurysmal subarachnoid hemorrhage. *Neurocrit Care*. 2009;10:141-147.
- Ramakrishna R, Sekhar LN, Ramanathan D, et al. Intraventricular tissue plasminogen activator for the prevention of vasospasm and hydrocephalus after aneurysmal subarachnoid hemorrhage. *Neurosurgery*. 2010;67:110-117.
- Suarez JJ, Martin RH. Treatment of Subarachnoid Hemorrhage with Human Albumin: ALISA study. Rationale and design [published online ahead of print June 10, 2010]. *Neurocrit Care*. doi: 10.1007/s12028-010-9392-8.
- Shankar JJ, Dos Santos M, Deus-Silva L, et al. Angiographic evaluation of the effect of intra-arterial milrinone therapy in patients with vasospasm from aneurysmal subarachnoid hemorrhage [published online ahead of print June 5, 2010]. *Neuroradiology*. doi: 10.1007/s00234-010-0720-7.
- Macdonald RL. Clazosentan: an endothelin receptor antagonist for treatment of vasospasm after subarachnoid hemorrhage. *Expert Opin Investig Drugs*. 2008;17:1761-1767.
- Macdonald RL, Kassell NF, Mayer S, et al. Clazosentan to overcome neurological ischemia and infarction occurring after subarachnoid hemorrhage (CONSCIOUS-1): randomized, double-blind, placebo-controlled phase 2 dose-finding trial. *Stroke*. 2008;39:3015-3021.
- Shojima M, Oshima M, Takagi K, et al. Magnitude and role of wall shear stress on cerebral aneurysms: computational fluid dynamic study of 20 middle cerebral artery aneurysms. *Stroke*. 2004;35:2500-2505.
- Cebal JR, Castro MA, Burgess JE, et al. Characterization of cerebral aneurysms for assessing risk of rupture by using patient-specific computational hemodynamics models. *AJNR Am J Neuroradiol*. 2005;26:2550-2559.
- Rahman M, Smietana J, Hauck E, et al. Size ratio correlates with intracranial aneurysm rupture status: a prospective study. *Stroke*. 2010;41:916-920.
- Ma D, Tremmel M, Paluch RA, et al. Size ratio for clinical assessment of intracranial aneurysm rupture risk. *Neurol Res*. 2010;32:482-486.
- Tremmel M, Dhar S, Levy EI, et al. Influence of intracranial aneurysm-to-parent vessel size ratio on hemodynamics and implication for rupture: results from a virtual experimental study. *Neurosurgery*. 2009;64:622-630; discussion 630-621.
- van Rooij WJ, Sluzewski M. Perforator infarction after placement of a pipeline flow-diverting stent for an unruptured A1 aneurysm. *AJNR Am J Neuroradiol*. 2010;31:E43-44.
- Trowski B, Macht S, Kulcsar Z, et al. Early fatal hemorrhage after endovascular cerebral aneurysm treatment with a flow diverter (SILK-Stent): do we need to rethink our concepts [published online ahead of print March 26, 2010]. *Neuroradiology*. doi: 10.1007/s00234-010-0676-7.
- Kim YH, Xu X, Lee JS. The effect of stent porosity and strut shape on saccular aneurysm and its numerical analysis with lattice Boltzmann method. *Ann Biomed Eng*. 2010;38:2274-2292.
- Augsburger L, Farhat M, Raymond P, et al. Effect of flow diverter porosity on intra-aneurysmal blood flow. *Klin Neurophysiol*. 2009;120:204-214.
- Liou TM, Li YC. Effects of stent porosity on hemodynamics in a sidewall aneurysm model. *J Biomech*. 2008;41:1174-1183.
- Kim M, Taulbee DB, Tremmel M, et al. Comparison of two stents in modifying cerebral aneurysm hemodynamics. *Ann Biomed Eng*. 2008;36:726-741.
- Bendok BR, Parkinson RJ, Hage ZA, et al. The effect of vascular reconstruction device-assisted coiling on packing density, effective neck coverage, and angiographic outcome: an in vitro study. *Neurosurgery*. 2007;61:835-840; discussion 840-831.
- Raymond J, Guilbert F, Weill A, et al. Long-term angiographic recurrences after selective endovascular treatment of aneurysms with detachable coils. *Stroke*. 2003;34:1398-1403.
- Gallas S, Pasco A, Cottier JP, et al. A multicenter study of 705 ruptured intracranial aneurysms treated with Guglielmi detachable coils. *AJNR Am J Neuroradiol*. 2005;26:1723-1731.
- Murayama Y, Nien YL, Duckwiler G, et al. Guglielmi detachable coil embolization of cerebral aneurysms: 11 years' experience. *J Neurosurg*. 2003;98:959-966.
- Kurte W, Berkefeld J. Materials and techniques for coiling of cerebral aneurysms: how much scientific evidence do we have? *Neuroradiology*. 2008;50:909-927.
- Takao H, Murayama Y, Yuki I, et al. Endovascular treatment of experimental aneurysms using a combination of thermoreversible gelatin polymer and protection devices: feasibility study. *Neurosurgery*. 2009;65:601-609; discussion 609.
- Raymond J, Leblanc P, Deslats AC, et al. In situ beta radiation to prevent recanalization after coil embolization of cerebral aneurysms. *Stroke*. 2002;33:421-427.
- Raymond J, Mounayer C, Salazkin I, et al. Safety and effectiveness of radioactive coil embolization of aneurysms: effects of radiation on recanalization, clot organization, neointima formation, and surrounding nerves in experimental models. *Stroke*. 2006;37:2147-2152.
- Raymond J, Savard P, Salazkin I, et al. Radiofrequency endothelial ablation prevents recanalization after endovascular coil occlusion: in vitro and in vivo assessment. *J Vasc Interv Radiol*. 2010;21:101-107.
- Kassell NF, Sasaki T, Colohan AR, et al. Cerebral vasospasm following aneurysmal subarachnoid hemorrhage. *Stroke*. 1985;16:562-572.