

Mixed Ulceration From Arterial and Venous Insufficiency: Is There an Algorithm for Treatment?

By Jon C. George, MD

Mixed arterial and venous disease is prevalent in a significant subset of patients with lower extremity ulcerations. However, there is no consensus on the optimal treatment modality in the setting of mixed arterial and venous disease. This article discusses a mixed arterial and venous disease case and the need for a treatment algorithm for such patients.

CASE REPORT

An 80-year-old woman with a history of chronic renal insufficiency, ischemic cardiomyopathy, and peripheral artery disease presented initially with lifestyle-limiting claudication of the left lower extremity. Physical examination revealed nonpalpable pulses except for Doppler signal of the left dorsalis pedis artery. Ankle-brachial index (ABI) of the extremity was 0.43, suggestive of occlusive femoral disease. Angiography of the left common femoral artery with runoff revealed distal left superficial femoral artery occlusion (Figure 1A) with reconstitution of the distal popliteal artery and two-vessel runoff into the left foot via the anterior tibial and peroneal arteries (Figure 1B).

Revascularization of the occlusion was performed using balloon angioplasty and stent placement (Figure 2A) with a good angiographic result and runoff (Figure 2B). She had complete resolution of her claudication symptoms but returned 1 year later with ulceration of the medial aspect of her left foot above the medial malleolus. Repeat angiography revealed restenosis of the stent (Figure 3A) and reocclusive disease of the distal popliteal artery stent extending into the anterior tibial artery (Figure 3B).

The patient was successfully revascularized (Figure 4). However, the ulceration progressed despite revascularization, prompting referral to my practice for further evaluation of the etiology of her ulcer 6 months after revascularization (Figure 5).

A venous Doppler study of the left lower extremity revealed severe reflux of the left greater saphenous vein (Figure 6)

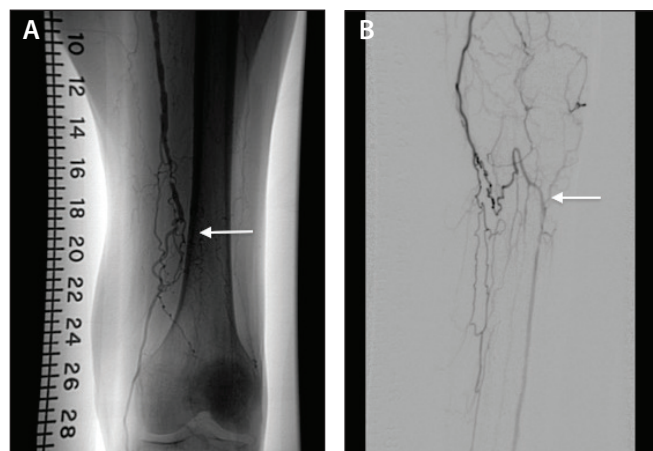


Figure 1. Angiogram of the left lower extremity revealing occlusion (arrow) of the distal superficial femoral artery (A) and reconstitution of the distal popliteal artery and runoff (arrow) via the anterior tibial artery (B).

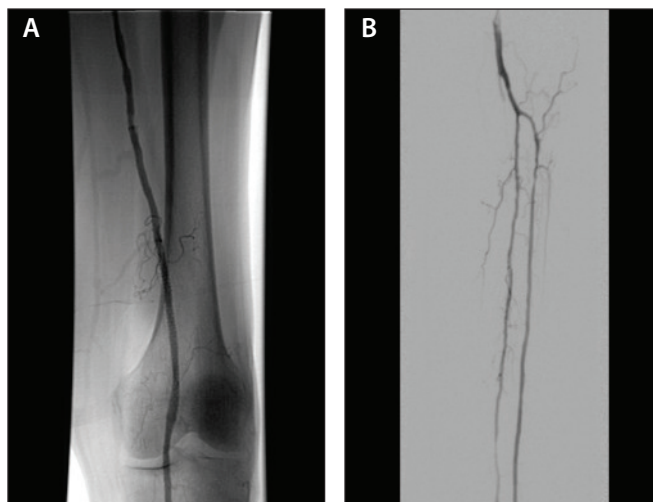


Figure 2. Angiogram after revascularization with balloon angioplasty and stenting (A) and two-vessel runoff (B).

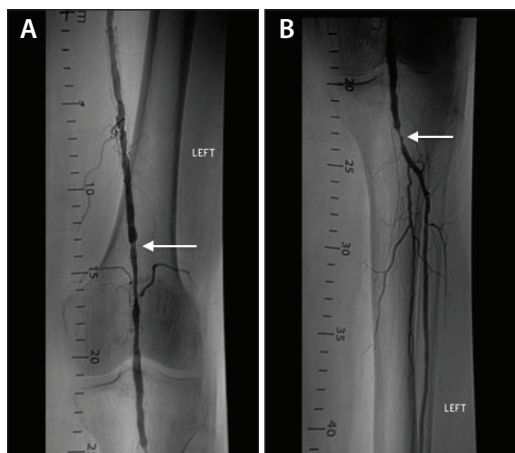


Figure 3. Follow-up angiogram revealing restenosis in the superficial femoral artery stent (A) and outflow lesion in the distal popliteal artery (B).

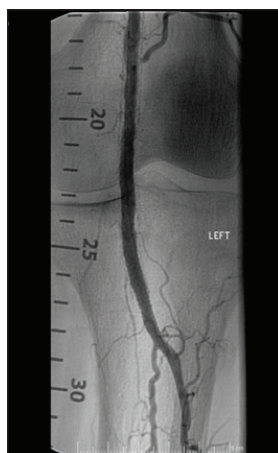


Figure 4. Angiogram after revascularization.

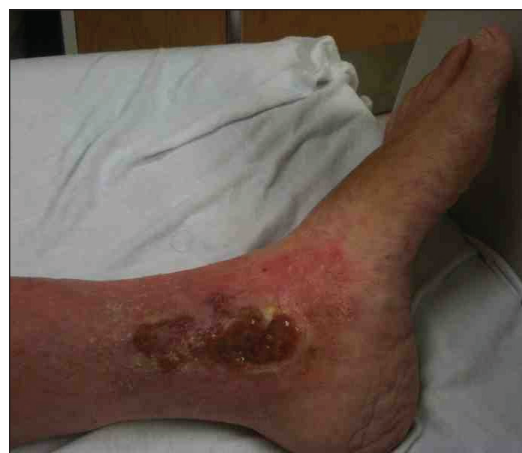

Figure 5. Image of the active ulcer above the medial malleolus of the left foot.

with flow above baseline in the proximal, mid, and distal portions of up to 1.7 seconds. An incompetent perforating vein (0.33 cm in diameter) was also noted in the left calf 23 cm from the ankle (Figure 7).

She subsequently underwent radiofrequency ablation of the left greater saphenous vein followed by the left calf perforator with complete occlusion by ultrasound (Figure 8).

At 3-month follow-up, the patient had complete healing of the ulceration and no residual symptoms (Figure 9).

DISCUSSION

Lower extremity ulceration is debilitating and has a significant economic impact.¹ The prevalence of lower extremity ulceration is 0.18% to 2%, with a majority (up to 72%) caused by chronic venous disease (CVD).² The burden of CVD treatment in the United States is enormous, with an estimated annual cost of over \$318 billion per year.³

Various types of lower extremity ulcers exist, including venous, arterial, neuropathic, lymphatic, malignant, infectious, medication-induced, and inflammatory¹; therefore, clinical history and physical examination are necessary to distinguish

them. Venous ulcers, although more common, are often mistaken for arterial ulcers, which range from 10% to 30% of all lower extremity ulcerations.⁴ Arterial ulcers are typically more painful; affect the toes, heel, malleoli, or anterior shin⁴; and are caused by arterial insufficiency. The main mechanisms of venous ulcers are reflux, venous outflow obstruction, or a combination of both⁵ and are predominantly found within the gaiter area above the medial malleolus.² However, in some subsets of patients, both arterial and venous disease coexist, and they develop ulcerations from mixed etiologies.² In these cases, the dominant disease process must be teased out and treated first.

Clinical history and physical examination are critical in diagnosis, including comorbid conditions, history of arterial or venous disease, prothrombotic states, quality of symptoms, and location of the ulcer. Noninvasive diagnostic tests of choice include ABI for diagnosis of peripheral arterial occlusive disease⁴ and duplex ultrasound for venous reflux or thrombosis.⁶

The mainstay of treatment for arterial insufficiency is revascularization via endovascular techniques or surgical

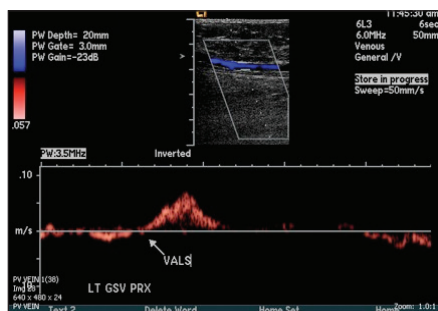


Figure 6. Venous duplex confirming significant reflux of the greater saphenous vein.

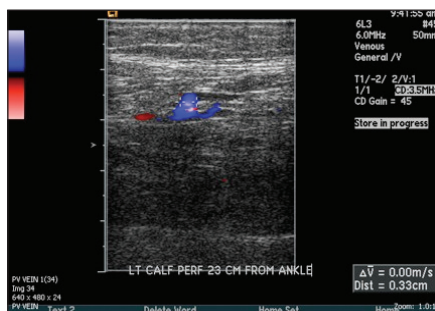


Figure 7. Venous duplex of a pathologic incompetent perforator vein in the left lower extremity above the ulcer.

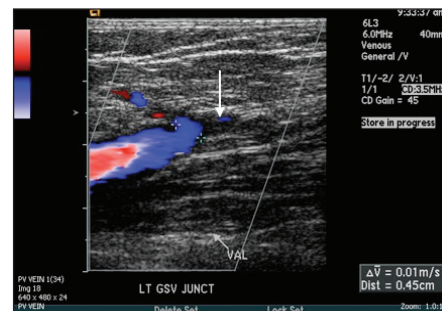


Figure 8. Venous duplex confirming complete obliteration of the greater saphenous vein (arrow) after ablation.

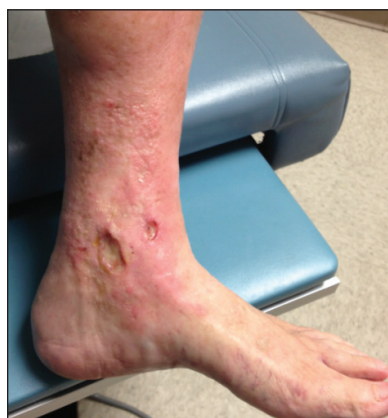

Figure 9. Image of the healed ulcer above the medial malleolus of the left foot 3 months after radiofrequency ablation.

vein,⁸ and has become the most popular invasive approach for treatment of chronic venous insufficiency.

TREATMENT ALGORITHM

Coexistence of arterial and venous disease is estimated to be present in up to 26% of patients with lower extremity ulcerations.⁹ The treatment of these mixed ulcers is optimally achieved by following an algorithm that involves assessment of the wound and degree of arterial and venous insufficiency. While there is no consensus on treatment of these mixed ulcers, the algorithm proposed by Hedayati et al is a popular approach (Figure 10).¹⁰

CONCLUSION

In summary, mixed arterial and venous ulcerations are not uncommon and require a full arterial and venous duplex evaluation in developing a treatment plan. In patients with mixed arterial and venous disease, revascularization is recommended in a staged fashion. Patients with an ABI > 0.7 should undergo wound care and compression therapy for venous disease, patients with an ABI < 0.7 should be considered for revascularization via an endovascular or open bypass procedure to enhance ulcer healing, and patients with an ABI < 0.5 may need earlier arterial intervention to allow for aggressive compression therapy.¹⁰ After arterial intervention, standard wound care and compression therapy remain crucial to wound healing and the prevention of ulcer recurrence. ■

Case report originally published in Vascular Disease Management. 2012;9(7):E121-E124; reprinted with permission from HMP Cardiovascular.

- Spentzouris G, Labropoulos N. The evaluation of lower-extremity ulcers. *Semin Intervent Radiol.* 2009;26:286-295.
- Adam DJ, Naik J, Hartshorne T, et al. The diagnosis and management of 689 chronic leg ulcers in a single-visit assessment clinic. *Eur J Vasc Endovasc Surg.* 2003;25:462-468.
- American Heart Association. Cardiovascular Disease: A costly burden for America.

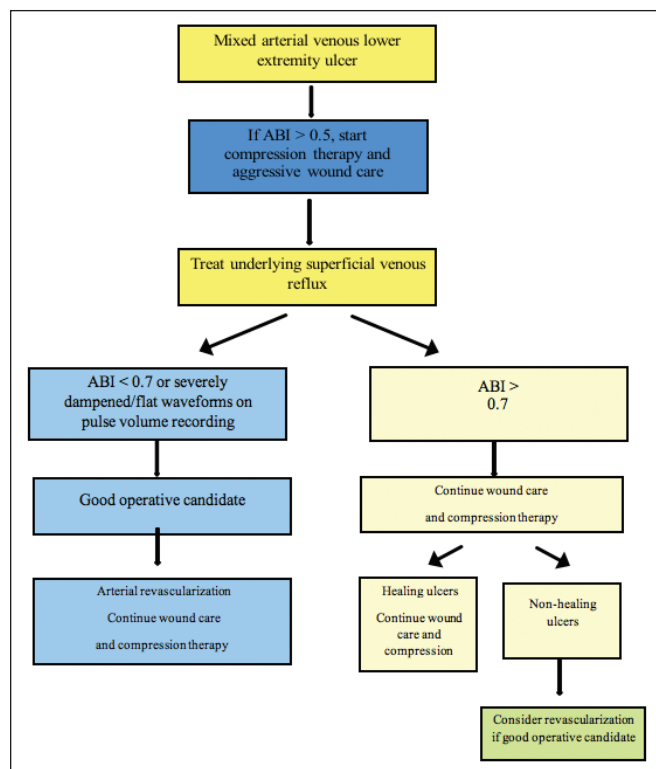


Figure 10. Treatment algorithm for patients with mixed arterial and venous lower extremity ulceration. Nasim Hedayati, John G Carson, Yung-Wei Chi, et al, *Vascular Medicine (Volume 20, Issue 5) pp. 8*, copyright © 2015 by (SAGE Publications). Reprinted by permission of SAGE Publications, Ltd.

http://www.heart.org/HEARTORG/Advocate/Cardiovascular-Disease-A-Costly-Burden-for-America_UCM_491316_Article.jsp#.XRvSgy2ZNTY. Updated February 14, 2017. Accessed July 9, 2019.

- Lazarides MK, Giannoukas AD. The role of hemodynamic measurements in the management of venous and ischemic ulcers. *Int J Low Extrem Wounds.* 2007;6:254-261.
- Nicolaides AN, Allegra C, Bergan J, et al. Management of chronic venous disorders of the lower limbs: guidelines according to scientific evidence. *Int Angiol.* 2008;27:1-59.
- Androulakis AE, Giannoukas AD, Labropoulos N, et al. The impact of duplex scanning on vascular practice. *Int Angiol.* 1996;15:283-290.
- Norgren L, Hiatt WR, Dormandy JA, et al. Inter-society consensus for the management of peripheral arterial disease (TASC II). *J Vasc Surg.* 2007;45(suppl S):S5-67.
- Gloviczki P, Comerota AJ, Dalsing MC, et al. The care of patients with varicose veins and associated chronic venous diseases: clinical practice guidelines of the Society for Vascular Surgery and the American Venous Forum. *J Vasc Surg.* 2011;53(5 suppl):2S-48S.
- Nelzén O, Bergqvist D, Lindhagen A. Leg ulcer etiology—a cross sectional population study. *J Vasc Surg.* 1991;14:557-564.
- Hedayati N, Carson JG, Chi YW, Link D. Management of mixed arterial venous lower extremity ulceration: a review. *Vasc Med.* 2015;20:479-486.

Jon C. George, MD

**Division of Interventional Cardiology and Endovascular Medicine
Einstein Medical Center
Philadelphia, Pennsylvania
jcgeorgemd@hotmail.com**

Disclosures: Consultant to Abbott, Boston Scientific Corporation, Medtronic, and Philips.