

Surveying the 2019 Venous Stent Landscape

A look at the existing and emerging stents being used to treat venous obstruction.

BY ERIN H. MURPHY, MD, FACS

Venous obstruction remains a significant cause of morbidity for many adults worldwide, with quality of life mirroring that of other chronic conditions including diabetes, chronic obstructive pulmonary disease, and congestive heart failure. Although patients with chronic venous obstruction have traditionally been managed with compression and limb elevation, venous stenting has changed this treatment paradigm. The clinical improvements experienced by patients after venous stenting have not only captured the interest of interventionalists but also of medical device companies, a few of which are entering the deep venous space for the first time. Clinical trials testing the technical success, safety, and efficacy of several new venous stents are in various stages of completion. This article provides an overview of the current landscape of venous stent technology in the United States.

THE EMERGENCE OF VENOUS STENTING: WALLSTENT ENDOPROSTHESIS

Venous stenting for iliofemoral outflow obstruction was first reported in the early 1990s. Traditionally, the Wallstent endoprosthesis (Boston Scientific Corporation) has been the primary venous stent, despite a lack of indication for this use. The short-, mid-, and long-term outcomes reported throughout the past 25-plus years have been encouraging,^{1,2} so much so that the field has slowly but consistently gained its footing on the back of the Wallstent.

The Wallstent excels as a conduit, rarely fracturing or failing primarily through the main body of the stent. The stent gracefully handles the curves of the pelvic veins, crosses the inguinal ligament with ease, and maintains strength via both radial force and compression resistance. Until recently, it was the only stent available in diameters large enough to replicate the size of noncompressed, nondiseased iliac veins, which typically range from 14 to 16 mm. Even with the advent of newer nitinol stents, the Wallstent remains as one of the only two stents (the other is the Z-stent, Cook Medical) routinely used in the venous system that is large

enough to be used in the inferior vena cava (IVC) without employing a double-barrel technique.

Although the design of the Wallstent has proven advantageous, there remain two critical shortcomings. First, the edges of the stent are weaker than the main body, making them prone to collapse and even occlusion if landed within diseased or externally compressed vein. This presents a major technical limitation when treating patients with commonly seen external compression of the cranial common iliac vein (CIV) by the overlying common iliac artery. Strictly stenting the area of stenosis positions the weakest portion of the stent at the point of maximum compression within the cranial CIV and is likely to result in stent collapse if left unsupported. To compensate, it was recommended that the Wallstent be positioned so that the cranial edge of the stent landed in the IVC, allowing the weaker end of the stent to expand freely in the IVC, while the stronger main body could perform as required at the site of compression. Using the same reasoning, significant overlap of stents without leaving bare segments is recommended to avoid stent collapse in the mid-portion of a diseased vein.

What was not foreseen with this adapted technique was the occurrence of contralateral iliofemoral deep vein thrombosis (DVT).³ With the Wallstent extended into the IVC, contralateral iliac blood flow is restricted through the closed-cell stent interstices, which likely develops a thin neointimal layer over time. This process may be similar to that seen with gradual IVC filter occlusion and is more common in patients not on anticoagulation. The overall incidence of DVT has been reported to range from 3% to 10% over time. Consequently, proper technique with the Wallstent now includes the use of a Z-stent to buttress the cranial edge of the stent in the CIV, which provides strength and compression resistance without needing to extend the Wallstent into the IVC (Figure 1).⁴

The second limitation of the Wallstent is the lack of deployment accuracy and precision due to its braided-design matrix. Although it adds greater flexibility through

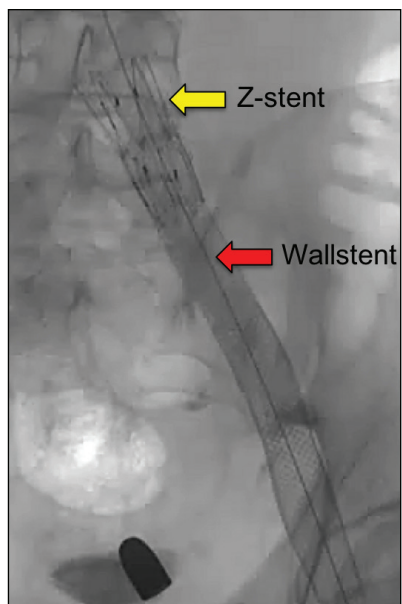


Figure 1. Iliac vein stenting using a Wallstent and a Z-stent.

tortuous curves and across the inguinal ligament, there is significant shortening of the stent as it expands during deployment, which is only worsened by postdilatation. Precise placement depends on the operator's best assessment of where the stent edge will come to rest once fully deployed and dilated, a difficult

task even in experienced hands. This is of little concern for the patient with a long segment of healthy landing zone but presents a significant challenge for patients with postthrombotic syndrome (PTS) who often require common femoral vein (CFV) treatment precisely to the femoral confluence for maximum benefit. The danger is leaving even a short segment of diseased CFV between the stent edge and the profunda/femoral confluence as a result of stent shortening, whether it is flow-limiting or not; this is often enough to lead to early stent thrombosis. Although experience helps to master an acceptable level of precision with the Wallstent, unpredictability remains a significant challenge with this design.

was first described in 2014.⁴ Deployment of the Z-stent in combination with the Wallstent has been well described in the literature. The proper technique involves landing the Wallstent within the iliac vein right up to but not into the IVC, followed by reinforcement with the Z-stent by positioning roughly 75% of the Z-stent within the previously placed Wallstent; this technique leaves approximately one-quarter of the Z-stent's length protruding into the IVC. When employed correctly, this technique prevents collapse of the cranial edge of the Wallstent, while also reducing the consequences of contralateral DVT over time.³ Furthermore, this technique facilitates bilateral CIV stenting by allowing the stent to mesh together without luminal compromise, effectively recreating the caval confluence. Lastly, the Z-stent has been described both as a primary stent and as an adjunct to the Wallstent within the IVC, commonly used at stent edges or across junctions (eg, renal or hepatic veins).² In my practice, I prefer to use the Z-stent as an adjunct to Wallstents because of anecdotal evidence of caval erosion when used as a primary stent. Nonetheless, both techniques have been used with success. The use of the Z-stent in the venous system is currently an off-label use.

Despite the shortcomings of the Wallstent, it remains a sturdy and reliable stent for treating outflow obstruction of the IVC and iliac veins, especially when used in combination with the Z-stent. The Wallstent has the largest experience and longest documented clinical results of any available venous stent. Moreover, the clinical results of this stent are what propelled the field forward. Although the Wallstent currently does not have an FDA indication for use in the venous system, Boston Scientific Corporation is in the process of applying to the FDA for a venous indication.

task even in experienced hands. This is of little concern for the patient with a long segment of healthy landing zone but presents a significant challenge for patients with postthrombotic syndrome (PTS) who often require common femoral vein (CFV) treatment precisely to the femoral confluence for maximum benefit. The danger is leaving even a short segment of diseased CFV between the stent edge and the profunda/femoral confluence as a result of stent shortening, whether it is flow-limiting or not; this is often enough to lead to early stent thrombosis. Although experience helps to master an acceptable level of precision with the Wallstent, unpredictability remains a significant challenge with this design.

A STEP FORWARD: Z-TRACHEOBRONCHIAL STENT AND INTRODUCER SYSTEM

The Z-stent was designed as a tracheobronchial stent but has found use in the venous system for chronic venous obstructions, initially implanted in the superior vena cava and then in the IVC.^{5,6} Use of the Z-stent in the iliac veins

THE NEXT GENERATION: DEDICATED NITINOL VENOUS STENTS

Currently, there are seven dedicated venous stents available in Europe, all of which have received CE Mark and been used in both trial and real-world applications. In the United States, four stents have entered various phases of United States investigational device exemption (IDE) trials. All four trials (VIRTUS, VIVO, VERNACULAR, and ABRE) have completed enrollment, and three have completed 1-year follow-up. Two platforms have received FDA approval in 2019—Venovo (BD Interventional) and Vici (Boston Scientific Corporation). The current landscape for United States and European venous stents is summarized in Table 1, and Figure 2 illustrates the stents that have entered US IDE trials.

Nitinol Stent Design

The newest generation of venous stents is composed of nitinol-based self-expanding platforms. Differences in stent design result in distinctive stent properties and behaviors intravenously, but there are also many similarities. Nearly all stent matrices are composed of nonbraided nitinol, with the notable exception of the Blueflow venous stent (plus medica GmbH & Co. KG), a braided nitinol stent not available in the United States. Furthermore, most new stents have improved flexibility to some degree by using an open-cell design matrix; the exception is the Vici venous stent, which is based on a closed-cell design.

A nonbraided stent design is advantageous for improved precision and accuracy during deployment without

TABLE 1. VENOUS STENT DEVICES

Device (Manufacturer)	CE Mark Approval	FDA Approval
Abre (Medtronic)	2017	Pending approval
Blueflow (plus medica GmbH & Co. KG)	2018	—
sinus-Obliquus (optimed Medizinische Instrumente GmbH)	2015	—
sinus-Venous (optimed Medizinische Instrumente GmbH)	2013	—
Wallstent (Boston Scientific Corporation)	2015	*
Venovo (BD Interventional)	2015	2019
Vici (Boston Scientific Corporation)	2013	2019
Zilver Vena (Cook Medical)	2010	Pending approval

*Applying for FDA approval outside of investigational device exemption trial.

significant stent foreshortening. Generally, nonbraided stents can be predictably deployed at the caval confluence if care is taken to identify the confluence precisely with intravascular ultrasound (IVUS). Z-stents should not be needed to support these stent designs because the ends should be as strong as the main body of the stents. Precise distal landing should also be improved.

For the most part, the minimal foreshortening seen with nitinol stents is secondary to the small mismatch between the expected stent length determined by IVUS measurements (which takes the straightest path feasible through the iliac veins) and the observed length of implanted stents (which follows the centerline iliac curve more fittingly). Of note, most of the nitinol stents discussed herein have constrained lengths that match their nominal lengths. One exception is the Vici stent, which demonstrates approximately 20% foreshortening between the constrained length and the implanted length upon deployment (per the instructions for use). This is because Vici's curved bridges straighten when crimped, resulting in a longer-appearing stent when constrained on the catheter. Nonetheless, the implanted length should be near-nominal or the intended length when sized properly.

Another improvement seen with the new stent generation is an increase in the available stent lengths in each portfolio (Table 2). With the need to treat long segments of disease typically encountered in postthrombotic venous patients, as well as the need to anchor stents used for May-Thurner lesions in healthy veins distally, dedicated venous stents are now available in longer lengths. Generally, isolated stents < 80–100 mm should be used with caution and may be associated with higher migration or embolization rates. In true PTS, where the patient has had prior iliofemoral venous thrombosis, it is rare to have healthy vein remaining. Stents in these patients often extend from the caval confluence to the profunda femoral confluence, spanning

lengths ≥ 160 mm. Although Wallstents have been available in a maximum length of 90 mm in the most commonly used sizes (16- and 18-mm diameters), newer nitinol stents are available in lengths between 120 to 160 mm depending on the platform (Table 2). The availability of longer stent lengths combined with more accurate and precise landing capability, as well as the ability to plan for a shorter overlap of stents, will likely result in fewer stents required per case.

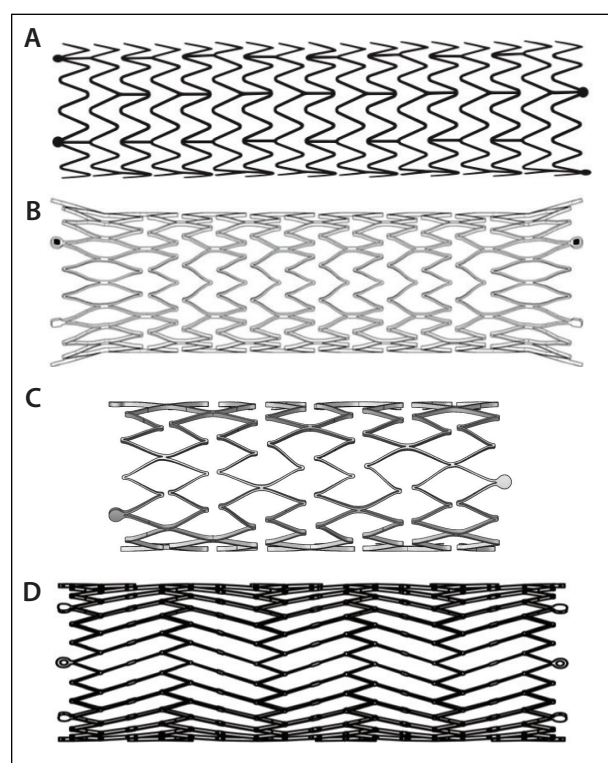


Figure 2. First-generation nitinol venous stents (Zilver Vena [A], Venovo [B], Abre [C], and Vici [D]) stents that have entered into or completed a United States IDE trial.

TABLE 2. DEDICATED VENOUS STENT PORTFOLIOS COMPARED WITH THE WALLSTENT

	Wallstent	Vici	Zilver Vena	Venovo	Abre
Stent layout	Braided	Closed cell	Open cell	Open cell	Open cell
Diameter, mm	14, 16, 18, 20, 22, 24*	12, 14, 16	10, 12, 14, 16	10, 12, 14, 16, 18, 20	10, 12, 14, 16, 18, 20
Stent lengths, mm (diameter, mm)	60 (14–18), 70 (20, 24), 90 (14–18), 80 (20), 70 (24) [†]	60, 90, 120 [‡]	40 (10, 12), 60 [‡] , 100 [‡] , 140 [‡]	40, 60, 80, 100, 120, 140, 160 [‡]	40 (10), 60 [‡] , 80 [‡] , 100 [‡] , 120 [‡] , 150 [‡]
Size, F (diameter, mm)	10 (14, 16), 11 (18–22), 12 (24)	9	7	8, 9 (14), 10 (16–20)	9
Delivery	Coaxial	Coaxial	Coaxial	Triaxial dual thumbwheel	Triaxial thumbwheel
Catheter working length, cm	75*	100	80, 120 [§]	80, 120 [§]	90
<p>*Information on sizes < 14 mm not included.</p> <p>[†]Lengths < 60 mm are available but not listed.</p> <p>[‡]Available for all stent diameters.</p> <p>[§]Available for all stent diameters and lengths.</p>					

All dedicated venous stents are available in 14- and 16-mm diameters, which are expected to be the most commonly used sizes for nitinol stents deployed in the iliac veins. Although Wallstents have traditionally been sized larger than this, nitinol stents are not as forgiving to oversizing; the use of stents larger than normal venous anatomy can result in prolonged back and groin pain without any obvious clinical gains. The catheter profiles are all comparable, especially considering an 8-F sheath is the most commonly used for IVUS, and most interventionalists use a 10- or 11-F sheath to accommodate the large-diameter balloons used for pre- and postdilatation. Interventionalists should be familiar with the different delivery systems and comfortable with the catheter working lengths.

TRIAL DESIGN SIMILARITIES AND DISTINCTIONS

As the first class of dedicated venous stents comes to market, each is accompanied by a unique set of trial data and instructions for use. In the United States, FDA approval is based on successful demonstration of safety and efficacy in a thorough IDE trial. However, despite many similarities in their designs and the overlap in their timing, it is important to keep in mind that there are significant differences as well (Table 3).

Because the trials were not designed specifically for the uniformity to allow for cross-comparison, gleaming insights into the performance of one platform versus another based solely on IDE data may prove to be a challenging if not misleading exercise. Understanding the unique designs and their potential impact on resultant data is essential not only

in evaluating the current platforms and how they apply to patients outside the trial setting, but also to enhancing our ability to design future studies, building on the lessons learned from the current class of trials.

Candidacy and Categorization

All four United States IDE trials were multicenter and single arm in design. The number of patients in each trial varied slightly, but each included close to 200 patients. The baseline trial eligibility requirements were the same across VIRTUS, VERNACULAR, and ABRE and included a documented iliofemoral obstruction $\geq 50\%$ in the presence of a CEAP (clinical, etiology, anatomy, and pathophysiology) score ≥ 3 , a Venous Clinical Severity Score (VCSS) of 2, or both. The VIVO trial varied from this in that the presence of symptomatic iliofemoral outflow obstruction was also required, but the severity of stenosis required (ie, 50%) was not specified. The first three trials initiated (VIVO, VIRTUS, and VERNACULAR) all determined presence of and/or degree of stenosis according to diameter differences on venography. The ABRE trial, the most recently initiated study, also allowed for inclusion of patients with $\geq 50\%$ area reduction on IVUS, a tool that has gained increasing acceptance as a more accurate way to measure venous stenosis.

In addition to eligibility requirements, patient inclusion and categorization definitions were not standardized across trials, which should be considered when reviewing each data set (especially if attempting to compare across them). The management of acute DVT patients in these trials is one of these distinct differences. In VIRTUS, these patients were excluded. The VERNACULAR trial included acute DVT

TABLE 3. VENOUS STENT UNITED STATES IDE TRIAL DESIGN

Trial	VIRTUS	VIVO	VERNACULAR	ABRE
Device	Vici	Zilver Vena	Venovo	Abre
Type	Multicenter, single arm	Multicenter, single arm	Multicenter, single arm	Multicenter, single arm
Patients (N)	200	243	170	200
Eligibility	<ul style="list-style-type: none"> • CEAP "C" \geq 3 and/or VCSS \geq 2, AND • \geq 50% iliofemoral venous outflow obstruction 	<ul style="list-style-type: none"> • CEAP "C" \geq 3 and/or VCSS \geq 2, AND • Iliofemoral venous outflow obstruction 	<ul style="list-style-type: none"> • CEAP (C) \geq 3 and/or VCSS \geq 2, AND • \geq 50% iliofemoral venous outflow obstruction 	<ul style="list-style-type: none"> • CEAP "C" \geq 3, VCSS \geq 2, and/or acute DVT, AND • \geq 50% iliofemoral venous outflow obstruction
Imaging for eligibility	<ul style="list-style-type: none"> • Diameter reduction on venography 	<ul style="list-style-type: none"> • Diameter reduction on venography 	<ul style="list-style-type: none"> • Diameter reduction on venography 	<ul style="list-style-type: none"> • Diameter reduction on venography/IVUS, OR • Area reduction on IVUS
Acute DVT inclusion	No	Yes	Yes	Yes
Patient cohorts	<ul style="list-style-type: none"> • Postthrombotic • Nonthrombotic 	<ul style="list-style-type: none"> • Acute (< 30 d symptoms) • Chronic (\geq 30 d symptoms, including subacute DVT, postthrombotic, non-thrombotic) 	<ul style="list-style-type: none"> • Postthrombotic (included acute DVT) • Nonthrombotic 	<ul style="list-style-type: none"> • Acute DVT • Postthrombotic • Nonthrombotic
Primary effectiveness endpoint	12-mo primary patency Freedom from: <ul style="list-style-type: none"> • Reintervention • Occlusion, thrombosis • In-stent restenosis $>$ 50% by <i>venography</i> 	12-mo primary patency Freedom from: <ul style="list-style-type: none"> • In-stent restenosis $>$ 50% or occlusion by <i>venography</i> 	12-mo primary patency Freedom from: <ul style="list-style-type: none"> • Reintervention • Occlusion, thrombosis • In-stent restenosis $>$ 50% by <i>DUS</i> 	12-mo primary patency Freedom from: <ul style="list-style-type: none"> • Reintervention • Occlusion, thrombosis • In-stent restenosis $>$ 50% by <i>DUS</i> (confirmed by <i>venography</i>)
Safety endpoint	30-day MAE	30-day MAE	30-day MAE	30-day MAE
CE Mark	Yes	Yes	Yes	Yes
FDA approval	Yes (2019)	Anticipated 2020	Yes (2019)	Anticipated 2021
Abbreviations: CEAP, clinical, etiology, anatomy, and pathophysiology; DUS, duplex ultrasound; IVUS, intravenous ultrasound; MAE, major adverse event; VCSS, Venous Clinical Severity Score.				

patients; however, they were placed in the PTS arm of the trial. Because the VIVO trial categorized patients from time of symptom onset, enrolling patients as acute (< 30 days from symptom onset) and chronic (> 30 days from symptom onset), most truly acute patients ended up in the acute group. Some subacute DVT patients ended up in the chronic arm, such that a proportion of patients in the chronic arm required lysis for DVT treatment as part of their care.

The ABRE trial included patients with acute DVT as a distinct patient cohort, defined as within 14 days from symptom onset. Patients with subacute or early chronic DVT, defined as > 14 days from symptom onset to 6 months, were excluded; after 6 months from symptom onset, they could be entered into the postthrombotic arm.

The management of patients with chronic disease also varied between the groups. The VIVO trial ultimately had

TABLE 4. SUMMARY OF COMPLETED UNITED STATES IDE TRIALS FOR VENOUS STENTS

	Vici Venous stent	Venovo Venous Stent
Trial	VIRTUS	VERNACULAR
Patients (N)	170 (pivotal cohort)	170
Patient/lesion characteristics	75% postthrombotic; 25% nonthrombotic	55% postthrombotic; 45% nonthrombotic
Mean lesion length	111 mm	67.8 mm
Mean stent length	149.8 mm	100.6 mm
Median stent length	120 mm	Not yet reported
Efficacy endpoint	12-month primary patency, 84% (79.8% postthrombotic; 96.2% nonthrombotic)	12-month primary patency, 88.3% (81.3% postthrombotic; 96.9% nonthrombotic)
Safety endpoint	30-day freedom from MAE, 98.8%	Overall freedom from MAE, 93.5%
Abbreviations: IDE, investigational device exemption; MAE, major adverse event.		

a diverse group of patients in its chronic arm. In addition to a lack of full separation of all DVT from the chronic cohort, both nonthrombotic and postthrombotic patients were included, and there are well-documented differences in outcomes after stenting in these groups. Although efforts were made to separate out nonthrombotic and PTS patients in the VIRTUS, VERNACULAR, and ABRE trials, the lack of clarity in defining these conditions made this challenging.

In the author's experience, most PTS patients have very diseased iliac veins extending from the femoral/profunda confluence or below, so the expectation would be for increased lengths of stented segments in this population. The trials reported to date have included relatively short lesion and median stent lengths⁷ as well as fewer stents extending below the infrainguinal ligament compared to what might be seen in real world practice for PTS patients. The ABRE study also sought to separate PTS and non-PTS patients; however, as this trial is still in the initial follow-up period, it is yet to be seen whether discrepancies between these groups will be apparent.

Until universal definitions for postthrombotic disease are developed and agreed upon, it is likely there will be variance and some uncertainty regarding the chronic subgroups across all stent trials. However, the differences in patient categorization seen in the current trials do not invalidate the primary endpoint analyses. They highlight the need to be thoughtful before drawing conclusions about the outcomes of PTS patients versus non-PTS patients; the included patient groups may be more heterogeneous in these studies than initially intended. Prudence is therefore also needed when comparing the chronic or PTS subsets across trials, because again there may or may not be homogeneity among them. As a field, we need to decide what truly defines PTS to better inform the transition from clinical trials to clinical practice.

Endpoint Analyses

The effectiveness endpoints were the same between three of the four trials, including freedom from reintervention, in-stent restenosis > 50%, and stent occlusion. The exception was the VIVO trial, where the endpoint was primary qualitative patency alone. Failure of quantitative patency occurred when there was a restenosis > 50% (which included occlusions). Thus, a reintervention for < 50% stenosis was not considered a failure of the primary effectiveness endpoint in the VIVO study, whereas it was in the other trial designs. What varied further between the trials was the means to determine a successful endpoint. Both the VIRTUS and VIVO trials used venography at 12 months to determine patency. The VERNACULAR trial instead used duplex ultrasound to determine 12-month patency, which is more consistent with routine clinical practice. The ABRE trial also used duplex ultrasound to determine the endpoint; however, it also required venography if the 12-month endpoint was not met or if the duplex ultrasound was nondiagnostic.

Overall, the differences in imaging requirements to determine both eligibility and success across these trials may reflect an evolution that mirrors current clinical practice. Clinical trends are moving away from reliance on venography and toward the use of both noninvasive duplex ultrasound and IVUS.

Early Trial Results

Although none of the United States IDE trials have come to formal publication yet, early summary data have been released for the VIRTUS trial evaluating the Vici venous stent and the VERNACULAR trial assessing the Venovo venous stent. Overall, both studies exceeded their primary effectiveness and safety endpoints and demonstrated feasibility as well as clinical success. Currently available results are shown in Table 4.⁷⁻⁹

Vici stent. The VIRTUS trial met its efficacy endpoint with a primary patency of 84% at 1 year.⁸ The primary safety endpoint was also met, with a freedom from 30-day major adverse events of 98.8%. Significant improvement in VCSS has been presented. A total of 10 patients (10/170 [5.9%]) had stent fractures in this trial, with an overall stent fracture rate of 3.6% (10/281) for the total number of implanted stents.¹⁰ The majority of fractures (9 of 10 reported) occurred in stents that extended into the CFV, though it appears that at most, half of all patients may have stents that extended below the inguinal ligament.

In Europe, use of the Vici stent also demonstrated no safety issues, and cumulative primary stent patency rates were 87% and 100% in the PTS and non-PTS cohorts, respectively.¹¹

Venovo stent. Primary patency of the VERNACULAR trial at 1 year was 88.3%, exceeding the goal of 74%. Likewise, the safety endpoint was met with an overall freedom from major adverse events of 93.5%.⁹ No fractures were reported in this trial; however, only a small portion of stents were extended into the CFV.

The Arnsberg venous registry also released data demonstrating an overall 6-month primary patency rate of 98% and a secondary patency rate of 100%. In addition, significant decreases in revised VCSS were reported.¹²

Venous Stent Fractures

The prevalence and long-term sequelae of venous stent fractures are not yet fully understood. Because most of stents placed in the trials reported so far likely do not extend below the CFV, we do not yet have a firm understanding the potential for fracture, which may increase below the inguinal ligament. Stent fractures may or may not equate to a clinical problem, and although some stents may require relining, the remainder may be asymptomatic. At the 1-year point in VIRTUS, the fractures that had occurred did not appear to have an impact on patency, as the fractured stents for all 10 patients were patent at this visit. None of the patients experienced symptoms related to their stent fractures, and no interventions were required as a result of the fractures in this trial. Further, 2-year cumulative patency has been reported for 101 stented limbs landing above and below the inguinal ligament at 90% and 79%, respectively.¹³ This difference was not statistically significant. If concerned, to avoid fractures at the groin, one consideration is to combine a nitinol stent cranially with a Wallstent extension distally, although this technique has not been formally evaluated. There has been limited corrosion testing

in this scenario without concerning results to date. Likewise, corrosion testing of nitinol and stainless steel also appears to be relatively benign.¹⁴

CONCLUSION

Although there is still much to be learned about venous stents and trial design, one cannot deny that progress is underway. At many international congresses, seats that used to be empty in the venous sessions are now full. CE Marked and FDA-approved venous stents translate into funding for venous trials and education, which means increased opportunities for patients worldwide who experience a condition that previously had no significant treatment options and was, to a large extent, disregarded by the vascular community. FDA IDE trials mean we have well-collected data sets available for review. New product designs mean the opportunity is at our fingertips to cautiously push the limits and discover the next frontiers of venous stenting, with the goal of ultimately improving patient outcomes. ■

1. Raju S. Best management options for chronic iliac vein stenosis and occlusion. *J Vasc Surg*. 2013;57:1163-1169.
2. Murphy EH, Johns B, Varney E, Raju S. Endovascular management of chronic total occlusions of the inferior vena cava and iliac veins. *J Vasc Surg Venous Lymphat Disord*. 2017;5:47-59.
3. Murphy EH, Johns B, Varney E, et al. Deep venous thrombosis associated with caval extension of iliac stents. *J Vasc Surg Venous Lymphat Disord*. 2017;5:8-17.
4. Raju S, Ward M Jr, Kirk O. A modification of iliac vein stent technique. *Ann Vasc Surg*. 2014;28:1485-1492.
5. Kishi K, Sonomura T, Mitsuzane K, et al. Self-expandable metallic stent therapy for superior vena cava syndrome: clinical observations. *Radiology*. 1993;189:531-535.
6. Joshi A, Carr J, Chrisman H, et al. Filter-related, thrombotic occlusion of the inferior vena cava treated with a Gianturco stent. *J Vasc Interv Radiol*. 2003;14:381-385.
7. Marston W. Improvement in quality of life after iliac vein stenting in a prospective clinical study of a nitinol venous stent. Presented at: American Venous Forum Annual Meeting; February 21, 2019; Rancho Mirage, CA.
8. Razavi MK. VIRTUS clinical trial: 12-month data. Presented at: Leipzig Interventional Course; January 22-25, 2019; Leipzig, Germany.
9. Dake M. 12-month results from the Venovo venous stent trial. Presented at: Vascular Interventional Advances conference; November 5-8, 2018; Las Vegas, Nevada.
10. Vici Venous Stent System [instructions for use]. Marlborough, MA: Boston Scientific Corporation; 2019.
11. Lichtenberg M, Breuckmann F, Stahlhoff WF, et al. Placement of closed-cell designed venous stents in a mixed cohort of patients with chronic venous outflow obstructions – short-term safety, patency, and clinical outcomes. *Vasa*. 2018;47:475-481.
12. Lichtenberg MKW, de Graaf R, Stahlhoff WF, et al. Venovo venous stent in the treatment of non-thrombotic or post-thrombotic iliac vein lesions – short-term results from the Arnsberg venous registry. *Vasa*. 2019;48:175-180.
13. Black S, Gwozdz A, Karunaniythy N, et al. Two year outcome after chronic iliac vein occlusion recanalisation using the Vici venous stent. *Eur J Vasc Endovasc Surg*. 2018;56:710-718.
14. Venugopalan R, Trepanier C, Pelton AR. Galvanic corrosion behavior of passivated nitinol. Presented at: Transactions of the Sixth World Biomaterials Congress; May 15-20, 2000; Hilton Waikoloa Village Resort, Kamuela (Big Island), Hawaii.

Erin H. Murphy, MD, FACS

Director, Venous and Lymphatic Institute
Sanger Heart and Vascular, Atrium Health
Charlotte, North Carolina
erinmurphy79@gmail.com

Disclosures: Consultant to Boston Scientific Corporation, Medtronic, Cook Medical, and Vesper. Principal investigator, ABRE trial.