

Indigo® System for Thromboembolic Disease

WITH FRANK R. ARKO III, MD; SCOTT L. STEVENS, MD; JAMES F. BENENATI, MD;
CHRISTOPHER W. BOYES, MD; PAUL PERKOWSKI, MD; LAUREL H. HASTINGS, MD;
MIKEL SADEK, MD; CHANDRAHAS PATEL, MD; AND JOS C. VAN DEN BERG, MD, PhD



Frank R. Arko III, MD

Chief, Vascular and Endovascular Surgery
Professor, Cardiovascular Surgery
Co-Director, Aortic Institute
Sanger Heart and Vascular Institute
Atrium Health
Charlotte, North Carolina
frank.arko@carolinashealthcare.org
Disclosures: Consultant to Penumbra, Inc.



Scott L. Stevens, MD

Professor of Surgery
Director of Endovascular Surgery
University of TN Medical Center-Knoxville
Knoxville, Tennessee
sstevens@utmck.edu
Disclosures: None.

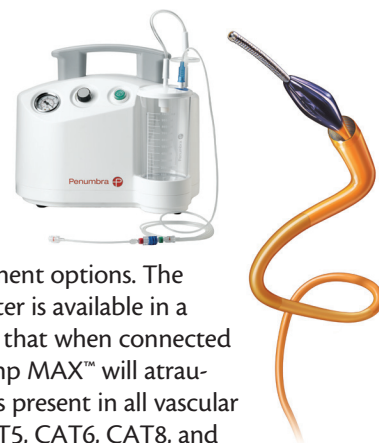Thromboembolic disease comprises a group of disorders that crosses into the arterial and venous vascular beds and a combination of both vascular beds in hemodialysis arteriovenous fistulas. Arterial thrombus is typically a result of atherosclerotic plaque rupturing, launching the body into the clotting cascade, and resulting in platelet activation/aggregation, which then results in thrombus. Venous thrombus, which encompasses deep vein thrombosis (DVT) and pulmonary embolism (PE), is typically the result of the following underlying sources: Virchow's triad of endothelial damage, hemostasis, and hypercoagulability—the occurrence of two of these three noted factors results in thrombus formation. Pulmonary thrombus typically involves the travel of a blood clot in the leg to the pulmonary artery, causing an acute occlusion. In the arterial vascular bed, the patient is symptomatic early on, and at the time of treatment, the thrombus is typically in the acute phase. In the venous vascular bed, the patient develops symptoms later, and at the time of treatment, the thrombus may be in the acute/subacute and/or chronic phase.

Due to differing thrombus morphology, the traditional endovascular treatment options that have existed have been associated with high complication rates and intensive care unit (ICU) stays. Complications have included bleeding, distal emboli, vessel damage, incomplete revascularization, and kidney damage. One recent study reports a 29% risk of kidney injury with rheolytic thrombectomy.¹ Furthermore, the ATTRACT trial recently

showed that catheter-directed lysis for venous thrombosis carries a significant bleeding risk.²

The Indigo® System (Penumbra, Inc.) has been designed to address the limitations of the traditional treatment options. The Indigo System aspiration catheter is available in a range of lengths and diameters that when connected to Penumbra's proprietary Pump MAX™ will atraumatically remove the thrombus present in all vascular beds. The catheters (CAT3, CAT5, CAT6, CAT8, and CATD) vary in diameters from 3.4 to 8 F and lengths of 50 to 150 cm to enable the operator to remove thrombus from small vessels, such as the pedal arch, to large vessels, such as the inferior vena cava (IVC).

The Indigo System was created to remove thrombus in peripheral artery occlusions based on the success of the Penumbra System® in the neurovasculature for reperfusion of large vessel occlusions in stroke patients. At our institutions, we first used the Penumbra System to remove arterial emboli in cases where patients had no other options to reperfuse the affected area and conventional treatment options would have fallen short. The neurotracking technology of these catheters simplified thrombus removal in hard-to-reach distal vessels. As a result of these early results in the peripheral anatomy, Penumbra developed a line of peripherally focused catheters for use with the Indigo System, starting



with the CAT3 catheter and CAT5 catheter to address small vessel arterial occlusions, then the CAT6 catheter and CAT8 catheter were introduced to address larger arterial and venous occlusions, and finally the CATD catheter to address thrombus removal in hemodialysis arteriovenous fistulas. Since the initial launch of the Indigo System, the catheters and techniques have progressed, resulting in high rates of revascularization in all vascular beds with low complication rates. In our institutions, the Indigo System has become the frontline tool for clot removal in the body. We are seeing excellent technical and long-term outcomes, including reduced need for hospital ICU stays (thereby reducing hospital costs), kidney injury rates, and bleeding complications.

In the arterial vascular bed, the Indigo System and XTRACT technique have enabled operators to safely remove the entire clot intact and treat the culprit lesion, as shown in the PRISM trial.³ In the venous vascular bed, in light of the ATTRACT trial advocating a reduction in the dose and duration of tissue plasminogen activator (tPA), the Indigo System with the coring technique (and tPA

turbo infusion, when needed) has enabled operators to remove the clot in a single setting in a vast majority of cases, as highlighted in Hastings and Perkowski's DVT experience.⁴ Finally, in the arteriovenous fistula and graft setting, the Indigo System has enabled operators to remove clot quickly, even in aneurysmal fistulas, and this has been demonstrated through Marcelin et al's fistula experience in Europe.⁵ Additionally, in the pulmonary vasculature, a US Food and Drug Administration investigational device exemption trial is currently underway to investigate the use of the Indigo System for PE. The following case reports highlight the Indigo System's progression in each vascular bed.

1. Escobar GA, Burks D, Abate MR, et al. Risk of Acute kidney injury after percutaneous pharmacomechanical thrombectomy using Angiojet in venous and arterial thrombosis. *Ann Vasc Surg*. 2017;42:238-245.
2. Vedantham S, Goldhaber SZ, Julian JA, et al. Pharmacomechanical catheter-directed thrombolysis for deep-vein thrombosis. *N Engl J Med*. 2017;377:2240-2252.
3. Saxon RR, Benenati JF, Teigen C, et al. Pharmacomechanical catheter-directed thrombolysis for deep-vein thrombosis. *N Engl J Med*. 2017;377:2240-2252.
4. Hastings LH, Perkowski PE. Single session percutaneous mechanical aspiration thrombectomy for symptomatic proximal deep venous thrombosis. Poster presented at: SAVS 42nd Annual Meeting; January 17-20, 2018; Scottsdale, AZ.
5. Marcelin C, D'Souza S, Le Bras Y, et al. Pharmacomechanical catheter-directed thrombolysis for deep-vein thrombosis. *N Engl J Med*. 2017;377:2240-2252.

POWER ASPIRATION-BASED XTRACT TECHNIQUE FOR BELOW-THE-KNEE ARTERIAL CLOT REMOVAL



James F. Benenati, MD

Medical Director, Noninvasive Vascular Laboratory
Fellowship Program Director
Miami Cardiac and Vascular Institute
Miami, Florida
Clinical Associate Professor of Radiology
University of South Florida College of Medicine
Tampa, Florida
jamesb@baptisthealth.net
Disclosures: Consultant for Penumbra, Inc.

The PRISM study was a retrospective case analysis conducted to determine the utility of the power aspiration-based XTRACT technique (Figure 1) as an initial and a secondary approach in the treatment of peripheral arterial thromboembolism. Prior to use of the Indigo System, the patients had TIMI (thrombolysis in myocardial infarction) scores of 0 or 1. The primary outcome was the rate of TIMI 2–3 revascularization after Indigo System intervention and at the end of procedure with balloon and stenting of the underlying lesion (Table 1). TIMI 2–3 flow was achieved in 87.2% of patients immediately after use of the Indigo System and in 96.2% of patients at the

end of the entire procedure (Table 2). In addition, there were no device-related adverse events.

This study showed that the XTRACT technique was safe and effective for revascularization of acute or sub-acute peripheral arterial occlusions as primary therapy or as a secondary therapy after other endovascular techniques had failed.

CASE REPORT

Patient Presentation

A woman in her 80s presented to the emergency department with 1 week of worsening intermittent left leg pain, tingling, numbness, and coldness. The patient had a history of hypertension, hyperlipidemia, and was a previous smoker. Arterial left extremity duplex map-

TABLE 1. INDIGO SYSTEM TREATMENT MODALITY

Used frontline	49.4%
Used after thrombolytics	15.2%
Used after other mechanical therapy	19.0%
Used after both thrombolytics and mechanical therapy	16.5%

TABLE 2. PRISM TRIAL PRIMARY OUTCOMES

	TIMI 2–3 Revascularization (n/N)
After Indigo System use	87.2% (74/78)
At the end of the procedure	96.2% (76/79)
Abbreviations: TIMI, thrombolysis in myocardial infarction.	

ping revealed thrombus in the popliteal artery, anterior tibial artery, and posterior tibial artery.

Case Summary

- Contralateral access was gained using a 6-F Destination® sheath (Terumo Interventional Systems), tracking the sheath as far distally as possible, and initial angiography was performed confirming the duplex mapping findings (Figure 2).
- We chose the largest, nonocclusive catheter that would fit in the vessel for aspiration—in this case, the CAT6 catheter was chosen. The Indigo System CAT6 catheter was connected to the proprietary Pump MAX and the XTRACT technique was utilized. The Indigo System CAT6 catheter was used to successfully aspirate the popliteal artery thrombus, and then the anterior and posterior tibial arteries were subselected with CAT6 and the thrombus burden was aspirated (Figure 3).
- After Indigo System aspiration, final angiography was performed, confirming complete thrombus resolution and patent blood flow (Figure 4).

DISCUSSION

Adapting the Indigo System to my practice has changed my treatment algorithm when treating arterial occlusions, whether it is an acute thrombotic event or emboli from atrial fibrillation. Tracking the largest, nonoc-

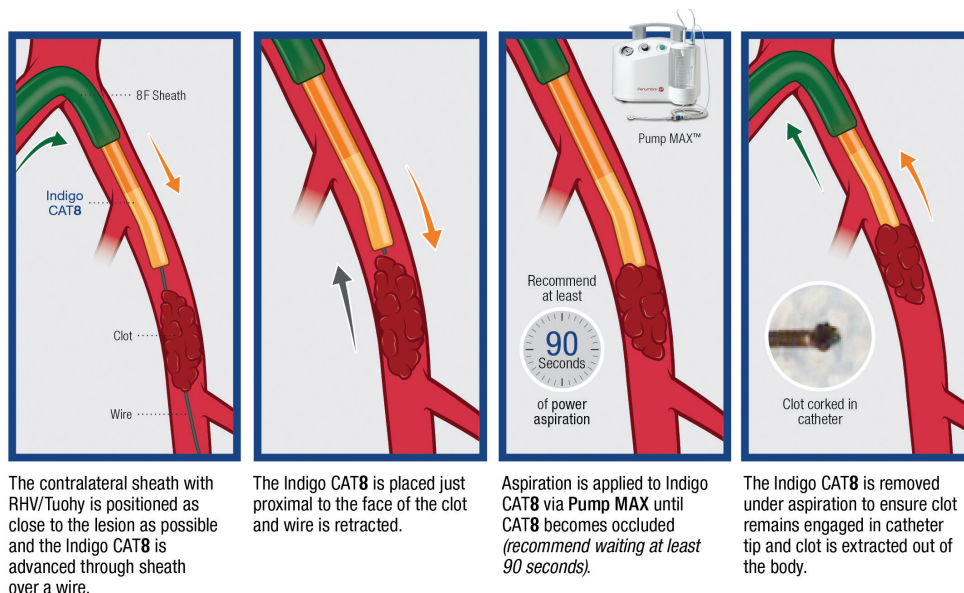


Figure 1. The XTRACT technique, as described in the PRISM trial.

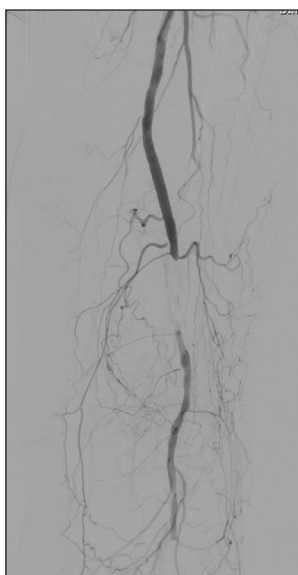

Figure 2. Initial angiogram confirming the duplex mapping.

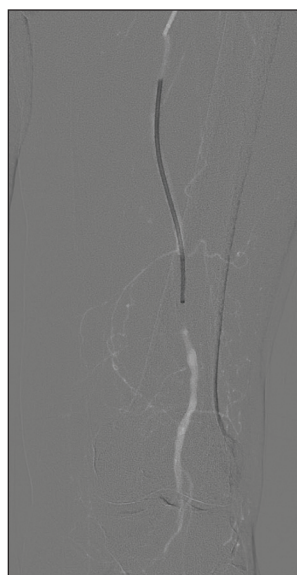


Figure 3. The Indigo System CAT6 being tracked to the popliteal artery.

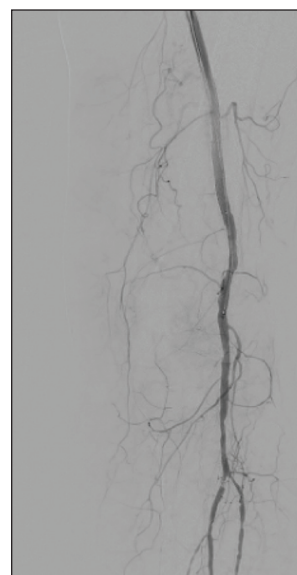


Figure 4. Final angiogram confirming thrombus resolution.

clusive catheter to the thrombi or emboli—in most cases, the 8-F CAT8 catheter—enables the operator to remove the obstruction intact with no distal emboli and treat the potential culprit lesion. In the past, there was not a “lights out” option for removing arterial thrombus; however, with the Indigo System, we are able to achieve high revascularization rates (87.2% TIMI 2–3 after Indigo System use) and have seen reliable success in clearing arterial obstructions.

INDIGO SYSTEM ASPIRATION PRE-DCB IN COMPLEX CLI



Christopher W. Boyes, MD

Vascular Surgeon
Sanger Heart and Vascular Institute
Atrium Health
Charlotte, North Carolina
chris.boyes@atriumhealth.org

Disclosures: None.

CASE REPORT

Patient Presentation

A woman in her 50s presented with left calf claudication symptoms for over a year when walking 50 feet. She has a history of a left superior femoral artery (SFA) stent that was placed several years ago. Arterial duplex mapping confirmed an occlusion of this SFA stent. We elected to perform left lower extremity angiography and an intervention.

Case Summary

- Contralateral access was gained using a 6-F Destination sheath and initial angiography was performed, revealing a chronically occluded SFA stent with reconstitution of the above-knee popliteal artery and adequate tibial runoff to the foot (Figure 1).
- We elected to perform mechanical thrombectomy using the Indigo System CAT6 catheter connected to continuous aspiration from the Pump MAX to remove any potential thrombus that may be present in the stent to mitigate the risk of distal intraprocedural embolization. This will also provide a clean

surface of intimal hyperplasia within the stent to optimize drug transfer with drug-coated balloon (DCB) angioplasty. One, 2-minute pass was made through the lesion with the CAT6 catheter. Postaspiration angiography was performed, revealing successful thrombectomy and visualization of a clean in-stent stenosis (Figure 2).

- The SFA stent lesion was ballooned using a 6-mm DCB for 3 minutes.
- Final angiography after Indigo System aspiration and DCB angioplasty revealed patent flow through the SFA stent with no distal embolism (Figure 3).

DISCUSSION

The treatment of peripheral vascular disease has evolved over the years. Our understanding of the complex morphology of lesions continues to grow. Innovation and technology have provided many options for treating a wide variety of these lesions. This includes endovascular mechanical thrombectomy.

For many years, aspiration or mechanical thrombectomy was used as a bailout option for embolism during the treatment of peripheral vascular disease. Recently, technology has allowed us to rethink how we approach many of these complex morphology lesions. We can now use the Indigo System as a primary treatment resource for peripheral vascular disease in order to reduce the risk of intraprocedural embolization and to truly expose the underlying culprit lesion. This is especially important for treating critical limb ischemia (CLI) as the use of the Indigo System in complex CLI cases can be the difference in a 15-minute versus a 2-hour battle with distal embolization.

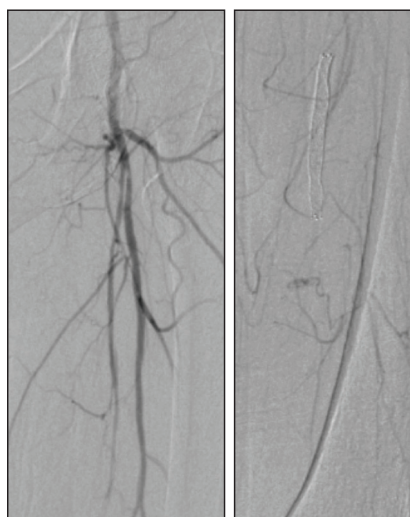

Figure 1. Preprocedural angiogram revealing occluded SFA stents with collateral fill to the lower extremity anatomy.

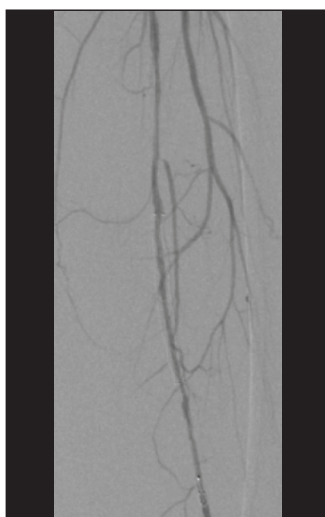

Figure 2. Angiogram postaspiration with CAT6 catheter revealing thrombus resolution.

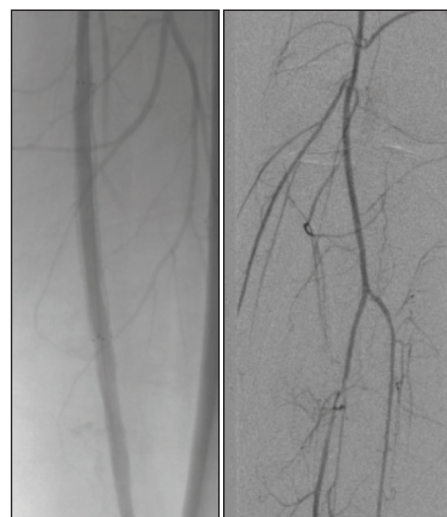

Figure 3. Posttreatment angiogram showing patent flow throughout leg.

BENEFITS OF COMPLETE CLOT REMOVAL USING THE INDIGO SYSTEM



Paul Perkowski, MD

Clinical Associate Professor of Surgery
Louisiana State University Health Sciences Center
Chief, Division of Vascular Surgery
Our Lady of the Lake Regional Medical Center
Baton Rouge, Louisiana
pperkowski@vesbr.com

Disclosures: Consultant and speaker for Penumbra, Inc.



Laurel H. Hastings, MD

Clinical Associate Professor of Surgery
Assistant Professor of Clinical Surgery
Our Lady of the Lake Regional Medical Center
Baton Rouge, Louisiana
laurel.hastings@cvts.com

Disclosures: None.

The ATTRACT trial, a randomized controlled trial funded by the National Institutes of Health, compared pharmacomechanical thrombolysis to anticoagulation for treatment of DVT and failed to meet the primary outcome of reduction of postthrombotic syndrome in the treatment arm. The trial showed that treatment with pharmacomechanical thrombolysis led to a statistically significant higher incidence of major bleeding. In addition, the conventional devices used at the time of ATTRACT were only able to remove 76% of the thrombus on average.

As a result of the lessons learned from the ATTRACT trial, modern clot removal tools and techniques that reduce the dose and duration of tPA are warranted. Our study at Louisiana State University aimed to evaluate the safety and efficacy of percutaneous thrombus removal using the Indigo System in patients with proximal symptomatic DVT.¹

Our study was a retrospective review, with a primary endpoint of technical success defined by restoration of blood flow with minimal residual thrombus (< 10%) without the need for a second treatment session using the Indigo System. Eighteen patients met the study criteria of having an occlusive proximal iliofemoral DVT with observation over a 12-month period. Primary technical success (> 90% thrombus removal) was achieved in 77.78% of patients (14/18) with only a single treatment session in 83.33% of patients (15/18). Freedom of reintervention at 6 months was 88.89% (16/18), and the two patients with recurrent DVT were asymptomatic. There were no device-related adverse events. These data are summarized in Table 1.

TABLE 1. SINGLE-SESSION PERCUTANEOUS MECHANICAL ASPIRATION THROMBECTOMY FOR SYMPTOMATIC PROXIMAL DVT

tPA on table	7/18 (38.89%)
Adjunctive measures	10/18 (55.56%)
Percent thrombus clearance	> 90% in 14/18
Single session	15/18 (83.33%)
Recurrence	2/18 (11.11%)

Abbreviations: DVT, deep vein thrombosis; tPA, tissue plasminogen activator.

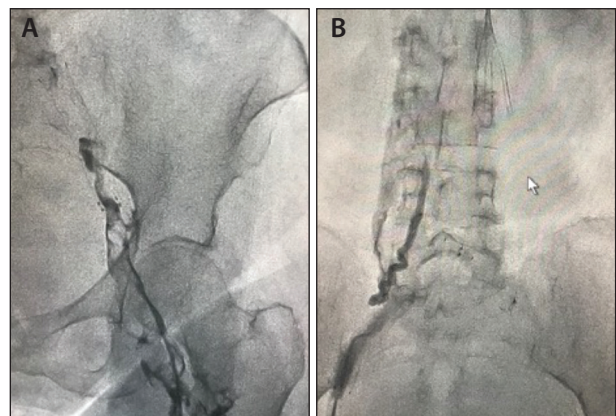


Figure 1. Initial venograms of both the left (A) and right (B) legs demonstrating DVT occlusions.

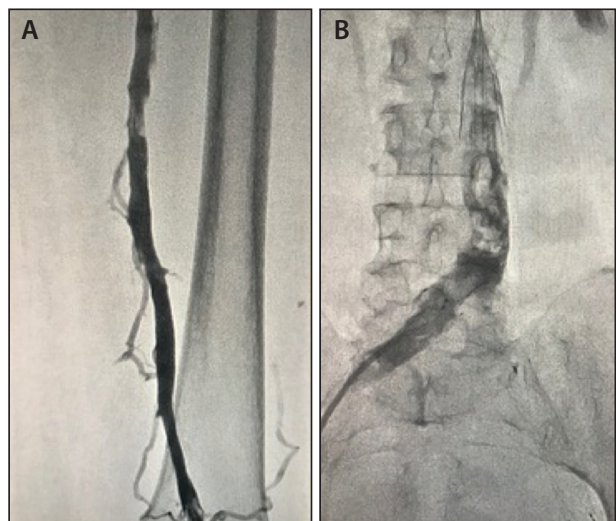


Figure 2. Postprocedure venogram revealing patent femoropopliteal (A) and iliac vein (B) segments.

CASE REPORT

Patient Presentation

A woman in her 70s presented with history of left leg DVT. The patient did well for 2 years after the first DVT

treatment but then developed occlusive thrombus in her right iliac vein. The patient underwent right iliac stenting to resolve a right leg DVT and a filter was placed because the patient was a fall risk. The patient returned to our care with severe right leg swelling and ultrasound examination confirmed an extensive right femoropopliteal and iliofemoral DVT and a left iliac stent occlusion, both extending into the IVC filter.

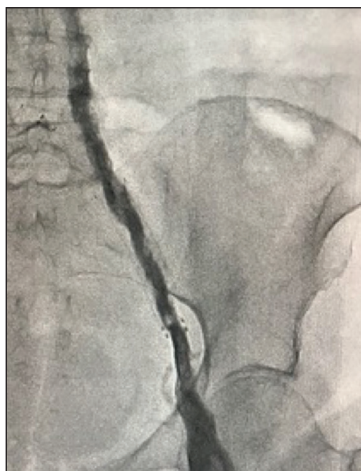

Figure 3. Venogram after Indigo System aspiration, highlighting a patent left iliac stent.

the right iliac vein and through the previously placed stents into the vena cava (Figure 2). The coring technique utilizes macro movements with the CAT8 catheter and SEP8 separator to extract the acute thrombus, as well as the wall-adherent clot present in DVTs.

- The CAT8 XTORQ catheter, SEP8 separator, and Pump MAX were used to aspirate the occlusion in the left iliac vein stent (Figure 3).
- The Indigo System was used once more on final pass to resolve the residual wall-adherent clot on the left and right. Both iliac stents underwent balloon angioplasty, final venography was performed, and the patient was discharged on the same day on rivaroxaban.

DISCUSSION

In such large, extensive DVTs, conventional treatment methods involve larger doses of tPA for longer infusion times with the associated bleeding risk, as was evidenced in the ATTRACT trial. Conventional rheolytic thrombectomy involves clot maceration and is associated with bradycardia and distal embolic complications such as PE, limiting its use to a small number of patients. In our experience, continuous power aspiration with the Indigo System relies on powerful vacuum technology to extract the thrombus using a low-profile, highly trackable 8-F system and is associated with minimal complications, along with reduction in tPA dosage. Prospective multicenter studies are needed to validate the results seen in our single-center experience, but the initial results are encouraging and have prompted us to adopt the Indigo System as a frontline option for our DVT patients.

1. Hastings LH, Perkowski PE. Single session percutaneous mechanical aspiration thrombectomy for symptomatic proximal deep venous thrombosis. Poster presented at: SAVS 42nd Annual Meeting; January 17–20, 2018; Scottsdale, AZ.

Case Summary

- The patient was placed in the prone position and left leg popliteal access was gained using a short 8-F Pinnacle® sheath (Terumo Interventional Systems). Venography revealed that the thrombus extended up into the vena cava to the filter in both the left and right legs (Figure 1).
- The CAT8 XTORQ catheter and SEP8 separator were connected to continuous aspiration and the Pump MAX was used to core the clot and remove the right leg thrombus in the popliteal vein, all the way up into

INDIGO SYSTEM IN CONTRAINDICATED BILATERAL DVT



Mikel Sadek, MD

Assistant Professor, Department of Surgery
NYU Langone Medical Center
Chief, Vascular Surgery
Bellevue Hospital Center
New York, New York
Mikel.Sadek@nyumc.org
Disclosures: None.

CASE REPORT

Patient Presentation

A man in his 50s presented with bilateral lower extremity thrombosis following bilateral ilioacaval venous thrombosis. Due to recent orthopedic surgery and his history of venous thromboembolism, it was important to revascularize the deep venous system in

order to mitigate the risk of developing postthrombotic syndrome. Therefore, the decision was to place an IVC filter and use the Indigo System to revascularize, thus mitigating the need for tPA in a contraindicated patient.

Case Summary

- The patient was placed in the prone position, and his bilateral popliteal veins were accessed with 10-F Pinnacle sheaths.
- The Indigo System's CAT8 XTORQ catheter, SEP8 separator, and Pump MAX were first used through the right popliteal access, working centrally starting with the popliteal vein all the way up into the IVC. Vessel patency was established on the right side.
- The CAT8 XTORQ catheter and SEP8 separator were then used to aspirate the thrombus burden on the patient's left side in same manner, starting at the popliteal vein and moving centrally up to the IVC.

- The final venogram confirmed patency of the deep venous system, and no other lytic agents were needed.

DISCUSSION

Penumbra's Indigo System helps to achieve prompt technical success in arterial and venous thrombo-

embolic disease. The Indigo System relies on power aspiration to remove the thrombus and not tPA to macerate/dissolve; therefore, it is one of the only options for patients with contraindications, as in this case report.

SINGLE-SESSION MECHANICAL THROMBECTOMY WITH THE INDIGO SYSTEM



Chandrabhas Patel, MD

Thoracic/Vascular Surgeon
Arizona Vascular & Thoracic Solutions
Glendale, Arizona
hossapatel@yahoo.com

Disclosures: None.

CASE REPORT

Patient Presentation

A woman in her 70s was admitted to our center due to a symptomatic acute right lower extremity DVT, which was confirmed via ultrasound imaging.

Case Summary

- Access was gained using an 11-cm, 8-F Pinnacle sheath, and initial venography was performed revealing extensive iliofemoral DVT (Figure 1).
- Due to the subacute nature of the thrombus burden, it was decided that tPA would be used to soften the clot before removing the thrombus burden with power aspiration via the Indigo System. The clot was infused with 12-mg of tPA using a turbo lysing technique (Figure 2):
 - We selected the appropriate infusion catheter length,

matching the length of the thrombus burden to the length of the infusion catheter for even tPA distribution. In this case, a 30-cm Craig-McNamara® infusion catheter (Medtronic) was selected.

- Next, 12 mg of tPA was mixed with 8 mL of saline in a 20-mL syringe. A three-way stopcock was placed at the back end of the infusion catheter, and the 20-mL syringe with tPA and 3-mL syringe were locked in. The tPA was transferred from the 20-mL syringe to the 3-mL syringe and then distributed throughout the clot burden to maximize tPA infusion.
- A dwell time of 10 minutes was completed.
- After the appropriate dwell time, the Indigo System CAT8 XTORQ catheter, SEP8 separator, and Pump MAX were used to remove the thrombus burden from the body. Using macromovements with the CAT8 XTORQ catheter, we were able to achieve complete thrombus resolution (Figure 3), and the patient was discharged the next day.

DISCUSSION

Prior to the introduction of the Indigo System, the options for DVT thrombus removal were limited.

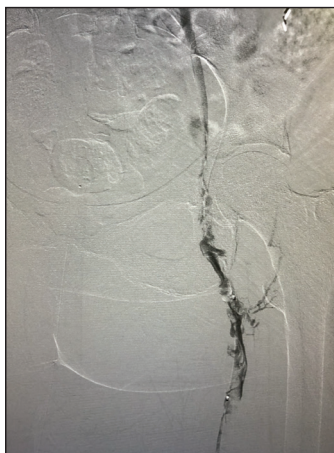


Figure 1. The initial venogram showing extensive iliofemoral DVT.

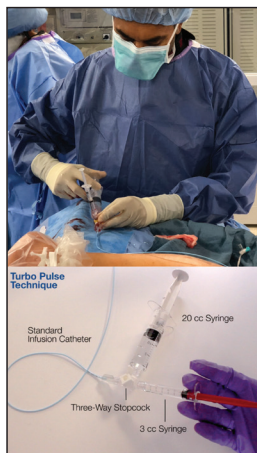

Figure 2. Turbo infusion setup.

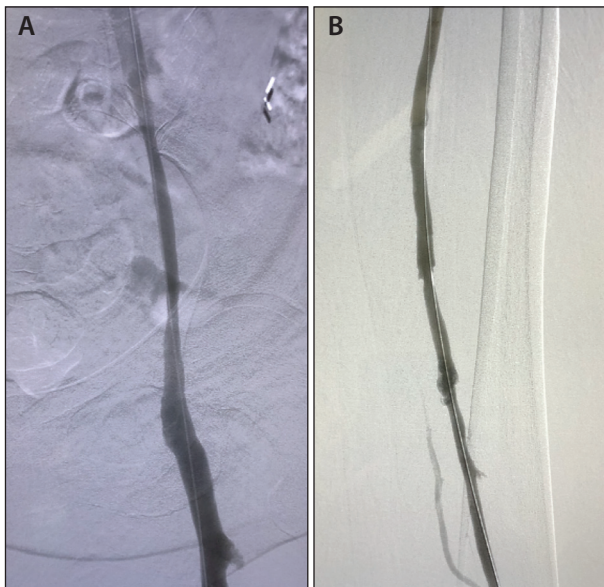


Figure 3. Final venogram exhibiting complete thrombus resolution in the iliac segment (A) and in the lower femoral segment (B).

The interventionalist could either use a long-duration and large-dose of tPA to dissolve the thrombus or use the rheolytic/maceration to break apart the thrombus. Complications with these conventional techniques included bleeding and distal embolization. Use of the Indigo System helps to achieve single-session DVT

treatment with potentially reduced dose and duration of tPA, thus reducing the risk of bleeding. The use of power aspiration to remove thrombus also potentially reduces distal embolization and can safely remove thrombus.

ENDOVASCULAR TREATMENT OF AN OCCLUDED DIALYSIS FISTULA



Jos C. van den Berg, MD, PhD

Head of Service of Interventional Radiology
Ospedale Regionale di Lugano
Lugano, Switzerland
jos.vandenberg@eoc.ch

Disclosures: Consultant to Penumbra, Inc.

A recent case series reported the results of thrombus aspiration in 35 patients with acutely thrombosed dialysis fistulas.¹ All procedures were performed within 48 hours of the occurrence of thrombosis. Technical success of clot removal from an arteriovenous fistula and/or graft using the Indigo System was 97.1% and clinical success, defined as a successful dialysis session after the procedure, was 91.4%. There were no technical or device-related complications. The average procedure time was 38.1 minutes, and the average blood loss during the procedure was 122.5 mL. At a mean follow-up of 8.5 months, five patients underwent a second aspiration for recurrent thrombosis of the dialysis fistula, and two patients had a restenosis treated with balloon angioplasty. The 6-month primary patency, primary assisted patency, and secondary patency rates were 71%, 80%, and 88.5%, respectively.

CASE REPORT

Patient Presentation

A woman in her 60s presented to our center with an acute occlusion of an arteriovenous fistula in

her left antecubital fossa. Dialysis 2 days earlier was uneventful, although recirculation was noted, with a suspicion of a stenosis of the postanastomotic area. Physical examination revealed absence of a thrill over the shunt. Dialysis was attempted but was not possible.

Case Summary

- Phlebography through a 4-F sheath confirmed occlusion of the fistula (Figure 1). An exchange was made for an 8-F sheath with a detachable valve.
- Thrombus aspiration using the CAT8 XTORQ catheter was performed. After the initial passage, partial reconstitution of flow was seen (Figure 2).
- After additional passages with the same aspiration catheter, full restoration of the lumen was observed, and an underlying high-grade stenosis was revealed (Figure 3).
- This stenosis was dilated with a 5- X 40-mm standard angioplasty balloon, with good angiographic outcome (Figure 4). The patient underwent dialysis immediately after the procedure and was able to continue dialysis in the months thereafter.

DISCUSSION

The Indigo System is a useful adjunct for the treatment of acute dialysis fistula occlusion, with a high technical success rate and low complication rate. ■

1. Marcelin C, D'Souza S, Le Bras Y, et al. Mechanical thrombectomy in acute thrombosis of dialysis arteriovenous fistulae and grafts using a vacuum-assisted thrombectomy catheter: a multicenter study [published online May 30, 2018]. *J Vasc Interv Radiol*.

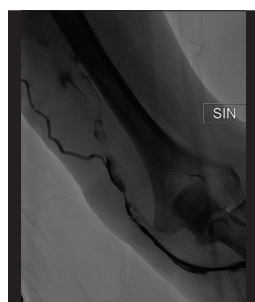

Figure 1. Phlebography showing the occluded fistula.

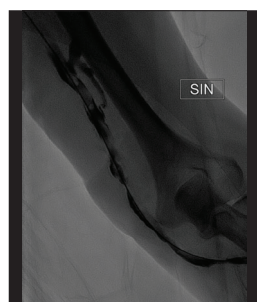

Figure 2. Partial reconstitution of flow after initial thrombus aspiration.

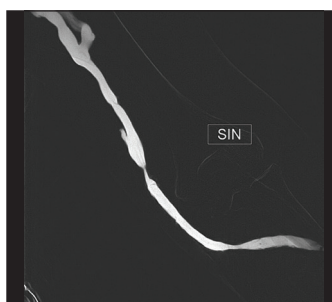

Figure 3. Full restoration of the lumen and the underlying high-grade stenosis.

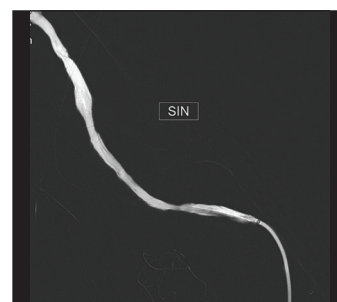


Figure 4. Angiographic results after stenosis dilation.