

Treating Venous Thromboembolism Without Lytic Medications

What the present and the near future will bring in terms of techniques and devices to remove venous thrombus.

BY CONSTANTINO S. PEÑA, MD; RIPAL T. GANDHI, MD; AND JAMES F. BENENATI, MD

The hallmark of percutaneous thrombus management over the last 2 decades has been the use of catheter-based thrombolytic infusion. The inability to significantly and consistently remove thrombus, along with the risk of downstream embolization and thrombosis propagation, has made mechanical thrombectomy techniques adjuncts to thrombolytic infusions. The chronicity of the thrombus is also important in the effectiveness of catheter-based thrombolytic infusions. Thrombolytics allow for dissolution of acute and subacute thrombus, as they may help to soften chronic thrombus. However, this is controversial and anecdotal, and chronic thrombus is usually dilated and potentially stented once blood flow has been established. The costs of catheter-based thrombolytic infusion therapies are related to the amount of drug that is used, the time needed for infusion, the level of hospital care during the infusion, and the potential risk of bleeding and serious complications.

There are economic and patient safety reasons to attempt to reduce the time necessary for thrombus removal and to eliminate or potentially reduce the necessity for prolonged thrombolytic infusion. There are many patients in whom the use of thrombolytic infusion is contraindicated, and thus, devices have been developed to attempt to remove enough thrombus in order to reestablish flow and hopefully reduce or eliminate the need for thrombolytics. These catheter-based devices can be categorized as those that fragment thrombus and those that extract thrombus.¹

THROMBUS FRAGMENTATION

There are a number of devices that can be used to macerate thrombus. These can be characterized into two general types: (1) catheter-based macrofragmentation and (2) device microfragmentation. In macrofragmentation, a standard catheter is used to agitate and break up vein thrombus in an attempt to improve or reestablish flow. An operator may take a catheter (eg, pigtail catheter) and rotate it with the use of a guidewire in an attempt to fragment large vein thrombus and re-establish some form of distal blood flow. This technique is usually reserved for patients with massive pulmonary embolism in which a catheter may be rotated or agitated in the pulmonary artery. These are unstable patients who cannot wait for lytic therapy to start functioning. Usually, this catheter fragmentation technique is followed with an infusion of thrombolytics or thrombus aspiration.

The second type of devices is predominantly used and approved for the treatment of thrombosed arteriovenous grafts. We have particular experience with the Arrow-Trerotola percutaneous thrombolytic device (Arrow International, a division of Teleflex), which is a 6-F catheter that can be opened within the vessel to expose a soft metal cage that is then rapidly rotated using a battery-powered mechanism within the handle of the device. Additionally, we have also used the Cleaner device (Argon Medical Devices, Inc.), which is a similar 6-F device with a small, quadrangular-shaped wire configuration that also spins

CASE 1

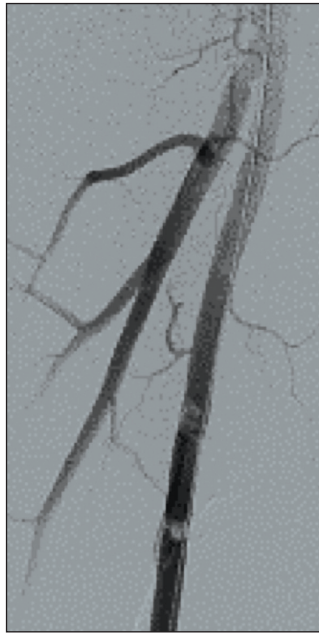


Figure 1. A 61-year-old man with two areas of thrombus within the superficial femoral artery.

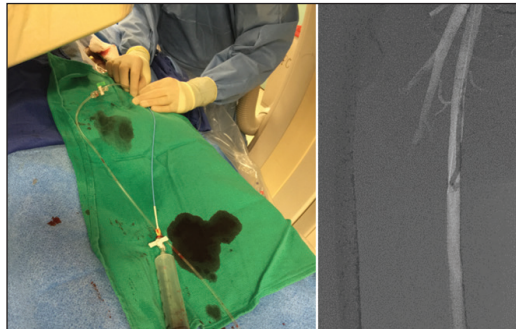


Figure 2. Catheter aspiration using a 60-mL syringe and a 6-F Envoy catheter.

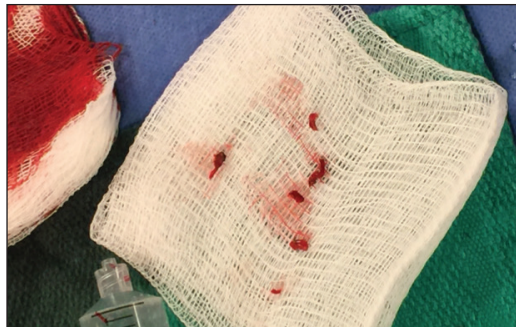


Figure 3. The thrombus removed.

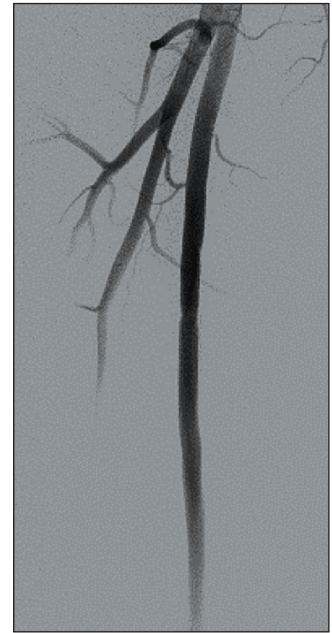

Figure 4. Angiogram demonstrating no residual thrombus after two passes.

CASE 2

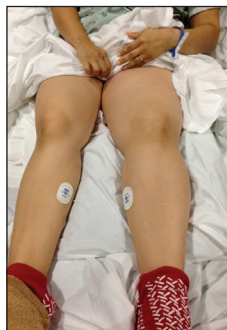

Figure 1. A 21-year-old woman with ulcerative colitis and gastrointestinal bleeding presented with significant left lower extremity pain and edema.

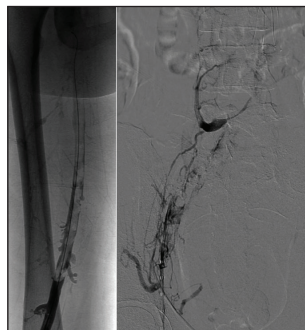


Figure 2. A venogram via a popliteal approach showed extensive iliofemoral deep vein thrombosis (DVT).

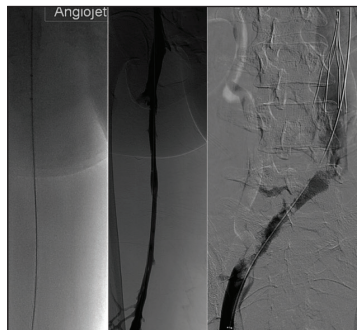

Figure 3. Initial imaging demonstrates use of the AngioJet Solent thrombectomy system alone. The patient could not receive thrombolytics because of gastrointestinal bleeding from ulcerative colitis.

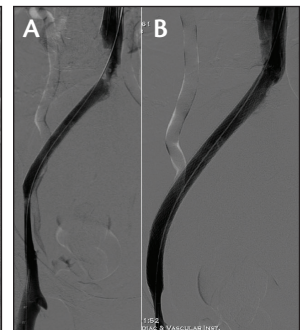


Figure 4. Placement of a 20-mm Wallstent (Boston Scientific Corporation) (A). Given the presence of persistent narrowing proximally, an additional 24-mm Wallstent was placed, which allowed excellent flow (B). The patient's symptoms and edema resolved within days.

CASE 3

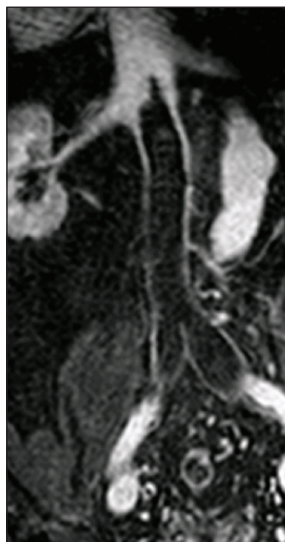


Figure 1. A 72-year-old man with a history of rectal bleeding from colonic adenocarcinoma presented with marked bilateral lower extremity and scrotal edema and pain. Magnetic resonance venography shows ilio caval DVT to the level of an IVC filter placed just below the renal veins.

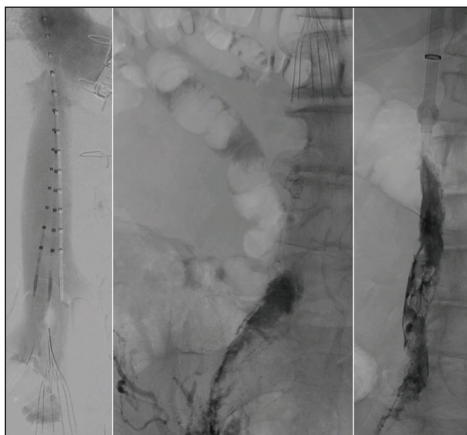


Figure 2. A venogram demonstrates ilio caval thrombosis with a small amount of thrombus noted at the IVC filter hook.

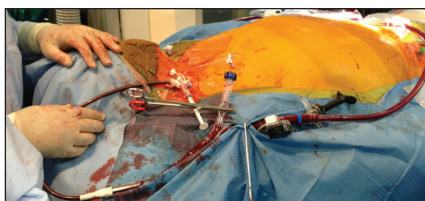


Figure 3. A 22-F AngioVac device is advanced via the right internal jugular vein, with the 16-F reinfusion cannula placed via the left internal jugular vein. The patient was put on extracorporeal bypass.

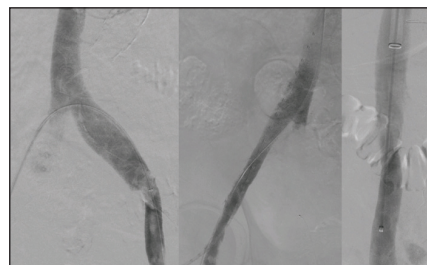


Figure 4. Final venogram after AngioVac thrombectomy demonstrating a patent IVC and iliac veins. Thrombolytics were not used due to the presence of rectal bleeding. The patient's symptoms improved after the intervention.

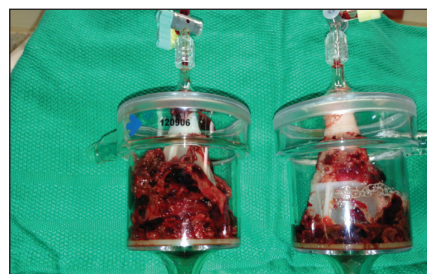

Figure 5. An image showing the thrombus removed during the procedure.

and macerates thrombus. These devices are limited in that they do not extract the macerated thrombus. In the best of situations, they can macerate the thrombus into very small particles that are then sent centrally as flow is reestablished. They are usually limited by their short working shafts and by the amount of thrombus that they can actually treat without aspiration or removal. Newer generations of these devices have longer working lengths and are more clinically versatile.

THROMBUS EXTRACTION

The largest group of percutaneous mechanical devices to treat venous thromboembolic disease involves those that attempt to extract thrombus. These range from traditional catheters that can be used to extract thrombus, to specific devices that aspirate thrombus. The use of a catheter to aspirate a small amount of thrombus has been used as the first-line treatment for distal embolization for many years. Now, there are special catheters designed for aspiration/extraction of thrombus, such as the Export (Medtronic),

Fetch2 (Boston Scientific Corporation), QuickCat (Spectranetics Corporation), and Pronto (Vascular Solutions, Inc.) catheters.

These systems rely on a limited amount of manual syringe-generated suction aspiration and are typically used in the arterial tree for distal, limited embolization. Their advantage is that they are routinely available and can usually safely remove thrombus or plaque emboli, allowing quick restoration of flow. The size of the catheter lumen, length of the catheter, and degree of aspiration suction limit the amount of material that can be extracted with each pass, and therefore, they are not typically used for larger-volume venous thrombosis (case 1).

Rheolytic catheter devices have been used successfully for thrombus extraction for over 15 years. The AngioJet thrombectomy device (Boston Scientific Corporation) is a catheter-based, over-the-wire device that uses high-pressure saline jets within the catheter to create a vacuum at the catheter tip (Bernoulli effect), drawing the thrombus into the inflow windows where the jets macerate and push the

Case 4 (Courtesy of Juan Gomez, MD)

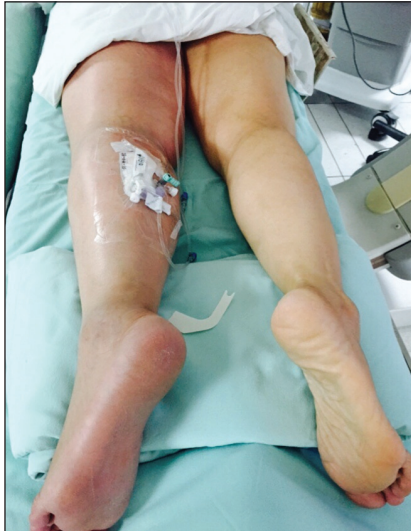

Figure 1. A 54-year-old woman with a history of left greater saphenous vein ablation 1 month prior presented with significant left lower extremity pain and edema.

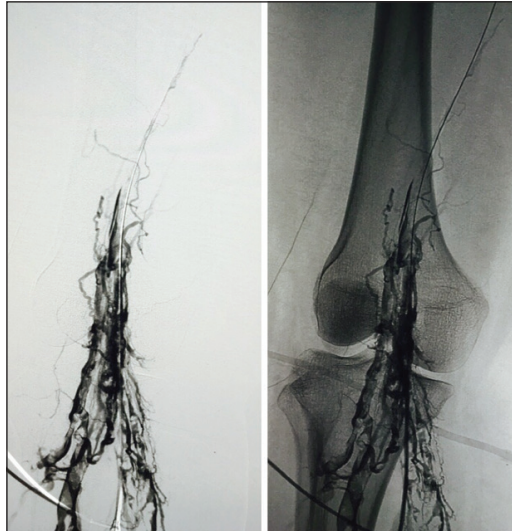


Figure 2. Noninvasive imaging (A) and subsequent venography (B) via a popliteal approach showed extensive left lower extremity iliofemoral DVT.

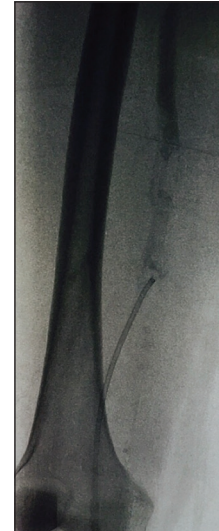

Figure 3. Despite overnight catheter-directed thrombolysis with tissue plasminogen activator, there was minimal response. The patient then underwent thrombectomy with the Indigo percutaneous mechanical thrombectomy system.

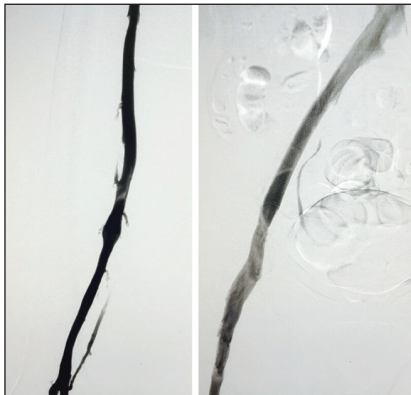


Figure 4. After mechanical thrombectomy and stenting of the left common iliac vein with a Wallstent, there was an excellent venographic result with rapid flow.

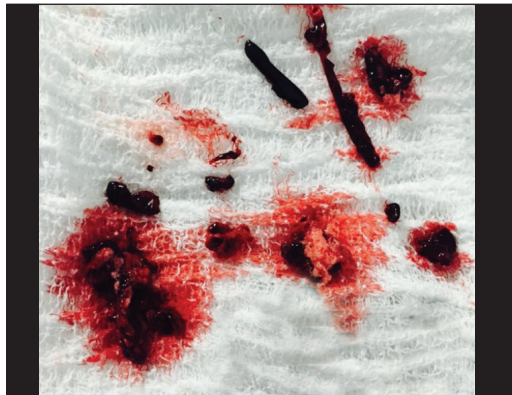

Figure 5. Thrombus removed with the Indigo system. The patient's symptoms resolved almost completely within 24 hours, and she is currently asymptomatic and on anticoagulation.

thrombus back down the catheter and into a collection bag. There are catheters that are compatible with 0.014- and 0.035-inch guidewires that work with 4- to 6-F sheaths. The type and size of the catheter used depends on the diameter of the vessel and thrombectomy power desired.

The PEARL I and II (Peripheral Use of Angiojet Rheolytic Thrombectomy With Mid [and a Variety of] Length Catheters) registries demonstrated significant improvement in clot resolution in both acute and chronic thrombus. Only 5% of enrolled patients were treated without the use of thrombolytics; however, a large number of patients in the

venous arm of the PEARL registry were successfully treated in ≤ 6 hours (38%) and ≤ 24 hours (75%). Furthermore, the CAVENT trial found that catheter-directed thrombolysis required approximately 48-hour thrombolytic infusions to treat DVT.²

When using the Angiojet catheter, distal emboli can be limited by slowly aspirating the thrombus proximally (peripherally in the venous system) and preserving the most central aspect of the thrombus until the proximal thrombus has been cleared. Technically, the amount of aspiration is limited by the diameter of the Angiojet catheter and by

catheter run times. By following guidance on catheter run times, and with appropriate patient hydration (pre- and postprocedure), the hemolysis is usually self-limited. In larger veins, the AngioJet catheter has been used with an angled guiding catheter, which is rotated in a spiraling fashion to create a treatment arc and, subsequently, a larger-diameter aspiration lumen.³ The use of the AngioJet device in the larger central veins, especially those in the thorax, can be associated with bradyarrhythmias. This is usually self-limited and improves with powering off and removal of the device. Atropine can be an adjunct, as well. For these reasons, use of this device is off-label in the pulmonary arteries (case 2).⁴

The need for large-volume thrombectomy, which is often necessary in the treatment of venous thromboembolism, led to the development of the AngioVac system (AngioDynamics, Inc.), which consists of a 22-F, balloon-actuated expandable tip that enables high flow and is connected to a circuit for extracorporeal bypass. While the patient is being treated under extracorporeal bypass, the blood is aspirated via the 22-F device and passed through a filter, which captures thrombus and other particulate material before the blood is recirculated back into the patient via a 16-F reinfusion sheath.

The AngioVac cannula is intended for use as a venous drainage cannula and for the removal of fresh, soft thrombi or emboli during extracorporeal bypass for up to 6 hours in vessels such as the inferior vena cava (IVC), superior vena cava, and right atrium. Not only does this device enable removal of large amounts of acute, subacute, and chronic thrombus, it is accomplished with virtually no hemolysis and minimal procedural blood loss because the aspirated blood is reinfused. The second-generation AngioVac device was recently released and offers several improvements over the earlier device, with the most important being the availability of an angled 20° tip, which aids in device navigation, and the addition of a Y adapter with Touhy insert, which allows for over-the-wire capability through the working sideport and accommodates up to an 18-F adjunctive device (case 3).

NEW TECHNOLOGIES

The use of catheters connected to controlled, continuous suction to aspirate and remove thrombus has been used successfully to extract cerebral arterial thrombus in the treatment of acute stroke.⁵ Similar catheter technology has been developed for use in the periphery, such as the Indigo aspiration system (Penumbra, Inc.). This 5-F catheter system uses a uniquely reinforced but soft-tipped catheter that is connected to a novel suction generator to aspirate thrombus into the catheter. The system can also be used along with a separator that functions as a curved wire that

can be extruded from the end of the catheter to clear the catheter and allow continued aspiration (case 4). Until recently, the use of the Indigo system had been somewhat limited in the central venous system due to the relatively small sizes of the devices. However, the recent introduction of both a 6- and 8-F catheter system should continue to improve larger-vessel aspiration for the treatment of venous thromboembolism. In May 2015, the US Food and Drug Administration cleared the Indigo embolectomy aspiration system for the removal of fresh, soft emboli and thrombi from vessels of the peripheral arterial and venous systems; this approval encompasses the larger 6- and 8-F sizes as well.

CONCLUSION

There are several catheter-based techniques available for the treatment of venous thromboembolism, including catheter-directed thrombolysis, mechanical thrombectomy, and pharmacomechanical thrombectomy. Although thrombolysis has traditionally been a first-line treatment option, the increasing armamentarium of innovative mechanical thrombectomy devices is changing the treatment landscape, with mechanical techniques becoming a very important adjunct or stand-alone therapy for this disease. Device selection depends on the clinical scenario, as well as operator preferences, with certain systems being better suited for certain applications. Continued research and comparative data will hopefully improve our knowledge in terms of efficacy of thrombus removal, clinical improvement, and cost effectiveness, with the ultimate goal of improving patient outcomes. ■

Constantino S. Peña, MD, is an interventional radiologist with Miami Cardiac and Vascular Institute in Miami, Florida. He has disclosed that he has served on advisory boards for Boston Scientific, CR Bard, and Penumbra.

Ripal T. Gandhi, MD, is an interventional radiologist with Miami Cardiac and Vascular Institute in Miami, Florida. He has stated that he has no financial interests related to this article.

James F. Benenati, MD, is an interventional radiologist with Miami Cardiac and Vascular Institute in Miami, Florida. He has disclosed that he has served on an advisory board for Penumbra. Dr. Benenati may be reached at jamesb@baptisthealth.net.

1. O'Sullivan G. Thrombolysis versus thrombectomy in acute deep vein thrombosis. *Interv Cardiol.* 2011;3:589-596.
2. Enden T, Haig Y, Klow NE, et al. Long-term outcome after additional catheter-directed thrombolysis versus standard treatment for acute iliofemoral deep vein thrombosis (the CAVENT study): a randomised controlled trial. *Lancet.* 2012;379:31-38.
3. García MJ. A treatment algorithm for DVT. *Endovasc Today.* 2014;13:38-40.
4. Kuo WT. Endovascular therapy for acute pulmonary embolism. *J Vasc Interv Radiol.* 2012;23:167-179.
5. Mocco J, Zaidat O, von Kummer R, et al. Results of the THERAPY trial: a prospective, randomized trial to define the role of mechanical thrombectomy as adjunctive treatment to IV rtPA in acute ischemic stroke. Presented at the European Stroke Organisation (ESO) conference 2015; April 17-19, 2015; Glasgow, United Kingdom.