

Treatment of Recurrent Varicose Veins

Identifying sources of recurrence and appropriate therapeutic options.

BY EDWARD G. MACKAY, MD

Varicose veins are largely treated by changing the circulatory pattern created by the underlying valvular failure. This frequently involves disconnecting superficial and deep connections that have incompetent valves to stop the flow from high-pressure deep veins back into low-pressure superficial veins and then ablating the damaged superficial veins (varicosities) either surgically, chemically, or thermally. Because there are numerous connections from superficial to deep veins (perforators) that could potentially fail,¹ recurrence should be less of a surprise than the lack thereof. Good treatment necessitates the identification of these abnormal connections, which requires imaging that both identifies the perforator and demonstrates the abnormal flow. The use of duplex ultrasound has greatly improved the accuracy of identifying the problematic perforator, the most common being the saphenofemoral junction.

CAUSES OF RECURRENCE

The causes of recurrence have been identified as wrong or inadequate procedures; recanalization of the treated veins; new sources of incompetence, such as an accessory saphenous vein, small saphenous vein (SSV), or perforator vein; pelvic vein incompetence; and neovascularization.^{2,3} Deep venous disease is a recognized risk factor for an increased chance of recurrence, leading to the possibility of obstruction playing a role in recurrence.⁴

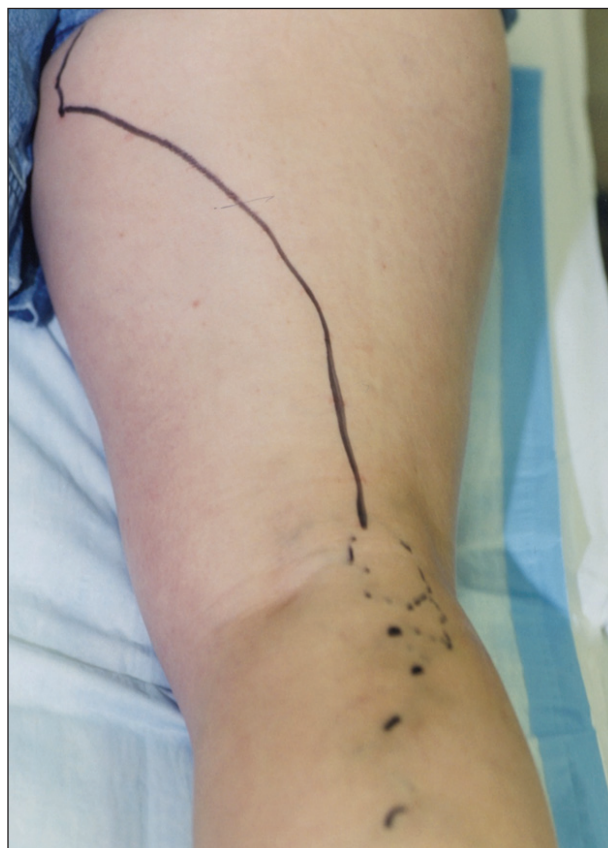

Figure 1. Recurrent varicose veins after SSV stripping from an undiagnosed thigh extension.

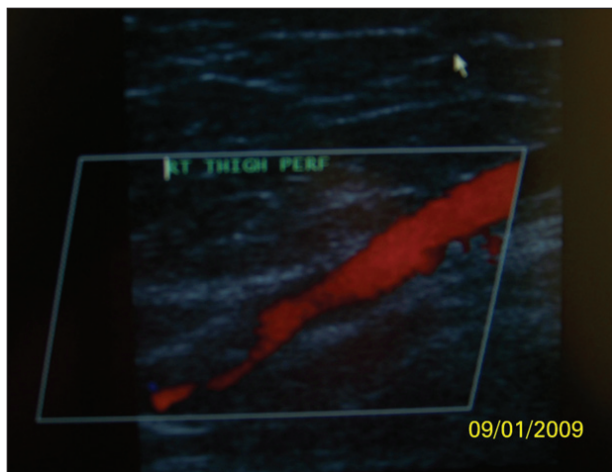


Figure 2. An incompetent perforator vein causing recurrent varicose vein.

INADEQUATE PROCEDURES

A wrong or inadequate procedure is best prevented by a thorough duplex examination. Thankfully, the use of duplex ultrasound has become more common with training of the individuals performing the procedures. In years past, no duplex was performed or there was an inadequate examination of all the potential sources of incompetence. Perforators, accessory veins, small saphenous extensions, and pelvic escape points were frequently overlooked. Simply ablating or stripping the great saphenous vein (GSV) and not treating a refluxing accessory saphenous vein will lead to early recurrence. Similarly, treating the SSV below the saphenopopliteal junction when there is also a refluxing thigh extension (Giacomini vein) leads to early recurrence (Figure 1).

Of course, the best treatment would be prevention through always performing a thorough and complete duplex examination. Have a protocol in place that includes careful documentation of all major sources of reflux, particularly the accessory, perforators, extensions, and pelvic escape points that could easily be missed.

NEW SOURCES OF INCOMPETENCE

New sources of incompetence, such as accessory and perforator veins, can be treated with a number of methods. Accessory veins can be treated with any of the standard ablative procedures, including thermal, chemical, and mechanochemical methods that are employed for treatment of the GSV or SSV. There are the usual limitations of these different modes of therapy, such as superficial or tortuous segments. Superficial segments can be treated with phlebectomy and/or chemical ablation (sclerotherapy).




Figure 3. Treatment of the incompetent perforator vein with radiofrequency (RF).

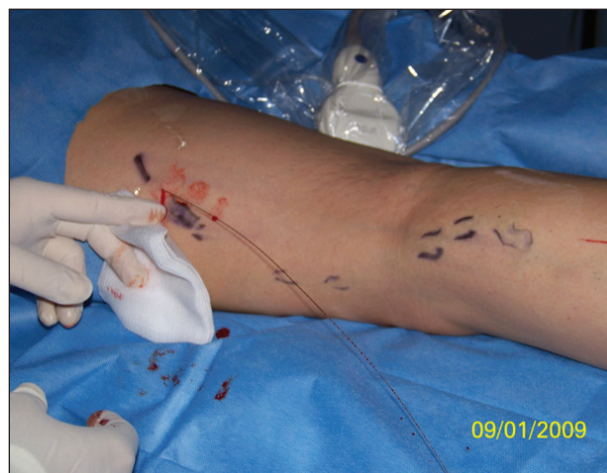

Figure 4. Wire access into the incompetent thigh perforator.

Tortuous segments may be treated from multiple entry points with thermal, mechanochemical, or chemical ablative techniques.

Incompetent perforator veins (Figure 2) can be treated with the previously described techniques, including subfascial endoscopic perforator surgery, thermal ablation, sclerotherapy, or ultrasound-guided ligation. Subfascial endoscopic perforator surgery was largely abandoned once ultrasound was used to effectively identify the incompetent perforators and allow more directed therapies. The only US Food and Drug Administration (FDA)-approved thermal treatment for incompetent perforator veins is the ClosureRFS endovenous radiofrequency stylet (Covidien) (Figure 3) using a bipolar thermal device that is inserted into the perforator vein over a wire or through direct access using the sharp enclosed within

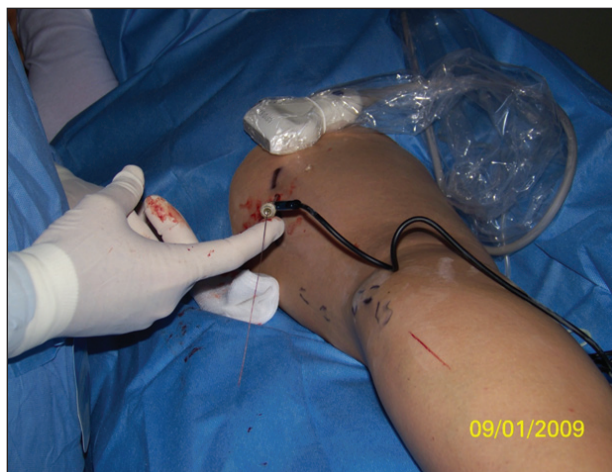

Figure 5. RF IPV inserted over the wire into the incompetent perforator.

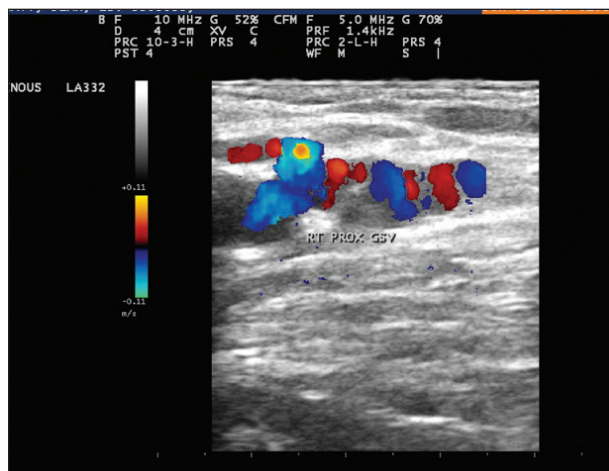


Figure 6. Neovascularization after high ligation and stripping causing recurrent varicose veins.

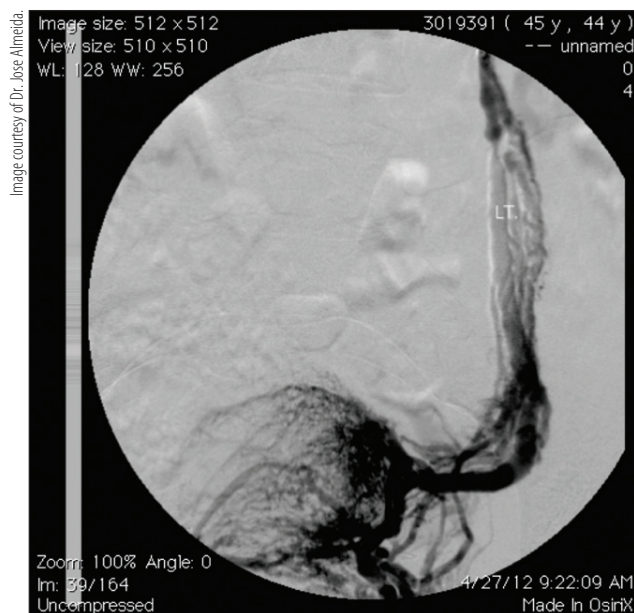


Figure 7. Symptomatic pelvic varicosities.

the catheter (Figures 4 and 5). After tumescent anesthesia is infiltrated, RF energy is applied, generating heat and ablating the vein. It takes approximately 2 to 4 minutes for each centimeter of perforator to be treated.

Thermal treatment with endovenous laser has been described,⁵ but no FDA approval has been obtained for this technique. Sclerotherapy is also used but can be limited by the proximity of the perforator to the deep venous system and the difficulty in controlling the entry of the sclerosant into the deep venous system, which could result in a deep vein thrombosis (DVT). Sclerotherapy works well for smaller veins that

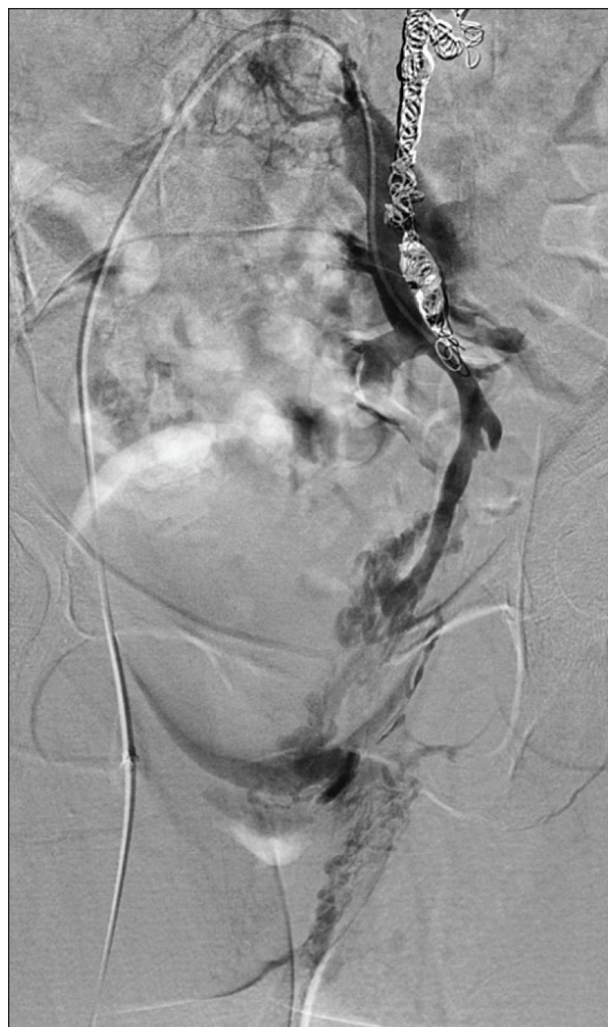

Figure 8. Pelvic reflux causing recurrent varicose veins of the lower extremity treated with coil embolization.

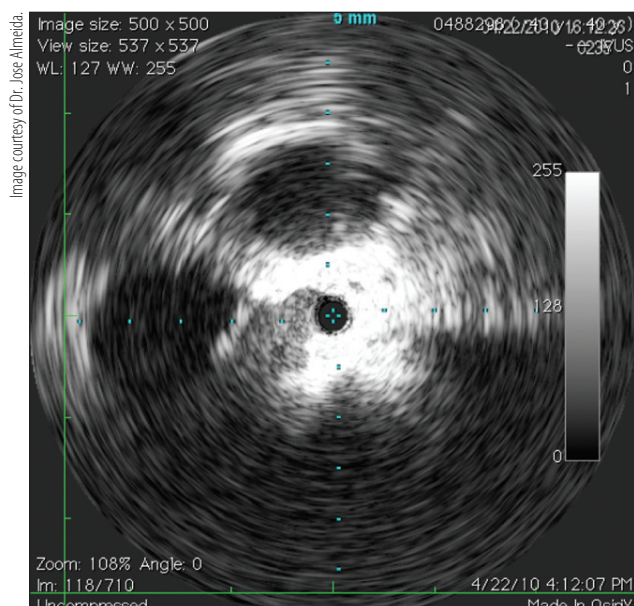


Figure 9. Deep iliac vein obstruction diagnosed with intravascular ultrasound.

do not immediately empty into the deep venous system. Care must be taken because perforator veins are accompanied by perforator arteries, and an injection to the artery could have serious consequences. Areas where the perforator is too superficial for thermal ablation and too close to the deep venous system for sclerotherapy may best be handled by simple ligation. By marking the location using ultrasound guidance, a very small incision could be used to mobilize, ligate, and divide the incompetent perforator vein between suture ligatures.

RECANALIZED VEINS

Recanalized saphenous veins after thermal, chemical, or mechanochemical ablation can be especially challenging to treat. The first step is to determine if treatment is necessary. If the duplex ultrasound shows a small lumen diameter, the volume of refluxing blood may not be clinically significant, and treatment may be unnecessary. Assuming that the recanalization is symptomatic and deserves treatment, this can still be very challenging because the previously treated vein may have scarring in the lumen. This prevents passing of a catheter through the vein, and the scarred vein wall may not respond to sclerotherapy as predicted. A widely patent vein that accepts a catheter can be treated with normal thermal methods, possibly needing higher energy requirements due to the thickened vein wall. If the vein does not accept a catheter, chemical ablation can be considered next. There are no data

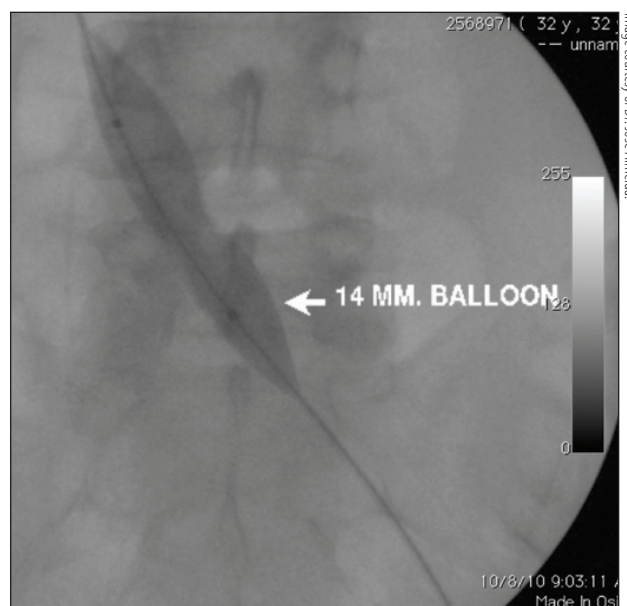


Figure 10. Venous angioplasty of iliac vein.

specifically addressing the problem of a recanalized saphenous vein, but the need to treat the tributary or perforator that the vein is refluxing into should be expected. With nowhere to reflux to, the saphenous vein should respond better to any treatment.

Finally, ligation from the highest refluxing point, such as the saphenofemoral junction or perforator, with or without stripping could be considered if less invasive methods fail. The stiffness of a PIN (perforator invaginate) stripper may be needed to pass down the scarred saphenous vein. The vein may need to be removed in segments if it is not possible to strip; subsequent high ligation along with phlebectomy may provide adequate results.

NEOVASCULARIZATION

Neovascularization is well documented after stripping; it is also documented after thermal ablation, but seems to be less common (Figure 6).⁶ Neovascularization provides a challenge for treatment; the vessels are very thin-walled, usually present in multiples, and grow in scar tissue from a previous treatment. This makes it potentially fraught with complications, including lymphatic injury, bleeding, and infection. Thermal treatment options are not possible because these vessels are too tortuous for catheters. This leaves chemical ablation as the only option for this difficult problem. Foam sclerotherapy with ultrasound guidance or the recently FDA-approved polidocanol microfoam (Varithena, BTG plc) may be the treatment of choice. On top of being the only foam

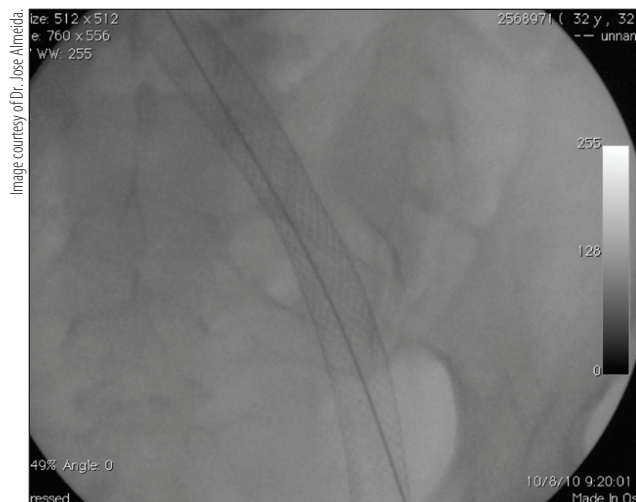


Figure 11. Iliac vein stenting.

sclerosant that is FDA approved, it has been approved for use in larger volumes than typically used for foam sclerotherapy. This should allow for fewer treatments and more predictable outcomes. There are no data on the use of polidocanol microfoam specifically for the treatment of neovascularization.

ABDOMINAL AND PELVIC INCOMPETENCE

Incompetence from abdominal and pelvic connections is another cause of recurrence, either early due to a missed finding on a duplex ultrasound or late as a new source of reflux.⁷ Treatment usually requires the initial diagnosis to be made by ultrasound or possibly venography, as well as presenting symptoms. If the symptoms are limited to the lower extremity, then therapy can be limited to treating the escape points from the abdominal wall or pelvic vessel with either direct ligation or image-guided sclerotherapy. Ultrasound guidance has been used, as well as radiographic imaging guidance with intravenous contrast. In a personal communication with Paul Timperman, MD, and Israel Schur, MD, the use of a combination of sclerosant and intravascular contrast was described to allow image confirmation of treated pelvic vessels. Patients presenting with pelvic symptoms as well as recurrent varicose veins should be evaluated for pelvic reflux and pelvic varicosities (Figure 7). The pelvic symptoms can be ameliorated while also treating the source of the reflux causing the recurrence of the lower extremity symptoms (Figure 8). Contrast venography of the gonadal and internal iliac veins should show the source of reflux and pelvic varicosities. Refluxing veins can be treated with embolization and/or sclerotherapy, ideally ablating the varicosities as well as occluding the refluxing vein.

OBSTRUCTIVE DISEASE

Recurrent varicose veins are more common in patients with a history of DVT and postthrombotic syndrome, which makes the possibility of deep venous obstruction a possible cause of the recurrent varicosities, especially with more advanced symptoms. Therefore, patients with recurrent varicose veins and advanced disease should be considered for venography and intravascular ultrasound (Figure 9). This could show proximal occlusive disease that could be the cause of increased venous pressures leading to recurrent reflux, varicose veins, and the more advanced symptoms. This could be treated with venous angioplasty and stent(s) with good long-term results (Figures 10 and 11).⁸

CONCLUSION

Recurrent varicose veins are an inevitable part of treating venous disease. As with any disease, prevention goes a long way toward reducing the incidence of recurrence. Prevention can be achieved with a thorough duplex evaluation and treatment of all refluxing escape points from the deep venous system to the superficial venous system. Despite proper diagnosis and treatment, recurrence is still a problem. The most common sources of recurrence are accessory and perforator veins, neovascularization, and deep venous disease from refluxing abdominal pelvic veins and obstruction. Treatment of these patients can be challenging and requires careful follow-up with duplex ultrasound evaluation and occasionally other imaging modalities. ■

Edward G. Mackay, MD, is Medical Director of Mackay Vein Institute in St. Petersburg, Florida. He has disclosed that he owns stock in Sapheon and EndoShape. Dr. Mackay may be reached at drmackay@drmackay.com; (727) 527-2888.

1. Delis KT, Husmann M, Kalodiki E, et al. In situ hemodynamics of perforating veins in chronic venous insufficiency. *J Vasc Surg.* 2001;33:773-782.
2. Bush RG, Bush P, Flanagan J, et al. Factors associated with recurrence of varicose veins after thermal ablation: results of the recurrent veins after thermal ablation study. *Scientific World Journal.* 2014;2014:505843. doi: 10.1155/2014/505843. eCollection 2014.
3. Cardia G, Catalano G, Rosafo I, et al. Recurrent varicose veins of the legs. Analysis of a social problem. *G Chir.* 2012;33:450-454.
4. Allegra C, Antignani PL, Carlizza A. Recurrent varicose veins following surgical treatment: our experience with five years follow-up. *Eur J Vasc Endovasc Surg.* 2007;33:751-756.
5. Zerweck C, von Hohenberg E, Knittel M, et al. Endovenous laser ablation of varicose perforating veins with the 1470-nm diode laser using the radial fibre slim. *Phlebology.* 2014;29:30-36.
6. Theivacumar NS, Darwood R, Gough MJ. Neovascularisation and recurrence 2 years after varicose vein treatment for sapheon-femoral and great saphenous vein reflux: a comparison of surgery and endovenous laser ablation. *Eur J Vasc Endovasc Surg.* 2009;38:203-207.
7. Meneses L, Fava M, Diaz P, et al. Embolization of incompetent pelvic veins for the treatment of recurrent varicose veins in lower limbs and pelvic congestion syndrome. *Cardiovasc Intervent Radiol.* 2013;36:128-132.
8. Neglen P, Hollis KC, Olivier J, Raju S. Stenting of the venous outflow in chronic venous disease: long-term stent-related outcome, clinical, and hemodynamic result. *J Vasc Surg.* 2007;46:979-990.