

Retrievable Inferior Vena Cava Filter Update

Current indications for temporary filter placement, as well as the techniques and possible complications of removal.

BY RAMSEY AL-HAKIM, MD, AND JUSTIN McWILLIAMS, MD

Venous thromboembolism, including deep vein thrombosis (DVT) and subsequent pulmonary embolism (PE), is a considerable source of morbidity and mortality in the general population. While anticoagulation remains the first-line treatment of venous thromboembolism, inferior vena cava (IVC) filters are an alternative option for prevention of primary or recurrent PE in patients with contraindications to anticoagulation or those who have failed anticoagulation. Retrievable IVC filters have been in use in clinical practice since 2003–2004, when the FDA first drafted regulations regarding their use. Initial prospective studies demonstrated no increased complication rate of retrievable filters compared to permanent filters. While permanent filters could be considered for patients with limited life expectancy, it has been our experience to place only retrievable filters regardless of indication for the rare case where a filter with a permanent indication requires retrieval or replacement (eg, filter complication). It is important to understand that retrievable filters are not temporary and can be placed for permanent indications. Because of this, the placement of retrievable filters has vastly outnumbered the placement of permanent filters in recent years and thus is the focus of this article.

INDICATIONS FOR IVC FILTER PLACEMENT

At our institution, we rely on the 2006 Society of Interventional Radiology (SIR) consensus guidelines for absolute, relative, and prophylactic indications for IVC filter placement.¹ The American College of Chest Physicians (ACCP) guidelines recommend IVC filter placement for patients with proximal DVT or PE and a contraindication to anticoagulation but do not recommend for or against relative or prophylactic indications as defined by the SIR consensus guidelines.² The use of prophylactic IVC filters is particularly controversial; this was recently reviewed by Harvey et al.³ Venous thromboembolic disease is a common complication associated with major trauma patients

Special attention should be paid to prophylactic filters placed in trauma patients, a situation in which the filter can typically be removed within a relatively short time interval as patients begin to ambulate or are transitioned to anticoagulation.

with an incidence estimated at 60%, and PE is the most common cause of death in patients surviving the initial injury.³⁻⁵ Meta-analyses have demonstrated a decreased incidence of PE with the use of IVC filters in this patient population.⁵⁻⁸ Some investigators have recommended bedside filter placement under ultrasound guidance to facilitate early placement, which is important given that 70% of posttraumatic pulmonary emboli occur within the first week, and some as early as 24 hours posttrauma.^{3,9} Prophylactic IVC filters, primarily for trauma patients, have become increasingly common and represented 29% of filters placed at our institution over the past 10 years, compared to absolute and relative indications in 64.1% and 6.9% of patients, respectively. Until more conclusive data are available, we plan to continue to follow the SIR consensus guidelines for filter placement indications, with the caveat of filter retrieval as early as clinically indicated, as discussed in this article.

INDICATIONS FOR IVC FILTER RETRIEVAL

In general, all patients with retrievable IVC filters should have the filter retrieved as soon as the clinical indication for placement is no longer present, ideally within 30 days of placement (see the *IVC Filter Retrieval-Assistance Programs* sidebar). For patients who have a

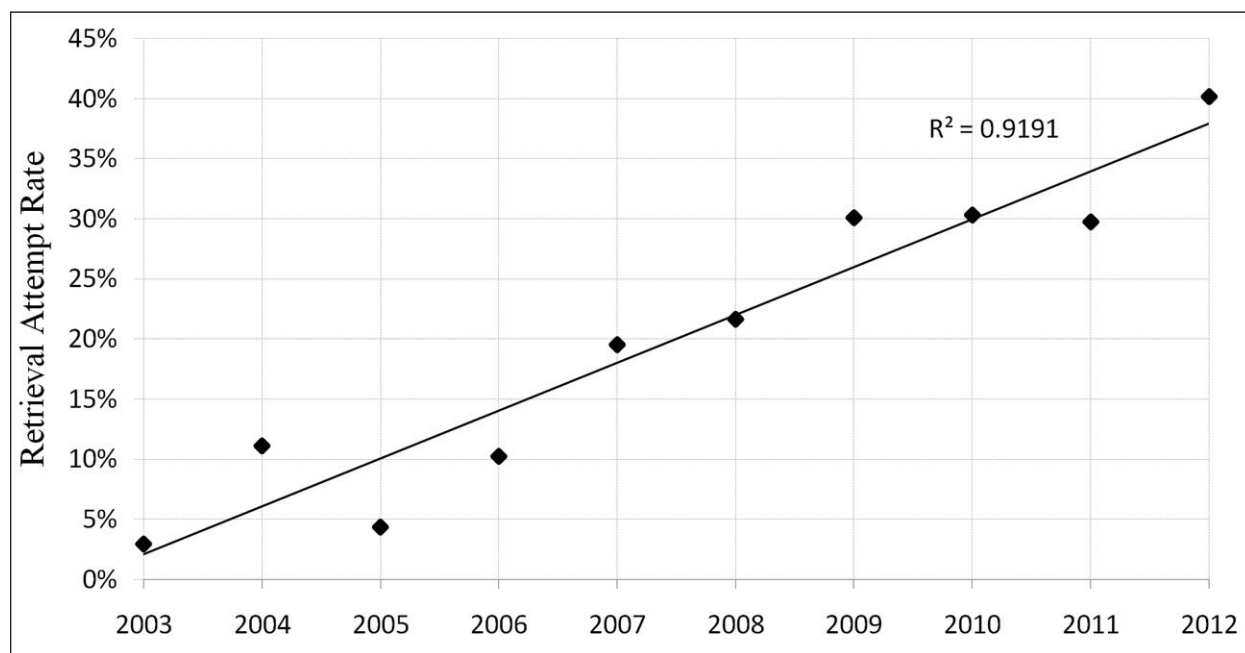


Figure 1. Single-center experience of IVC filter retrieval attempt rates by year demonstrates a significant linearly upward trend ($P < .01$) with a peak retrieval attempt rate of 40.2% in 2012.

filter placed for temporary inability to be anticoagulated (eg, surgery), the filter should be removed as soon as the patient is therapeutically anticoagulated. For prophylactic indications, the filter should be removed as soon as the patient's risk of DVT is no longer significantly increased (ie, the patient is ambulating). Special attention should be paid to prophylactic filters placed in trauma patients, a situation in which the filter can typically be removed within a relatively short time interval as patients begin to ambulate or are transitioned to anticoagulation.¹⁰

Indwelling filters that are no longer indicated should be promptly retrieved for several reasons. Most importantly, there are several reported long-term IVC filter complications, such as IVC thrombosis, IVC penetration, chronic abdominal pain, and duodenal perforation.¹¹ Also, failure of routine removal techniques has been shown to increase with dwell time, and use of advanced techniques has been shown to significantly increase the retrieval complication rate.¹² Clearly, a patient should not be subjected to these unnecessary risks if there is no continued benefit of the IVC filter. The responsibility to retrieve filters ultimately falls upon the interventionist, which has led to the development and adoption of various registries that have successfully increased the retrieval rate in many institutions.¹³ At our own institution, we have significantly increased our filter retrieval attempt rate linearly over a 10-year period ($P < .01$), with a peak retrieval attempt rate of 40.2% in 2012 (Figure 1).

Recognition of the dangers of long-term IVC filters has led interventional radiologists to attempt retrieval of IVC filters with prolonged dwell times, particularly in younger patients. Angel et al, in a systematic review of 1,715 removed filters, reported an average time to retrieval of 72 days; successful retrieval up to 3,006 days has been reported in the literature.^{11,14} However, the success of retrieval attempts has been shown to decrease with prolonged dwell times, which further highlights the importance of frequent follow-up for reassessment of risk and consideration of filter retrieval as early as possible.^{15,16}

Although most IVC filters remain asymptomatic, symptomatic filter strut penetration can occur and is a further indication for filter removal. We presented our results from a retrospective analysis at the SIR 2014 Annual Scientific Meeting in San Diego, California. We graded IVC filter penetration on preretrieval CT in 49 patients according to increasing depth of strut penetration (grade 0–2) and evidence of contact with adjacent structures (grade 3).¹⁷ There were four patients with symptoms that could potentially be explained by filter penetration (3 with abdominal pain and 1 with back pain) and were not consistent with an alternative clinical diagnosis. All four of these patients had grade 3 penetration, fat stranding associated with the penetrating struts (which was not present in remaining 45 patients), and complete alleviation of symptoms after filter retrieval. We concluded that patients with high-grade filter strut penetration and associated symptoms not consistent with an alternative diagnosis have

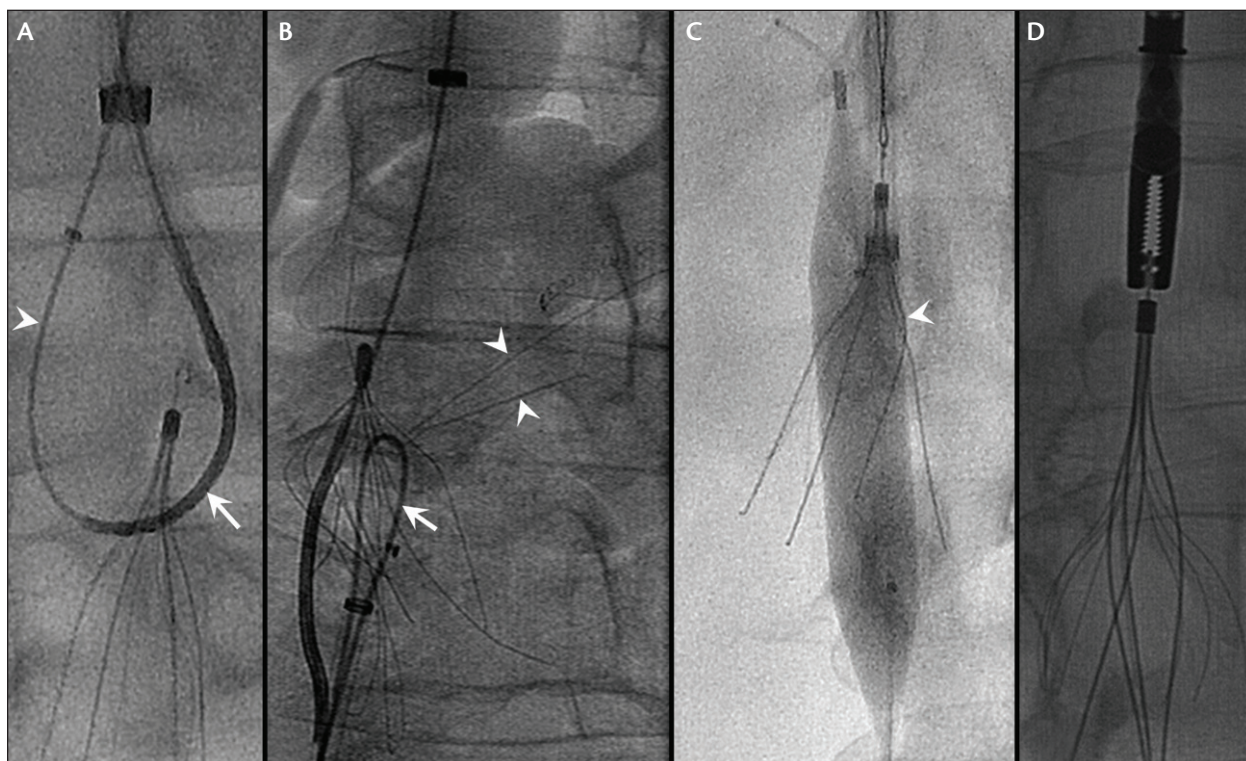


Figure 2. Antegrade wire loop and snare technique with Glidewire (arrowhead) and reverse curve catheter (arrow) coursing between filter struts and externalized through sheath (A). Retrograde wire loop and snare technique with Glidewire (arrow) coursing cranially to filter struts (arrowheads) and tension applied caudally to assist release of deeply penetrating filter struts (B). Balloon displacement technique with 14- X 40-mm Atlas (Bard Peripheral Vascular) balloon-displacing penetrating filter strut (arrowhead) (C). Endobronchial forceps firmly grasping an embedded filter hook (D).

a high likelihood of symptom alleviation after filter retrieval, particularly when there is evidence of fat stranding on preretrieval CT.

TECHNIQUES FOR IVC FILTER RETRIEVAL

Although a majority of filters can be removed without difficulty, there are several factors that increase the risk of routine filter retrieval failure, including embedded hook, severe tilt, significant filter thrombus, caval occlusion, and filter strut penetration into the caval wall, which has been seen with all filter types. Multiple studies have described various advanced techniques for retrieval of these difficult IVC filters, including Iliescu et al, who performed a thorough review of advanced techniques.¹⁸⁻²⁰ Case examples of some of the useful techniques are shown in Figure 2, including loop snare, balloon displacement, and endomyocardial/endobronchial forceps dissection techniques. Review of our 10-year institutional IVC filter retrieval experience demonstrated that an algorithmic approach to IVC filter retrieval using advanced techniques in cases where routine technique has failed resulted in an overall filter retrieval rate of 98.2%.

More recently, we have reported our success with a modified loop snare technique, which we call the *Hangman technique*.²¹ The Hangman technique uses a 5-F reverse curve catheter (SOS Omni Catheter; AngioDynamics) and Glidewire (Terumo Interventional Systems) to create a wire loop between the filter neck and IVC wall (hence the name “Hangman”), as opposed to between the filter legs, for release of the embedded filter hook (Figure 3). The Hangman technique was attempted in 11 cases, which were all complicated by severe tilt (mean tilt, $13.3^\circ \pm 3.9^\circ$) and presence of an embedded hook (mean dwell time, 194.5 days). The retrieval success rate of this technique was 81.8% (9/11), with no associated complications.

Although techniques vary based on the specific situation, we usually first attempt routine retrieval using a loop snare, sometimes using several telescoping sheaths to increase longitudinal rigidity and prevent buckling as the sheath is passed over the filter. If the hook cannot be engaged by the snare, a shaped guide catheter can be used to help direct the snare toward the hook. If this fails, we usually proceed directly to the Hangman technique and resort to the loop

IVC FILTER RETRIEVAL-ASSISTANCE PROGRAMS

In May of this year, the US Food and Drug Administration updated their August 2010 Initial Communication on the necessity of timely retrieval of IVC filters. With reports of device migration, filter fracture, and embolization, there is a strong recommendation to remove filters as soon as protection from pulmonary embolism is no longer needed.

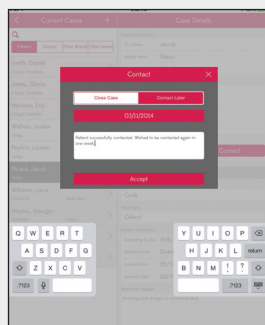
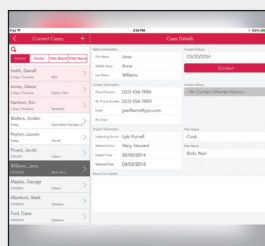
As a response to this ongoing push, two industry-sponsored programs were started to aid in the reminder to physicians and patients about appropriate follow-up and retrieval.

VCF TRACK APP**Cook Medical****Search “VCF Track” in the iPad iTunes store**

VCF Track is an organizational tool that manages key information about filters, recipients, manufacturer brands, implant dates, and referral physicians. It will even send you reminders when patients' intended follow-up dates have passed. You can track any filter brand, and no information leaves your device. The free app is available only in the iTunes store and works only on iPads.

VCF Track allows you to:

- Directly input filter information
- View current and archived information at any time
- Create and monitor reminders for patient follow-up
- Have case information at your fingertips, including the type of filter used in each case
- Search patient case information quickly
- Receive notifications for patient contact
- Write notes to yourself
- Alter notification dates
- Maintain patient contact history in one place
- Archive patient cases

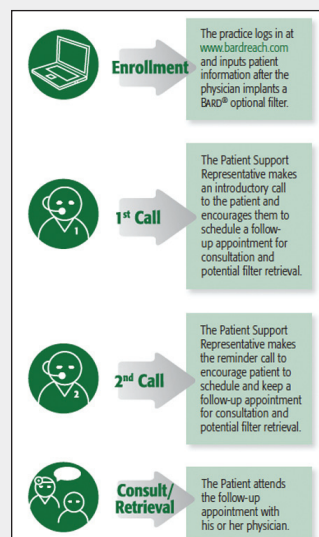
**BARD REACH PROGRAM****Bard Peripheral Vascular****www.bardreach.com**

The Bard REACH program is an initiative designed to help physicians track and contact their Bard Optional vena cava filter patients and bring them back to the practice for follow-up.

When a physician registers for the free Bard REACH program, he or she receives access to a secure web portal and the services of professional patient support representatives. The representatives contact the patients and encourage them to return for initial follow-up or retrieval.

In order to use this service, complete a one-time online registration and agree to the terms that allow McKesson, a third-party patient outreach group, to contact patients on your behalf.

After implanting a Bard Optional vena cava filter, enroll the patient using the secure web portal. A McKesson patient support representative contacts the patient on your behalf, encouraging him or her to schedule and attend a follow-up consult.



snare technique or endobronchial forceps only for filters failing these measures.

COMPLICATIONS ASSOCIATED WITH FILTER RETRIEVAL

While the available advanced techniques are very successful, interventionists should be aware of reported complications of filter retrieval, including IVC dissection, IVC intussusception, IVC thrombus/stenosis, filter fracture with embedded strut, IVC injury with hemorrhage, and vascular injury from complicated venous access. Our

10-year experience of 231 filter retrieval attempts demonstrated an overall filter retrieval complication rate of 1.7%, with a significantly higher complication rate associated with the use of advanced techniques compared to routine technique (5.3% vs 0.4%; $P < .05$).¹² Overall, these reported complication rates of filter retrieval, even with fairly prolonged dwell times, compare favorably with the risk of leaving the filter in place long term.

In our experience, an interventionist cannot be overprepared in anticipation of retrieving an IVC filter. Significantly prolonged dwell times, as well as several

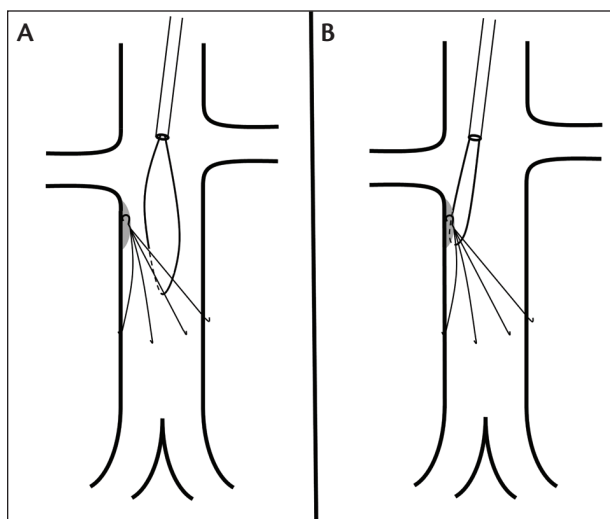


Figure 3. Schematic of an IVC filter with lateral tilt and embedded hook due to a fibrous capsule (gray shading). The standard loop snare technique (A) utilizes a wire between the filter struts, while the Hangman technique (B) is accomplished by passing the wire between the filter neck and IVC wall just inferior to the embedded hook. Adapted and printed from Al-Hakim R, et al. The Hangman technique: a modified loop snare technique for the retrieval of inferior vena cava filters with embedded hook. *J Vasc Interv Radiol*. In press. © 2014, with permission from Elsevier.²¹

imaging predictors on preretrieval CT, can strongly predict the failure of routine technique.¹⁵ While we do not routinely perform preretrieval CT on all patients, the potential risk and benefit of a preretrieval CT should be considered for any patient presenting for IVC filter retrieval, particularly those with dwell times > 180 days where the odds ratio of complicated retrieval is > 2. Preretrieval CT can provide information on tilt, migration, strut penetration, and most importantly, embedded hook. A priori knowledge of the presence of features predicting a high likelihood of advanced filter retrieval allows proper patient counseling on procedural risks, preparation for prolonged procedural time, and scheduling of patients with anesthesia in selected situations.

CONCLUSION

IVC filters can be placed for absolute, relative, or prophylactic indications in selected patients. Although controversial at this time, we adhere to the 2006 SIR consensus guidelines for absolute, relative, and prophylactic indications until more conclusive data are available. However, it is the responsibility of the interventionist to ensure timely retrieval of IVC filters when no longer clinically indicated, ideally within 30 days if clinically feasible, to reduce long-term

complications and minimize the risk of retrieval-associated complications. Implementation of registries has been shown to increase filter retrieval rate and is highly recommended.

Knowledge of the dwell time and the potential for difficult retrieval are important when considering IVC filter retrieval and counseling patients. Preretrieval CT has been shown to identify factors that predict a high probability of failure of routine technique and should be considered for filters with a dwell time > 180 days. Several safe and effective techniques have been described for removal of filters that fail routine retrieval technique. Although advanced retrieval techniques have been associated with higher complication rates, advanced retrieval may be preferable to the risks associated with leaving a filter in place permanently. ■

Ramsey Al-Hakim, MD, is with the Department of Radiology, Division of Interventional Radiology, University of California in Los Angeles. He stated that he has no financial interests related to this article.

Justin McWilliams, MD, is with the Department of Radiology, Division of Interventional Radiology, University of California in Los Angeles. He stated that he has no financial interests related to this article. Dr. McWilliams may be reached at jumcwilliams@mednet.ucla.edu.

1. Kaufman J, Kinney T, Streiff M, et al. Guidelines for the use of retrievable and convertible vena cava filters: report from the Society of Interventional Radiology Multidisciplinary Consensus Conference. *J Vasc Interv Radiol*. 2006;17:449-459.
2. Guyatt G, Akl E, Crowther M, et al. Antithrombotic therapy and prevention of thrombosis, 9th ed: American College of Chest Physicians evidence-based clinical practice guidelines. *Chest*. 2012;141:7S-47S.
3. Harvey J, Hopkins J, McCafferty I, et al. Inferior vena cava filters: what radiologists need to know. *Clinical Radiol*. 2013;68:721-732.
4. Rogers FB. Venous thromboembolism in trauma patients: a review. *Surgery*. 2001;130:1e12.
5. Kidane B, Madani AM, Vogt K, et al. The use of prophylactic inferior vena cava filters in trauma patients: a systematic review. *Injury*. 2012;43:542-547.
6. Rajasekhar A, Lottenberg R, Lottenberg L, et al. Pulmonary embolism prophylaxis with inferior vena cava filters in trauma patients: a systematic review using the meta-analysis of observational studies in epidemiology (MOOSE) guidelines. *J Thromb Thrombolysis*. 2011;32:40-46.
7. Rogers FB, Shackford SR, Ricci MA, et al. Routine prophylactic vena cava filter insertion in severely injured trauma patients decreases the incidence of pulmonary embolism. *J Am Coll Surg*. 1995;180:641-647.
8. Rogers FB, Cipolle MD, Velthuis G, et al. Practice management guidelines for the prevention of venous thromboembolism in trauma patients: the EAST practice management guidelines work group. *J Trauma*. 2002;53:142-164.
9. Rosenthal D, Wellons ED, Levitt AB, et al. Role of prophylactic temporary inferior vena cava filters placed at the ICU bedside under intravascular ultrasound guidance in patients with multiple trauma. *J Vasc Surg*. 2004;40:958-964.
10. Sarosiek S, Crowther M, Sloan JM. Indications, complications, and management of inferior vena cava filters: the experience in 952 patients at an academic hospital with a level I trauma center. *JAMA Intern Med*. 2013;173:513-517.
11. Angel LF, Tapson V, Galgon RE, et al. Systematic review of the use of retrievable inferior vena cava filters. *J Vasc Interv Radiol*. 2011;22:1522-1530.
12. Al-Hakim R, Kee S, Olinger K, et al. Inferior vena cava filter retrieval: effectiveness and complications of routine and advanced techniques. *J Vasc Interv Radiol*. 2014;25:933-939.
13. Lynch FC. A method for following patients with retrievable inferior vena cava filters: results and lessons learned from the first 1,100 patients. *J Vasc Interv Radiol*. 2011;22:1507-1512.
14. Lynch FC. Removal of a Günther Tulip filter after 3006 days. *J Vasc Interv Radiol*. 2011;22:337-340.
15. Dinglasan L, Oh J, Schmitt J, et al. Complicated inferior vena cava filter retrievals: associated factors identified at preretrieval CT. *Radiology*. 2012;266:347-354.
16. Marquess JS, Burke CT, Beecham AH, et al. Factors associated with failed retrieval of the Günther Tulip inferior vena cava filter. *J Vasc Interv Radiol*. 2008;19:1321-1327.
17. Oh J, Trerotola S, Dagli M, et al. Removal of retrievable inferior vena cava filters with computed tomography findings indicating tenting or penetration of the inferior vena cava wall. *J Vasc Interv Radiol*. 2011;22:70-74.
18. Van Ha TG, Vinokur O, Lorenz J, et al. Techniques used for difficult retrievals of the Günther Tulip inferior vena cava filter: experience in 32 patients. *J Vasc Interv Radiol*. 2009;20:92-99.
19. Iliescu B, Haskal ZJ. Advanced techniques for removal of retrievable inferior vena cava filters. *Cardiovasc Intervent Radiol*. 2012;35:741-750.
20. Kuo WT, Tong RT, Hwang GL, et al. High-risk retrieval of adherent and chronically implanted IVC filters: techniques for removal and management of thrombotic complications. *J Vasc Interv Radiol*. 2009;20:1548-1556.
21. Al-Hakim R, McWilliams J, Derry W, Kee S. The Hangman technique: a modified loop snare technique for the retrieval of inferior vena cava filters with embedded hook. *J Vasc Interv Radiol*. In Press.